



## Original Research Article

## Assessment and comparison of clinico-microbiological efficacy of moxifloxacin plus vancomycin combined therapy with fortified vancomycin in bacterial keratitis

Ahmad Abdullah<sup>1,\*</sup>, S N Askari<sup>1</sup>, Shamim Ahmad<sup>1</sup>, Yasir Alvi<sup>1</sup>

<sup>1</sup>Dept. of Ophthalmology, Jawaharlal Nehru Medical College Hospital, Aligarh, Uttar Pradesh, India



## ARTICLE INFO

## Article history:

Received 14-07-2020

Accepted 06-11-2020

Available online 30-06-2021

## Keywords:

Keratitis

Corneal ulcer

Bacterial keratitis

Efficacy

## ABSTRACT

**Aim:** To assess and compare clinico-microbiological efficacy of Moxifloxacin (0.5%) plus Vancomycin (2.5%) combined therapy to Fortified Vancomycin (5%) in bacterial keratitis.

**Materials and Methods:** The present study was conducted on patients who visited eye OPD, J.N.M.C.H and Gandhi Eye Hospital, Aligarh. Patients with bacterial keratitis were diagnosed and included in the study. Right eyes were instilled moxifloxacin plus vancomycin combination therapy and Left eyes were instilled fortified vancomycin. Microbiological results were recorded on first visit and on follow up visits during course of treatment.

**Results:** Total of 32 patients were included in the study. At first visit, only 8 cases were positive for bacterial culture with coagulase negative Staphylococcus (CoNS) being the most common organisms. All the smears became negative in first follow-up (7th day) in both the groups. No significant difference were found in clinical and microbiological study outcome between the two-study groups.

**Conclusions:** We conclude that both the drugs, i.e. moxifloxacin (0.5%) plus vancomycin (2.5%) combined therapy and fortified vancomycin (5%) had good efficiency clinically and in microbial elimination in cases of bacterial keratitis with equivalent outcome.

© This is an open access article distributed under the terms of the Creative Commons Attribution License (<https://creativecommons.org/licenses/by/4.0/>) which permits unrestricted use, distribution, and reproduction in any medium, provided the original author and source are credited.

## 1. Introduction

Bacterial keratitis is a ocular infection that occurs when the corneal epithelial barrier is compromised. According to World Health Organization (WHO), corneal diseases are among the major causes of vision loss and blindness in the world today, second only to cataract. A particular feature of bacterial keratitis is its rapid progression and corneal destruction. Clinical signs and symptoms in cases of corneal ulcer include ocular pain, decreased vision, inflammation, photophobia, discharge, focal corneal stromal infiltrates, epithelial defect, corneal thinning, stromal edema, anterior chamber reaction and eyelid edema.<sup>1</sup> Infection mostly involves Gram-positive *S. aureus*, *S. epidermidis* and several *Streptococcus* and *Bacillus* spp., as well as Gram-negative bacteria like *P. aeruginosa*, *S. marcescens*, *Moraxella*

*lacunata*, *Microbacterium liquefaciens* and *H. influenzae*.

Excessive and injudicious use of antibiotics has aggravated the problem of antibiotic resistance. Therefore, proper selection of antibiotic for these ocular surface infections remains a challenge for clinicians as well as microbiologists. The emergence of bacterial resistance is influenced by characteristics of the pathogens, antibiotic prescribing practices including the widespread use of systemic antibiotics and health care guidelines. There is a trend of growing resistance to antibiotics among bacteria in corneal samples. Studies indicate that advance generation antibiotics may kill bacteria more rapidly, leading to a faster resolution of ocular infection in the eye than with older topical ocular antibiotics and thereby decreasing transmission and reducing the risk of ocular drug resistance. To maintain a strategic distance from there spread and to prevent further complications, bacterial keratitis need to be tackle at the earliest possible stage.

\* Corresponding author.

E-mail address: [drabdullah9@gmail.com](mailto:drabdullah9@gmail.com) (A. Abdullah).

Moxifloxacin is a fourth-generation fluoroquinolone. It has activity against both Gram-positive and Gram-negative bacteria. This compound cover bacterial resistance to second-and third-generation fluoroquinolones. Vancomycin is a member of the beta lactamase resistant penicillin family. It is bactericidal to gram positive bacteria by binding to structural precursors of the bacterial cell wall. Studies have shown rapid emerging resistance in bacterial ocular surface infections.

Studies show that advanced-generation fluoroquinolones kill bacteria more rapidly, which leads to faster resolution of ocular infection than with older topical antibiotics and thereby reducing the risk of ocular drug resistance.<sup>2,3</sup> Clinical studies suggest that treatment outcomes with fluoroquinolone monotherapy compare favorably with conventional combined therapy of fortified antibiotics.<sup>4</sup>

Clinical examinations have demonstrated that treatment results with fluoroquinolone monotherapy are comparable with combination therapy of fortified antibiotics.<sup>4</sup> Topical Vancomycin has been utilized effectively to treat methicillin resistant ocular surface infections.<sup>5</sup> Kotulus and associates reported clinical failure in a subset of 9 patients with MRSA contaminations treated with moxifloxacin or gatifloxacin. 33% of the patients mproved with proceeded treatment with the 8methoxyfluoroquinolones; however, 66% required extra ntercession and mproved when changed to vancomycin and additionally other mix treatment. Unfortunately economically accessible types of vancomycin are not accessible for the treatment of bacterial ocular infections.<sup>6,7</sup>

In view of above facts, the present study is planned with the objectives to assess and compare clinic-microbiological efficacy of moxifloxacin (0.5%) plus vancomycin (2.5%) combined therapy to fortified vancomycin (5%) in bacterial keratitis. However authors have not come across any study comparing moxifloxacin (0.5%) plus Vancomycin (2.5%) combined therapy to fortified vancomycin (5%) on reviewing English literature on the topic.

## 2. Materials and Methods

### 2.1. Study setting and population

The present study was conducted between January 2016 and September 2017 on patients who presented at ophthalmology OPD, J.N.M.C.H and Gandhi Eye Hospital, Aligarh. This institute is one of the largest government Ophthalmology institute in India.<sup>8</sup> The procedures were explained to the patients and only those patients or guardians in case of minors, who agreed to join the study after written consent, were enrolled for the study.

### 2.2. Inclusion criteria

1. All clinically proven cases of keratitis.
2. Age more than one year

3. Those who gave consent

### 2.3. Exclusion criteria

1. Age less than one year
2. Pregnant female
3. History of surgery within 6 week
4. History of hypersensitivity with vancomycin/moxifloxacin
5. Decrease corneal sensitivity
6. Positive on KOH mount
7. Those who did not gave consent

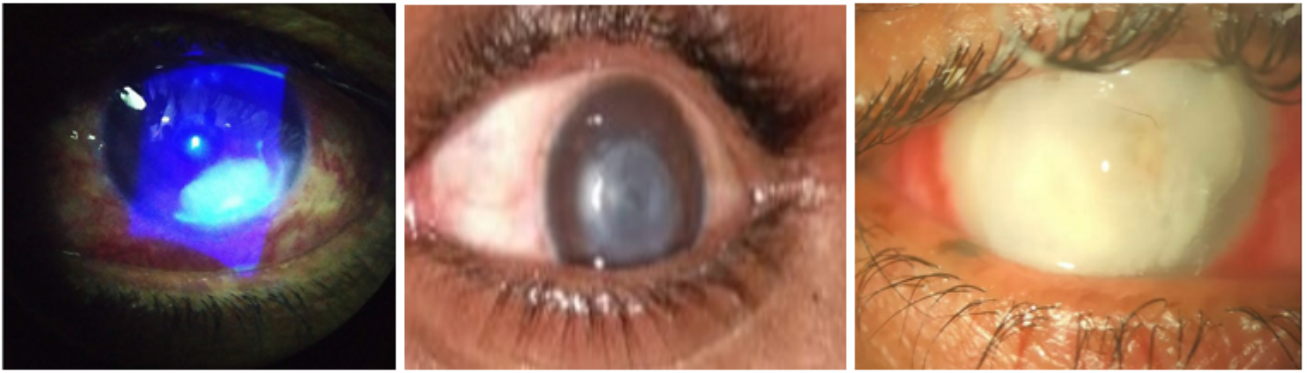### 2.4. Study groups

To eliminate investigator and patient's related bias, patients were divided into two groups on the basis of eye involved. Patients with right eye (OD) (18 eyes) involvement were instilled combination therapy with moxifloxacin(0.5%) plus vancomycin(2.5%) labeled as "Group A" drug and with left eye (OS) (14 eyes) involvement were instilled fortified vancomycin(5%) labeled as "Group B" drug.

### 2.5. Study procedure

All patients of corneal ulcer who reported to OPD, after taking consent were examined for corneal sensations. Those who showed decreased corneal sensation were excluded from the study and were given proper treatment as per standard protocol. Those who had normal corneal sensation further underwent corneal scraping under topical anesthesia using Proparacaine hydrochloride 0.5%. Corneal scrapings were obtained from diseased eyes with sterilized platinum wire loop from base and edge of ulcer for KOH mount and bacteriological examination. Samples which were positive on KOH mount, were again excluded from the study.

The corneal scraping material thus collected was evaluated microscopically for bacteria. Corneal scraping material was inoculated on blood agar and chocolate agar for bacterial culture. Further processing was done to identify the organism and its species at microbiology laboratory at Institute of ophthalmology and Bacteriology lab at Department of Microbiology, J.N.M.C.H, Aligarh. Clinical and Microbiological assessment were performed at visit 1 (day 0) and repeated at visit 2 (day 7), visit 3 (day 14) and visit 4 (day 21). Commercially available preservative free moxifloxacin topical eye drops (Vigamox) were used in the study. Topical Vancomycin drops were prepared by reconstituting the parenteral antibiotic with sterile injection water in a concentration of 25mg/ml when used as combination therapy with moxifloxacin (0.5%) in Group A and in a concentration of 50mg/ml when used as Fortified Vancomycin in Group B and solutions were placed in ophthalmic dispensing bottles by an aseptic technique. The solution were preserved at 4°C.



**Fig. 1:** Variable clinical presentation of bacterial keratitis

Redness and discharge were scored utilizing validated photographic standards.<sup>7</sup> Pain was scored according to the score give by Herr et al. as severe = 3, moderate = 2, mild = 1, absent = 0.<sup>9</sup> The size of the corneal ulcer and area of Infiltration was measured in square millimeters using Slit-lamp. Clinical and Microbiological assessment were performed at visit 1 (day 0) and repeated at visit 2 (day 7), visit 3 (day 14) and visit 4 (day 21).

#### 2.6. Data management and statistics

Statistical analysis were performed using Statistical Package for Social Sciences (SPSS) Version 20. The significance was tested by chi square test for qualitative data while repeated measure ANOVA for the change in various quantitative data. p- value of  $\leq 0.05$  was considered significant.

#### 2.7. Ethics

The study was approved by the board of studies and Institutional Ethics and Research Advisory Committee, JN Medical College, AMU, Aligarh. The participants were ensured about confidentiality of the exercise. Patients were informed briefly about the study and given free will to participate. Appropriate health education, counselling and referral were provided to all the patients.

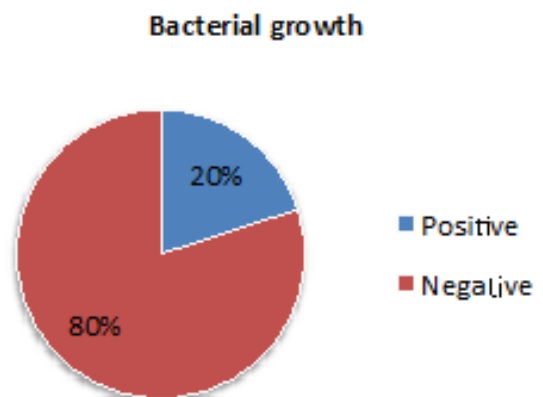
### 3. Results

During the study period 32 patients presented to the OPD with clinically proven keratitis of either eye. After excluding fungal and viral keratitis and applying exclusion criteria we were able to select 40 patients. Final analysis were done on 32 patients as eight patients were lost to follow up in our study.

Out of total 32 patients, majority were male (62.5%) while rest were female (37.5%). All the patients had unilateral eye involvement. Majority were in 11-50 year age group (56.3%) while some were also grouped in above 50

years (37.5%) and very few were below the age group of 10 years (6.3%). At first visit, only eight cases (25%) were positive for bacterial culture, while rest 75% did not showed any bacterial growth. Among those who were positive for bacterial growth, half of them (50%) were positive for coagulase negative Staphylococcus (CoNS) followed by Staph. Aureus in 37.% while one belong to Streptococcus spp. (12.5%). (Table 1 and Figure 2)

Patient with right eye (OD) involvement were instilled combination therapy with moxifloxacin (0.5%) plus vancomycin (2.5%) labeled as Group A and left eye (OS) were instilled fortified vancomycin (5%) labeled as Group B. Eighteen patients were grouped in Group A while rest 14 patients were grouped in Group B. Four patients showed bacterial growth in each of the groups and this distribution was found to be statistically insignificant ( $p > 0.05$ ) (Table 2), while distribution of various species of bacteria in each groups was also found to be statistically insignificant ( $p > 0.05$ ) (Table 3).



**Fig. 2:** Baseline culture positivity of study population

**Table 1:** Demographic and microbiological profile of the study population

Variable	No of patient	Percentage
<b>Gender</b>		
Male	20	62.5%
Female	12	37.5%
<b>Age group</b>		
<10 years	2	6.3%
11-50 years	18	56.3
>50 years	12	37.5
<b>Bacterial growth</b>		
Positive	8	25.0%
Negative	24	75.0%
<b>Bacteria</b>		
Staph. aureus	3	37.5%
Coagulase negative Staphylococcus(CoNS)	4	50.0%
Streptococcus spp.	1	12.5%

**Table 2:** Baseline culture positivity of study population in study groups

Eye/Group	Positive Bacterial Growth n (%)	No Bacterial Growthn (%)	Totaln (%)
Group A	4 (22.2)	14 (77.8)	18
Group B	4 (28.6)	10 (71.4)	14

$\chi^2 = 0.169, df=1, p=0.680$

**Table 3:** Distribution of isolated organisms in two study groups

Eye/Group	Total No. of Eyes	Positive Culture	Organisms Isolated		
			CoNS	SA	Strep. Spp.
Group A	18	4	2 (50%)	1 (25%)	1(25%)
Group B	14	4	2 (50%)	2 (50%)	0 (0%)

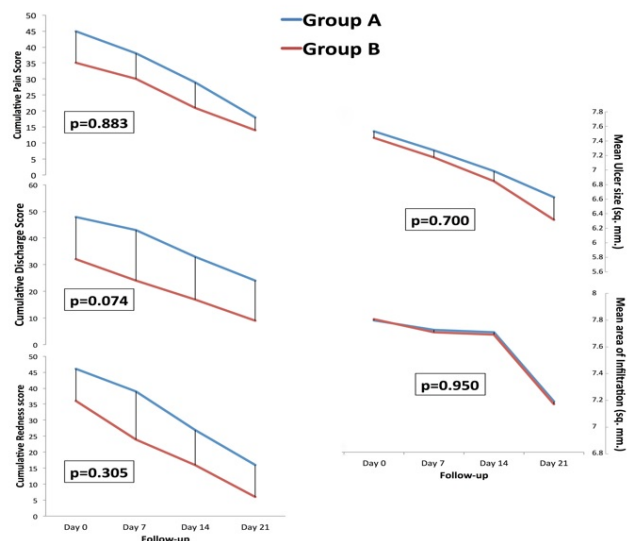
$\chi^2 = 0.101, df=1, p=0.750$

All positive smears in both the groups (Group A and Group B) became negative in first follow-up (Day 7) and there after remain negative for bacterial culture on further follow up. Thus no significant difference was found in microbiological study outcome between the two-study groups. ( $p>0.05$ ) (Table 4)

The two study groups were analyzed for their symptomatic relief of various complains of keratitis. As more number of patients were grouped in Group A, cumulative redness score, cumulative discharge score and cumulative pain score were more in this group, but decrease in these cumulative score was found to be statistically insignificant in Group A in comparison to Group B ( $p>0.05$ ) (Figure 3). Similarly change in ulcer size and size of infiltration in both the study group was found out to be statistically insignificant ( $p>0.05$ ) (Figure 3).

#### 4. Discussion

Bacterial keratitis is potentially dangerous ocular surface infection that may occur when the corneal epithelial barrier is compromised, leading to ulceration. We evaluated the clinico-microbiological efficacy of commonly used drug for bacterial keratitis i.e fortified vancomycin (5%) with a new

**Fig. 3:** Effect of drugs on various symptoms on follow-up visits in the two study groups

**Table 4:** Effect of drugs on Bacterial Conjunctival Flora on follow-up visits in two study groups

Follow up	Group A		Group B	
	Positive	Negative	Positive	Negative
Baseline (Day 0)	4	14	4	10
Day 7	0	18	0	14
Day 14	0	18	0	14
Day 21	0	18	0	14

drug combination of moxifloxacin (0.5%) plus vancomycin (2.5%). We found that the both the drugs are equivalent in their efficacy in our study participants. To the best of our knowledge, this study is the first study that compares these two important drugs among bacterial keratitis.

Out of all the patients presented to Eye OPD, we found 32 cases of bacterial keratitis in a study duration of one years. Most of the cases were in young to middle age group (10-50 years) while only 2 out of 32 (6.3%) patients of bacterial keratitis were less than 10 years of age. 12 out of 32 (37.5%) patients of bacterial keratitis were more than 50 years of age. In a study Kareem in 2012 reported that bacterial keratitis, is more common in middle age than in other age groups which is in line with our study.<sup>10</sup> The same study reported that gram stain smears are not very dependable for therapeutic decision in bacterial keratitis and also because of the relatively low positive yield of cultures.<sup>10</sup> Only 3 patients in series had dependable culture results out of 17 smears and scrapings that were performed. Some of the patients were already on topical antibiotics when received and that was one of the possible causes for negative microbial investigations.<sup>10</sup> Cavuoto et al.<sup>11</sup> in 2006 found that Gram-positive pathogens accounted for 52.5% of culture proven cases out of which 72.1% were *S. aureus*. Staphylococcal infections were more common in adults, while *S. pneumoniae* and *H. influenzae* were more common in children. Gangopadhyay et al.<sup>12</sup> in 2000 reported that only 56 (40%) out of 140 samples showed organism on Gram stain. In the present study, only 8 out of 32 (25%) of the corneal scrapping for bacterial keratitis showed organism on Gram stain on Day 0(1stvisit). This may be attributed to excessive use of over the counter topical antibiotic in our study population before reaching our hospital. Gram-positive *S. aureus*, *S. epidermidis*, and several *Streptococcus* and *Bacillus* spp., as well as Gram-negative bacteria like *P. aeruginosa*, *S. marcescens*, *Moraxella lacunata*, *Microbacterium liquefaciens*, and *H. Influenzae* have been reported as common pathogenic organisms causing bacterial keratitis.<sup>13–15</sup> In present study most common causal pathogens were coagulase negative *Staphylococcus* (CoNS) (50%), *S.aureus* (37.5%) and *Streptococcus* spp. (12.5%). 100% of isolated causative pathogens were Gram Positive. This reflects geographical variation of microbial spectrum in bacterial keratitis.

Both the group i.e., Group A eye drop and Group B eye was found to be effective clinically and in eradication

of causative micro-organisms in the patients of bacterial keratitis as confirmed by clinical resolution and microbial culture. All the positive smears became negative in first follow-up (7th day) in both the groups. No significant difference was found in microbiological study outcome between the two-study groups.

We also evaluated clinically in terms of symptomatic relief in bacterial keratitis. We observed that the rate of decline in redness score in both the group was similar and it was found to be statistically insignificant. Similar results were found with the relief in pain and these two drugs were found to be similar in reducing pain. Although the rate of decline in discharge score in eyes installed with group B drug was higher than the group A eyes, but it did not reached the statistically significant level and both the drugs were found to be similar in reducing discharge. Mean size of ulcer and mean are of infiltration in both the group was similar at all the visits and their was no statistically significant difference even in rate of decrease in ulcer size as well as are of infiltration.

## 5. Conclusion

In the present study, combination therapy with moxifloxacin (0.5%) plus vancomycin (2.5%) and fortified vancomycin (5%) alone were evaluated in bacterial keratitis. Their clinical and microbiological response in keratitis was comparable and it may be considered as an alternative to other antimicrobial therapy in drug resistant cases. We conclude that both the drugs, i.e. moxifloxacin (0.5%) plus vancomycin (2.5%) combined therapy and fortified vancomycin (5%) are effective clinically and in eradication of causative organism in patients of bacterial keratitis as confirmed by clinical response and microbial culture.

## 6. Source of Funding

None.

## 7. Conflict of Interest

None.

## References

1. Deshmukh S, Pandey S, Maurya RP, Singh MK, Singh VP. Epidemiology and factors affecting visual acuity in fungal keratitis in Eastern Uttar Pradesh" nd. *J Clin Expe Ophthalmol*. 2015;1(2):68–75.

2. Lichtenstein SJ, Wagner RS, Jamison T, Bell B, Stroman DW. Speed of bacterial kill with a fluoroquinolone compared with nonfluoroquinolones: Clinical implications and a review of kinetics of kill studies. *Adv Ther.* 2007;24(5):1098–12. doi:10.1007/bf02877716.
3. Ohnsman C, Ritterband D, O'Brien T, Girgis D, Kabat A. Comparison of azithromycin and moxifloxacin against bacterial isolates causing conjunctivitis. *Curr Med Res Opin.* 2007;23(9):2241–9. doi:10.1185/030079907x226276.
4. Wilhelmus KR, Hyndiuk RA, Caldwell DR. 0.3% Ciprofloxacin Ophthalmic Ointment in the Treatment of Bacterial Keratitis. *Arch Ophthalmol.* 1993;111:1210.
5. Goodman DF, Gottsch JD. Methicillin-Resistant Staphylococcus epidermidis Keratitis Treated With Vancomycin. *Arch Ophthalmol.* 1988;106:1570.
6. Oguro S, Kasama T, Eguchi H, Shiota H. The inhibitory effect of vancomycin ointment on the manifestation of MRSA keratitis in rabbits. *J Infect Chemother.* 2009;15(5):279–83. doi:10.1007/s10156-009-0708-6.
7. Clark L, Silverstein B, Morris T, Gearinger L, Comstock T, DeCory H. Besifloxacin ophthalmic suspension 0.6% in the treatment of bacterial conjunctivitis patients with Pseudomonas aeruginosa infections. *Clin Ophthalmol.* 2012;6:1987. doi:10.2147/oph.s35715.
8. Abdullah A, Askari SN, Ahmad S, Alvi Y. Assessment and Comparison of Microbiological Efficacy of Moxifloxacin plus Vancomycin Combined Therapy with Fortified Vancomycin in Bacterial Conjunctivitis. *Int Arch BioMed Clin Res.* 2018;4(3):65–8.
9. Herr K, Spratt K, Mobily P, Richardson G. The Clinical journal of pain. *Clin J Pain.* 2004;20:207–19.
10. Kareem AA. Fortified Topical Vancomycin Drops in the Treatment of Bacterial Keratitis. *Med J Babylon.* 2012;9:238–47.
11. Cavuoto K, Zutshi D, Miller D. Investigative ophthalmology & visual science. *Ophthalmol Vis Sci.* 2006;47:1907.
12. Gangopadhyay N. Fluoroquinolone and fortified antibiotics for treating bacterial corneal ulcers. *Br J Ophthalmol.* 2000;84(4):378–84. doi:10.1136/bjo.84.4.378.
13. Green M, Apel A, Stapleton F. Risk Factors and Causative Organisms in Microbial Keratitis. *Cornea.* 2008;27(1):22–7. doi:10.1097/ico.0b013e318156caf2.
14. Green MD, Apel AJG, Naduvilath T, Stapleton FJ. Clinical outcomes of keratitis. *Clin Exp Ophthalmol.* 2007;35(5):421–6. doi:10.1111/j.1442-9071.2007.01511.x.
15. Keay L, Edwards K, Naduvilath T, Forde K, Stapleton F. Factors Affecting the Morbidity of Contact Lens–Related Microbial Keratitis: A Population Study. *Invest Ophthalmol Vis Sci.* 2006;47(10):4302. doi:10.1167/iovs.06-0564.

### Author biography

**Ahmad Abdullah**, Senior Resident

**S N Askari**, Professor

**Shamim Ahmad**, Professor

**Yasir Alvi**, Senior Resident

**Cite this article:** Abdullah A, Askari SN, Ahmad S, Alvi Y. Assessment and comparison of clinico-microbiological efficacy of moxifloxacin plus vancomycin combined therapy with fortified vancomycin in bacterial keratitis. *Indian J Clin Exp Ophthalmol* 2021;7(2):327-332.