



Case Report

A report on intra orbital foreign body presenting as a chronic discharging sinus

Syed Mehabub Ul Kadir¹, Rajendra P Maurya^{2,*}

¹Dept. of Ophthalmology, Bangladesh Eye Hospital and Institute, Dhaka, Bangladesh

²Regional Institute of Ophthalmology, IMS, Banaras Hindu University, Varanasi, Uttar Pradesh, India



ARTICLE INFO

Article history:

Received 16-12-2020

Accepted 19-12-2020

Available online 22-12-2020

Keywords:

Foreign body

CT scan of the orbit

Orbit

Organic

Surgical extraction

ABSTRACT

The visual loss due to retained orbital foreign body may be associated with the ruptured globe, traumatic optic neuropathy, and orbital fracture. Metallic foreign body is more common than non-metallic foreign body. A young male are commonly affected by an orbital foreign body. Our aim is to describe a case report on retained orbital foreign bodies of a young male patient. The presenting feature was chronic discharging sinus. CT scan confirmed the organic foreign body in the orbit. MRI may be done as adjunct to CT scan of the orbit in the cases of wooden foreign body. Surgical extraction was made for two times. A high index of suspicion is mandatory for the suspected case of orbital foreign body. Multiple pieces of wooden foreign may be found.

© This is an open access article distributed under the terms of the Creative Commons Attribution License (<https://creativecommons.org/licenses/by/4.0/>) which permits unrestricted use, distribution, and reproduction in any medium, provided the original author and source are credited.

1. Introduction

An orbital foreign body (FB) is an important cause of ocular morbidity especially in the pediatric and adolescent age group.^{1,2} Complications of orbital foreign bodies consisted of loss of the globe and loss of the vision even after the initial trauma. Orbital foreign body (FB) can be classified into inorganic and organic. Inorganic are metallic (steel, pellet, etc.), and nonmetallic (glass, plastic, and concrete).^{3,4} An organic foreign body is vegetative material like a wooden piece. Organic FB is poorly tolerated than inorganic FB. The common cause of trauma is accidental trauma (fall over objects, road traffic accident, sports related injury, and occupational injury) rather than physical assault.^{1,4} The orbital foreign body may be associated with orbital wall fracture, ruptured globe, traumatic optic neuropathy, avulsion of the eyelid, face and head injury. The decision of the management should be individualized and depends on the types, pattern, size, and location of a foreign body. A surgical extraction is necessary for organic foreign body because of increased risk of infections and

complications.⁵ We attempt to assess a case report with the presentation of chronic discharging sinus and a variety of different patterns of organic foreign bodies in the orbit.

2. Materials and Methods

This case report was evaluated in the national institute of ophthalmology during the period of July to August of 2014. A detailed history was taken and meticulous ophthalmic examination was carried out for the study. Computed tomography (CT) scans and magnetic resonance imaging (MRI) was advised at separate times for diagnosing the foreign body. Obtained written consent and documented all clinical and imaging reports.

3. Case Report

A 15 year-old boy belonging to the rural area of Bangladesh, He presented with painful swelling in the left lower eyelid, Blackish red crust on the lesion, sometimes blood stained pus comes out through the lesion for the last 1 month. He had given a history of an accidental fall from a mango tree on the ground.

* Corresponding author.

E-mail address: mauryarp_bhu@yahoo.com (R. P. Maurya).

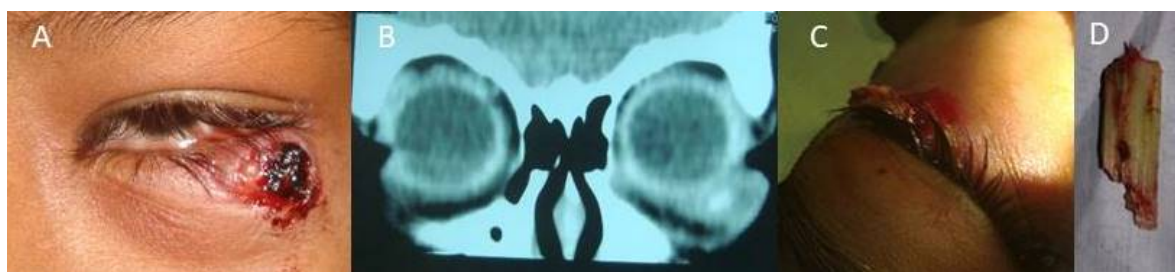


Fig. 1: A-D: A- A 15 -year -old male boy presented chronic discharging sinus in the left lower eyelid, B- CT scan of the orbit showed a hyperdense elongated wooden foreign body, C, D- The extracted wooden foreign body

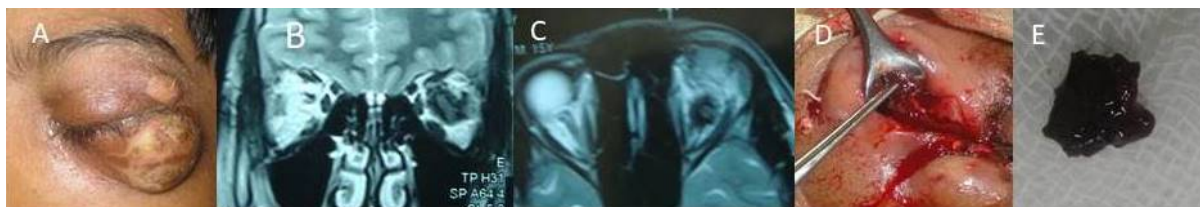


Fig. 2: A-E: A- Patient came after 1 month of extraction of one piece of wooden foreign, presented with left orbital cellulitis, B,C- MRI showed a hypo intense foreign body in the posterior part of the left orbit, D- Surgical extraction of Foreign body, E- The extracted wooden foreign body

He had admitted in a general hospital for the management of generalized trauma of the body. After settling down, they referred to an ophthalmologist for eyelid lesions. Ocular motility showed restricted in abduction and down gaze, visual acuity was recorded as 6/6 in the right eye and 6/24 in the left eye. A hyperdense elongated lesion seen in the inferolateral part of the left orbit, the lesion is close proximity to the left globe; there was soft tissue swelling in the left lower lid and inferolateral part of the left orbit which was suggestive of intraorbital foreign body and a chronic discharging sinus in the left lower eyelid. We extracted the wooden foreign body and evacuated the pus from his left orbit under general *anesthesia*. Infection and swelling were reduced on an oral antibiotic and inflammatory *medication* after surgery. Patient and Patient's guardian *were* happy and discharged from the hospital. Again he had come with left lower eyelid swelling, orbital cellulitis, painful proptosis, ophthalmoplegia, and ptosis. The intravenous broad-spectrum antibiotic was started, and we advised for magnetic resonance imaging (MRI) of the Orbit. The MRI showed a hypointense foreign body compared to fat on T2 weighted images in the most posterior part of the left orbit that was missed in the CT scan previously. Again, the patient had undergone for *re-exploring* the left orbit under general anesthesia by a team approach including an orbit surgeon and a neurosurgeon. We removed a pigmented blood stained irregular almost rectangular shaped wooden foreign body from the posterior part of the left orbit and a clear outlined thin, threadlike strong wooden foreign body extracted using a special neurosurgical instrument from the apex of his left

orbit. After that, patient was cured from further infection and abscess in the left orbit, but his vision was reduced to perception of light.

4. Discussion

A high index of suspicion is necessary while examining a patient with periorbital injuries.^{6,7} Sometimes, the patient may present later with the initial incident forgotten. A careful history should be taken to assess the possible nature of the injury and the pattern of foreign body, to obtain any previous trivial trauma. Our patient gave only a history of fall over the ground but he did not give any history of foreign body. Meticulous ocular examination and radiological assessment may help to assess ocular morbidity, and also help to detect the actual size, the site of orbital foreign bodies. A young male is more common than other age group and female.⁸ The common presenting features of orbital foreign bodies were chronic discharging sinus (37%), open wound (26%), non healing infection (22%), visual loss (15%), and proptosis (15%).⁶ Ideally CT scan of the orbit must be ordered with 1-1.5 cuts of slices.⁴ CT scan is the gold standard imaging technique to detect orbital FB as well as an orbital fracture.^{4,9} CT may give false results if FB is < 0.5mm, and 35% to 40% of non-metallic foreign body.¹⁰⁻¹² Sometimes, wooden FB is difficult to detect on a CT scan as wood may mimic isodense with air or orbital fat.^{10,13} A wooden FB can be hypodense compared to traumatized fat in the presence of blood and inflammation. In MRI, the wood appears as hypointense on both T1 and T2 weighted images compared

to fat in the initial days of trauma, while in later days, it is isodense on T1 and T2 weighted images.^{4,14} Contrast CT/ MRI can be extremely useful in delineating the extent of orbital or intracranial abscess. The CT scan can be ordered to rule out metallic FB before an MRI scan.^{11,15} Contrast study may help to define the fistulous tract. Visual improvement is better in the 85% of anteriorly located orbital foreign body than that of posteriorly located foreign body (30%). The orbital foreign body may be developed no perception of light (NPL) vision. The postoperative visual loss was reported in the literature from 2.5 to 8%.^{2,4,6,8,13,16} Vegetative (wooden) material is poorly tolerated, provides a good medium for microbial agents, and it can cause orbital infection, abscess, and discharging sinus, and sometimes the abscess may extend intracranial space.¹⁷⁻¹⁹ Injuries may appear as a small puncture site/ entry point wound and the FB cannot be found from the surface should also be kept in mind that there may be more than one FB or multiple fragments of a foreign body may be found in the orbit. Time since injury is one of the important documents and it may be a few hours to a few decades. In general, organic FB present earlier than the metallic or glass FB due to the associated complications. The extent of the injury also depends on the size of the FB and the impact velocity. Always need a high index of suspicion for the treatment of orbital foreign body.⁷ If you found one vegetative or wooden FB, search for others fragments of FBs in the orbit.

5. Conclusion

Discharging sinus is one of the common presenting features of the wooden orbital foreign body. Multiple wooden foreign may remain in the orbit and sometimes CT scan may miss the orbital foreign body. The Good quality CT scan is mandatory to detect and localize the foreign body. A high index of suspicion is important for the management of the orbital foreign body. Early management is essential to reduce ocular and adnexal morbidity.

6. Declaration of Patient Consent

The authors certify that they have obtained all appropriate patient consent.

7. Source of Funding

Nil.

8. Conflicts of Interest


There are no conflicts of interest.

References

- Al-Mujaini A, Al-Senawi R, Ganesh A, Al-Zuhaibi S, Aldhuhli H. Intraorbital Foreign Body: Clinical Presentation, Radiological Appearance and Management. *Sultan Qaboos Univ Med J*. 2008;8(1):69-74.
- Fulcher TP, McNab AA, Sullivan TJ. Clinical features and management of intraorbital foreign bodies. *Ophthalmol*. 2002;109(3):494-500. doi:10.1016/s0161-6420(01)00982-4.
- Ho VH, Wilson MW, Fleming JC, Haik BG. Retained Intraorbital Metallic Foreign Bodies. *Ophthalm Plast Reconstr Surg*. 2004;20(3):232-6. doi:10.1097/01.iop.0000129014.94384.e6.
- Finkelstein M, Legmann A, Rubin PAD. Projectile Metallic Foreign Bodies in the Orbit. *Ophthalmol*. 1997;104(1):96-103. doi:10.1016/s0161-6420(97)30355-8.
- Jabang JN, Dampha L, Sanyang B, Roberts CA, Ceasay B. Management of a large intraorbital wooden foreign body: Case report. *Surg Neurol Int*. 2020;11:158. doi:10.25259/sni_204_2020.
- Kadir S, Haider G. Retained Intraorbital Foreign Bodies (IOFB). *Int J Ocul Oncol Oculoplasty*. 2017;3(1):14-8.
- Tas S, Top H. Intraorbital wooden foreign body: clinical analysis of 32 cases, a 10-year experience. *Turk J Trauma Emerg Surg*. 2014;20(1):51-5. doi:10.5505/tjtes.2014.93876.
- Bilge AD. Intraorbital Foreign Bodies: Clinical Features and Outcomes of Surgical Removal. *Turk J Trauma Emerg Surg*. 2016;22(5):432-6. doi:10.5505/tjtes.2016.20925.
- Chaudhary R, Upendran M, Campion N, Yeung A, Blanch R, Morgan-Warren P, et al. The role of computerised tomography in predicting visual outcome in ocular trauma patients. *Eye*. 2015;29(7):867-71. doi:10.1038/eye.2015.39.
- Carrasco JR. Wooden intraorbital foreign body injuries: Clinical characteristics and outcomes of 23 patients. *Ophthalm Plast Reconstr Surg*. 2010;26:238-44.
- Pinto A, Brunese L, Daniele S, Faggian A, Guarnieri G, Muto M, et al. Role of Computed Tomography in the Assessment of Intraorbital Foreign Bodies. *Semin Ultrasound, CT MRI*. 2012;33(5):392-5. doi:10.1053/j.sult.2012.06.004.
- Zhang Y, Cheng J, Bai J. Tiny ferromagnetic intraocular foreign bodies detected by magnetic resonance imaging: a report of two cases. *J Magn Reson Imaging*. 2009;29(3):704-7.
- Shelsta HN, Bilyk JR, Rubin PAD, Penne RB, Carrasco JR. Wooden Intraorbital Foreign Body Injuries: Clinical Characteristics and Outcomes of 23 Patients. *Ophthalm Plast Reconstr Surg*. 2010;26(4):238-44. doi:10.1097/iop.0b013e3181bd7509.
- Prazeres S, Jacomet PV, Galatoire O, Lafitte F, Heran F, Boissonet H. Diagnosis and therapeutic management of an intraorbital organic foreign body. *J Fr Ophthalmol*. 2009;32:8-15.
- Dunkin JM, Crum AV, Swanger RS, Bokhari SAJ. Globe Trauma. *Semin Ultrasound CT MRI*. 2011;32(1):51-6. doi:10.1053/j.sult.2010.09.003.
- Callahan AB, Yoon MK. Intraorbital foreign bodies: retrospective chart review and review of literature. *Int Ophthalmol Clin*. 2013;53(4):157-65.
- Shinder R, Gutman J, Gunasekera CD, Connor M, Nakra T. Occult Orbital Organic Foreign Body. *Ophthalm Plast Reconstr Surg*. 2011;27(6):463-4. doi:10.1097/iop.0b013e31821dc5f6.
- Yadav I, Maurya RP, Bhushan P, Singh MK, Singh VP, Sen PR. Unrecognised large wooden intra-orbital foreign body. *Indian J Clin Exp Ophthalmol*. 2015;1(1):50-5.
- Kadir SM, Haider G. Retained intra-orbital foreign bodies (RIOFB). *Int J Ocul Oncol Oculoplasty*. 2016;3(1):14-8.

Author biography

Syed Mehbub Ul Kadir, Assistant Professor and Consultant  <https://orcid.org/0000-0002-2077-6784>

Rajendra P Maurya, Associate Professor  <https://orcid.org/0000-0001-9343-6003>

Cite this article: Kadir SMU, Maurya RP. A report on intra orbital foreign body presenting as a chronic discharging sinus. *Indian J Clin Exp Ophthalmol* 2020;6(4):657-659.