

A study on clinical outcomes of laser photocoagulation for retinopathy of prematurity

Malathi V.K¹, Ramya Chelliah^{2,*}, KR.Sowmiya³

^{1,2}Assistant professor, Department of ophthalmology, Tagore medical college and hospital, Chennai

³Associate professor, Department of community medicine, Tagore medical college and hospital, Chennai

***Corresponding Author:**

E-mail: ramche12@yahoo.co.in.

ABSTRACT

Introduction: Retinopathy of prematurity (ROP), is a vaso-proliferative disorder of premature infants, especially in those exposed to high concentration of oxygen.


Aim: To analyse the outcomes of laser photocoagulation in ROP.

Materials and Methods: This is a Prospective interventional study of infants admitted in neonatal intensive care unit (NICU), who were less than 1.5 kilograms weight, less than 32 weeks of gestation, and high risk preterm infants outside this criteria were also included. The infants examined were grouped according to whether they required follow up observation or 532 nm-Nd:YAG laser therapy using indirect ophthalmoscopy.

Results: 73(36.14%) babies had ROP. 17 (23.28%) required laser treatment. 14 (82.35%) babies treated with laser recovered whereas 3(17.64%) progressed.

Conclusion: Pre threshold and threshold ROP, have responded very well to laser treatment, reinforcing the need for timely screening and intervention. The use of 532nm laser with good outcome in our study shows its efficacy which is comparable to diode laser.

Key words: Cryotherapy, Laser, Prematurity, ROP.

Access this article online	
Quick Response Code:	Website: www.innovativepublication.com
	DOI: 10.5958/2395-1451.2015.00023.2

INTRODUCTION

Retinopathy of prematurity (ROP) is an important cause of preventable blindness in children [1,6]. Recent advances in neonatal care in the last decade, has increased the survival rates for premature infants. Consequently, the incidence of ROP has increased in parallel [2, 3]. Early identification of retinal damage and the institution of appropriate treatment prevents blindness [1,4].

Retinopathy of prematurity is a disease that affects the immature vasculature in the eyes of premature babies. It can be mild with no visual defects, or it may become aggressive with new blood vessel formation (neovascularization) and progress to retinal detachment and blindness [5].

The CRYO-ROP report has defined the criteria of the "threshold ROP"[6]; the ETROP data, published in December 2003, demonstrated a benefit of earlier treatment compared with conventional management; babies who meet ETROP criteria should be considered eligible for surgical treatment (cryo-therapy, argon or diode laser-therapy)[7]. Clinical trials show that treatment of the disease once it reaches a critical stage

is highly effective at preventing progression to blinding retinal detachment. There has been a promising outcome with the use of 532nm green laser which is reinforced in our study.

AIM

- To analyse the outcomes of laser photocoagulation in retinopathy of prematurity thereby emphasising the importance of early detection and treatment to prevent complications by arresting disease process at early stage.

MATERIALS AND METHODS

Babies admitted in the NICU, in Institute of Child Health and Government Children Hospital, who were either less than 32wks gestation or with birth weight less than 1500gms, during the period July 2010 to Jan 2013 were included in this study.

Inclusion criteria

- birth weight of less than 1500gm
- less than 32 weeks of gestation
- Selected preterm infants with a birth weight between 1500 and 2000 g or gestational age of more than 32 weeks with sickness like need of cardiorespiratory support, prolonged oxygen therapy, apnoea of prematurity, anaemia needing blood transfusion and neonatal sepsis or believed by their attending paediatrician or neonatologist to be at high risk.

This 'third criterion' is important as it brings in many more larger babies into the screening guidelines without raising the screening parameters[8].

Details of gestational age, post conceptional age, birth weight, post natal age, anterior segment examination and posterior segment examination were recorded. The following complications of pre-term were also noted like, birth asphyxia, respiratory distress syndrome, hyperbilirubinemia, seizures, septicaemia and pneumonitis.

The infants satisfying the inclusion criteria were registered. Anterior segment examination was done using hand held slit lamp. Anterior segment examination was done to rule out hazy cornea, shallow anterior chamber, rigid pupil and leucocoria. posterior examination was done using indirect ophthalmoscopy. Examination was conducted in ROP screening cubicle in NICU. Babies were wrapped adequately with a sterile cloth which facilitated examination by restricting movements of the baby as well as providing warmth to the baby.

Care was taken not to disturb the external meiosis of the baby who were in the intensive care unit under artificial ventilator support. Pupil was dilated with 0.25% tropicamide and 0.5% phenylephrine which was instilled three times ten minutes apart, one hour before the fundus examination. 0.5% Paracaine was used as topical anaesthetic. Indirect ophthalmoscopy with scleral indentation was done. Findings were recorded with diagrams and plan of management. Aseptic precautions were taken like washing hands, wearing cap and mask. Sterilised paediatric wire speculum and scleral indenters were used for fundus examination. The infant was monitored with pulsoxymeter and a neonatologist was present during the examination to monitor the baby.

The stages of ROP were classified according to the International Classification of Retinopathy Of prematurity [8, 9, 10], as shown in table 1.

Threshold disease is five contiguous sectors (clock hours) or eight non-contiguous sectors (clock hours) in zone 1 or zone 2 with the presence of plus disease.

prethreshold disease is zone 1 any ROP less than threshold, zone2 stage 2 with plus, zone2 stage 3 without plus, or zone2 stage 3 less than five contiguous clock hours or less than eight non-contiguous clock hours with plus.

The Early Treatment of ROP (ETROP) study successfully categorized characteristics of ROP that may help predict which eyes are most likely to benefit from early peripheral retinal ablation, effectively dividing patients into two groups[11] as shown in table 2.

The authors concluded that all patients with type I ROP should be treated, and all patients with type II ROP should be watched and treated if they progressed to type I characteristics.

Based on these criteria, the babies were grouped into type I and type II ROP.

Ablative therapy was planned for **type I ROP**, defined as zone I any stage with plus, zone I stage 3 without plus, zone II stage 2 or 3 with plus, or zone II, stage 3 without plus as supported by ETROP[11].

A watch and wait approach to **type II ROP**, defined as zone I stage 1 and 2 without plus, or zone II, stage 3 without plus as prescribed by ETROP was followed [11]. Weekly or even twice weekly, follow-up of type II eyes was done to ensure that type II ROP did not progress to type I. Follow-up examinations were based on the exam findings and are listed in table 3.

Photocoagulation was done using frequency doubled 532nm Nd: YAG laser as diode laser was not available in the institute. The treatment was undertaken within the neonatal unit, where the baby could be safely cared for (adequate physiological monitoring with facilities and staff for any rapid intervention needed) while the room is darkened during treatment.

Appropriate continuity of care and post procedure monitoring for adverse events could be ensured when the procedure was done in the neonatal unit.

The infant was fed and burped 30 – 60 minutes before treatment. The pupils were dilated using the combination of 0.25% tropicamide and 0.5% phenylephrine. It was instilled thrice ten minutes apart at least half an hour before the procedure. 0.5% proparacaine was applied topically to anaesthetise the eyes. A sterile paediatric lid speculum was carefully introduced into the conjunctival sac, without touching the cornea.

Photocoagulation of peripheral retina from the ridge to the ora serrata was done using a frequency doubled Neodymium- YAG laser of wavelength 532nm by indirect ophthalmoscope with 28 D condensing lens. Parameters chosen were 978 spots (range, 210-2208 spots; power, 120- 200 mw; duration, 150- 200ms, one burn width apart).

Antibiotic and anti-inflammatory eye drops were given four times a day for a week following laser. The first examination post treatment was done seven days after treatment and was continued weekly for signs of decreasing activity and regression. Retreatment was planned in babies requiring more laser therapy in 10-14 days following initial treatment.

RESULTS

Out of the 202 babies screened, the mean gestational age of babies was 30.25 weeks and the mean birth weight was 1.25kg. As shown in figure one, 73 (36.138%) babies had ROP. 35% were females and 65% were male babies. Three pairs of twins were also affected by ROP among others. Of the 73 infants having ROP, 29(39.72%) infants had stage 1 disease, 24(32.87%) infants had stage 2 disease, 12(16.43%) had stage 3 and 2(2.73%) had stage 4 disease as depicted in figure 2. Babies with ROP were grouped as type IROP

who required laser and type II who did not require laser. The type I group included prethreshold and threshold ROP. They were 17 in number (23.28%) and Type II group had 56(76.71%) infants as seen in figure 3.

As seen in figure 4,14(82.35%) of those who were treated with laser recovered, which included twelve(85.71%) babies who responded with regression after the first sitting, and two(14.28%) babies who

required second sitting. Re-treatment was performed 10 days after initial treatment as there was a failure of the disease to regress. 3(17.64%) babies progressed to severe disease. This included two babies who inspite of second sitting of lasers did not respond and one baby who was brought late for review. This baby was seen to have developed retinal detachment for which surgery was planned. The other two babies were planned for anti VEGF.

Table 1: International classification of ROP

Stage 1	Demarcation line separating the avascular retina anteriorly from vascularised retina posteriorly with abnormal branching of small vessels immediately posterior to this.
Stage 2	Retinal ridge: the demarcation line has increased in volume, but this proliferative tissue remains intraretinal.
Stage 3	Ridge with extraretinal fibrovascular proliferation.
Stage 4	Partial retinal detachment.
Stage 5	Total retinal detachment.
Plus disease	Engorgement of posterior veins and tortuosity of arterioles.

Table 2: Type I and type II ROP

Type I ROP: treat	Type II ROP: watch and wait
Zone I plus with stage 1, 2, or 3	Zone I stage 1 or 2 without plus
Zone I no plus with stage 3	Zone II stage 3 without plus
Zone II with plus stage 2 or 3	

Table 3: Examination schedule for follow up

1-week or less follow-up Stage 1 or 2 ROP: zone I stage 3 ROP: zone II
1- to 2-week follow-up Immature vascularization: zone I— no ROP stage 2 ROP: zone II regressing ROP: zone I
2-week follow-up Stage 1 ROP: zone II regressing ROP: zone II
2- to 3-week follow-up Immature vascularization: zone II — no ROP stage 1 or 2 ROP: zone III regressing ROP: zone III

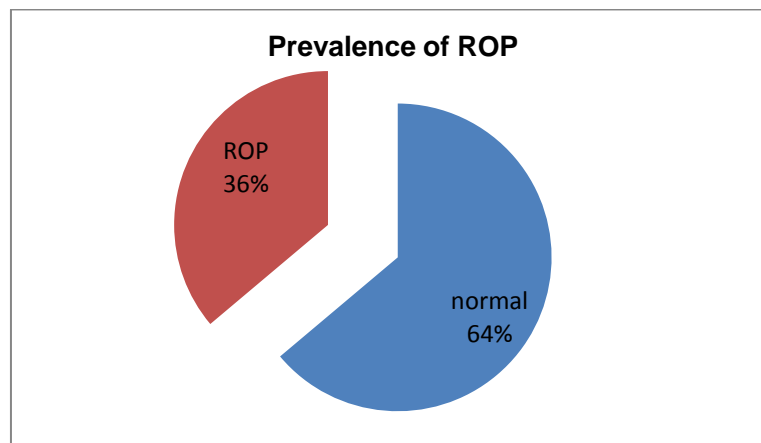


Fig. 1: Prevalence of ROP

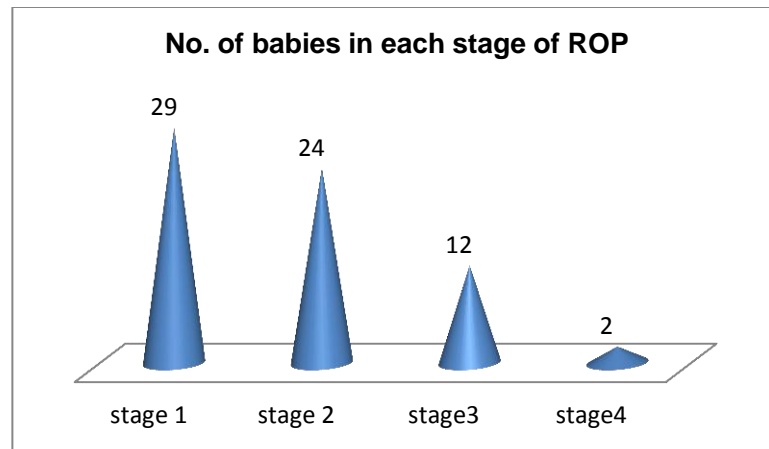


Fig. 2: No. of babies in each stage of ROP

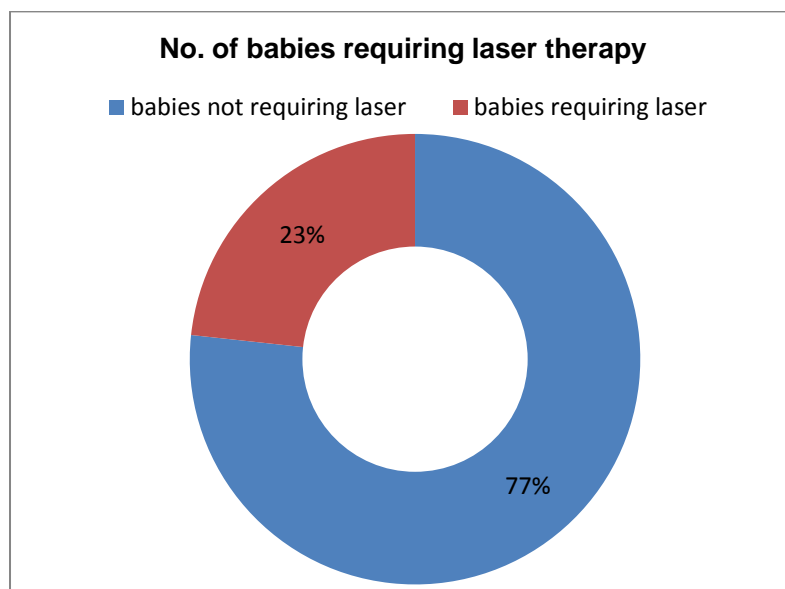


Fig. 3: No. of babies requiring laser therapy

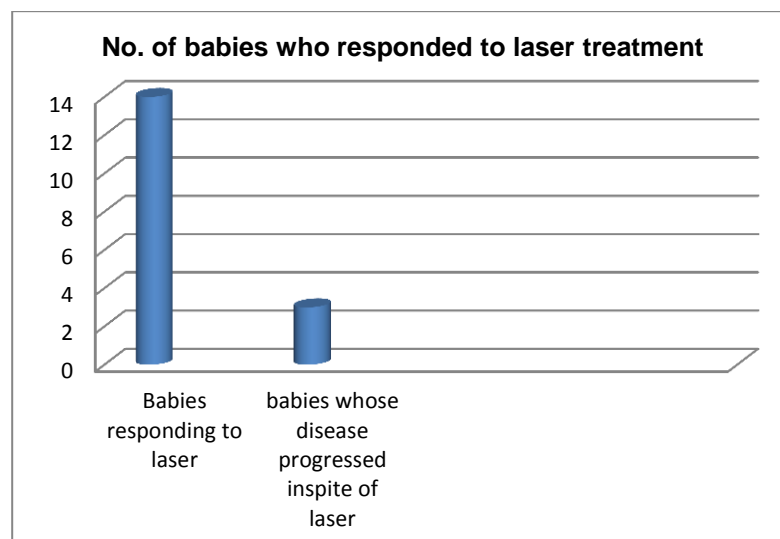


Fig. 4: No. of babies who responded to laser treatment

Image 1: ROP Evaluation Form

VITREO RETINA
R I O & G O H, Chennai-8.

I.C. No : _____
Date : _____
Procedure : _____
Fixed on I _____

R. O. P. EVALUATION FORM

Patient Name _____
Gestational Age _____
POD (Conceptual age (GA + post-natal age)) _____
Weight _____

MRD No. _____
Birth Date _____
Exam Date _____

ANTERIOR SEGMENT

iris rubeosis	OD	yes	no	OS	yes	no
corneal abnormality		yes	no		yes	no
suspect glaucoma		yes	no		yes	no

FUNDUS

vitreous hemorrhage	OD	yes	no	OS	yes	no
plus disease		yes	no		yes	no
pre-threshold (zone 1 any stage, zone 2 with stage 2+, zone 3 or zone 2 stage 3+ but not reaching threshold clock hours. Need to examine in one week)		yes	no		yes	no
threshold (zone 1 or zone 2 with stage 3+, 5 contiguous sectors or 8 composite sectors. Cryotherapy within 72 hours.)		yes	no		yes	no

OD Immature, no R.O.P. _____ Mature _____
R.O.P. Higher stage _____ Lowest zone _____ Total number clock hours _____

OS Immature, no R.O.P. _____ Mature _____
R.O.P. Higher stage _____ Lowest zone _____ Total number clock hours _____

Re-examine in _____ weeks.

Physician's Signature _____

Image 2: Stage 3 ROP image

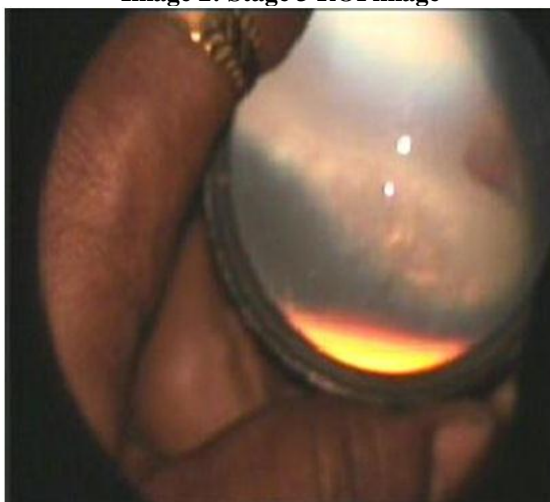
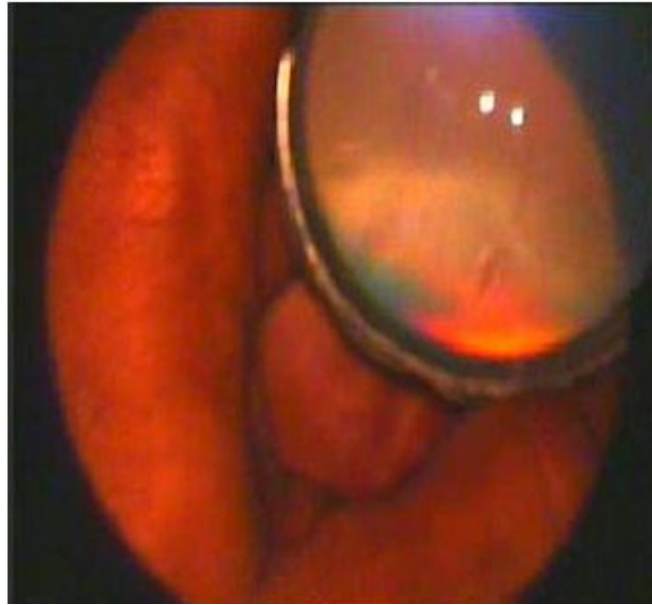

Image 3: post retinal laser photo coagulation

DISCUSSION

Retinopathy of prematurity is a potentially avoidable cause of irreversible and usually total blindness in infants who are born premature. ROP is characterized by abnormal neovascular development in the retina of premature infants. These abnormal blood vessels are fragile and can leak or bleed, scarring the retina and pulling it out of position. This causes a tractional retinal detachment, which is the main cause of visual impairment and blindness in ROP [5].

It is a major cause of blindness in children in middle-income countries and south-east Asia and has lifelong implications for the child and their family. It was a major issue among the developed countries 50-60 years ago [12]. This occurred because all preterm infants were given 100% oxygen whether they needed it or not. Oxygen is highly toxic to blood vessels, including those in the retina [13,14]. After the role of oxygen was understood, and it was used less freely, blindness from ROP declined dramatically. Over the last 10-15 years it has become a major cause of blindness in children in middle-income countries in Latin America, eastern Europe and the emerging economies of southeast Asia [15] (e.g. Vietnam). It is being increasingly reported in China and India.

Blindness from ROP can be controlled through 2 broad approaches:

- Reducing the incidence through excellent neonatal care
- Detecting and treating infants who develop the severe stages of disease

According to WHO, there are 15 million preterm births a year (born at <37 weeks), those most at risk of ROP are those born at <32 weeks gestational age; babies 32-37 weeks are at less risk. Factors which increase the risk of

ROP include preterm birth; too much oxygen; sepsis; chronic lung disease; poor nutrition i.e. less than perfect neonatal care. It is seen that only preterm babies cared for in neonatal intensive care units develop ROP.

India has the largest number of preterm births of any country (ref WHO born too soon, 2012). Unicef is supporting the development of neonatal intensive care units in India.

ROP has a well established classification system, natural history is known: signs develop 3-4 weeks after birth; progression is rapid, but in around 70% of infants the condition resolves without treatment (i.e. 5-10% of all babies screened). It is those who progress who need treatment. Clinical trials show that treatment of the disease once it reaches a critical stage is highly effective at preventing progression to blinding retinal detachment.

Our study reports a prevalence of 36.14% and boys outnumbered girls. Hakeem et al has reported 19.2% in their study, ROP: A study of prevalence and risk factors. João B. Fortes Filho et al has seen a prevalence of 25.5% in his study, conducted in a teaching hospital in Brazil [16].

The incidence of ROP is seen to be on the rise in the developing countries as seen in our study which is supported by the findings of Nadir Ali Mohamed in his study in Brunei showing the prevalence of ROP among the sample of his study to be 34.8%, where, again boys outnumbered girls [17].

It has been proved that ablative treatment of the peripheral retina of immature infants with ROP ameliorates the course of the disease. Peripheral retinal ablation reduces the incidence of adverse ophthalmic outcome in premature infants with threshold ROP [18]. Peripheral retinal ablation of avascular retina anterior to the ridge can be done by either cryotherapy or diode

laser. Abdel h. A. A. Hakeem et al also has found laser photocoagulation to be very effective in regressing ROP[19]. In agreement with Coats et al, they found that their six cases that required laser intervention improved and ROP regressed with regular follow-up.

The CRYO-ROP report has defined the criteria of the "threshold ROP"; the ETROP data, published in December 2003, demonstrated a benefit of earlier treatment compared with conventional management; babies who meet ETROP criteria should be considered eligible for surgical treatment (cryo-therapy, argon or diode laser-therapy)[20,21].

Diode laser ablation has replaced cryotherapy due to lower rate of postoperative ocular and systemic complications and less damage to the adjacent tissues compared with cryotherapy[22]. Other advantages are that the laser spots are visible during treatment minimizing the risk of missing areas requiring treatment, and that laser equipment is portable allowing use outside of the operating theatre. The procedure can be carried out under general anesthesia or under sedation depending on the feasibility and expertise.

In our study, the babies who required laser photocoagulation included both pre threshold and threshold ROP, in accordance with the previous studies. Early treatment for retinopathy of prematurity cooperative group has also agreed that early treatment of high-risk prethreshold ROP significantly reduced unfavourable outcomes to a clinically important degree [7]. Diode laser photocoagulation using indirect ophthalmoscopy is the preferred mode of treatment for ROP [23,24,25]. Argon lasers which were tried earlier were not popular as they induced cataract.

We have used, frequency doubled Nd: YAG 532nm laser, with very good outcome. We did not come across any post laser complications like, cataract, anterior segment ischemia or hyphaema.

Nd; YAG frequency doubled laser is used for adult retinal vascular disorders. But was not used for ROP widely, we used 532 green laser for the treatment of ROP since this was the only available laser in our centre. And we found this promising as the outcome was very good which was comparable to diode and also we did not come across any complications. There are not many studies showing the use of 532nm green laser. Hence, this study helps in proving that ROP can be managed well using 532nm green laser.

Sanghi et al in his retrospective study has compared diode laser with 532 green laser. His study revealed that the number of spots used were almost equal in both the groups. The favourable outcome following treatment was 97% and 96.9% respectively. He also noted that complications were not seen following the use of 532 green laser, also there was much less pain as compared to diode laser. Hence, 532 nm green laser could be used in many centres in developing countries where this might be the only laser available to treat ROP.

The number of infants whose ROP regressed with one laser sitting was high. This fact is reinforced by Sanghi et al in his study where 94% of the infants responded well with one sitting of laser[26]. Rodrigo pessoa cavalcanti lira also has used green laser in his study and signs of ROP regression after first and second sitting of laser therapy were comparable with our results[27].

The number of children who were benefitted by timely screening and management in our study is significant correlating with the previous reports. By proper management with lasers we have seen a positive outcome in the form of regression of the disease. In addition to this we were able to show the promising effects of Nd:YAG lasers comparable to diode lasers.

CONCLUSION

The control of blindness in children is considered a high priority within the world health organization's (WHO's) vision 2020 — the right to sight Programme. Many of the causes of blindness in children are either preventable or treatable. Since ROP is one of the main causes of childhood blindness and is on the higher side in developing countries, we need to address this issue to curb this disease.

A good team work by the obstetrician, neonatologist and the paediatric ophthalmologist where preterm births can be reduced, excellent neonatal care could be given and screening of high risk infants and prompt treatment rendered is absolutely necessary.

Our study stresses the need for good screening at the right time and also advocates the use of 532nm green laser which remains an effective and safe alternative to diode laser photocoagulation and to cryotherapy in the treatment of ROP. Though, randomized clinical trials are necessary to further validate these results.

BIBLIOGRAPHY

1. Cryotherapy for Retinopathy of Prematurity Cooperative Group. Multicenter trial of cryotherapy for retinopathy of prematurity: ophthalmological outcome at 10 years. *Arch Ophthalmol* 2001; 119: 1110–1118.
2. Dominico R, Davis K, Davis O. Documenting the NICU design dilemma: Comparative patient progress in open-ward and single family room units. *J Perinatol*. 2011;31:281–8.
3. Fanaroff AA, Hack M, Walsh MC: The NICHD neonatal research network: changes in practice and outcomes during the first 15 years. *Semin Perinatol* 2003, 27:281–287.
4. Fanaroff AA, Martin RJ, editors. *Neonatal perinatal medicine*. 7th ed. Louis: Mosby; 2002. pp. 676–745.
5. Azad R, Chandra P. Retinopathy of prematurity. *J Indian Med Assoc*. 2005;103:370–2.
6. Cryotherapy for Retinopathy of Prematurity Cooperative Group. Multicenter trial of cryotherapy for retinopathy of prematurity. Three-month outcome. *Arch Ophthalmol* 1990; 108: 195–204.
7. Early Treatment for Retinopathy of Prematurity Cooperative Group. Revised indications for the treatment of retinopathy of prematurity: results of the early treatment for retinopathy of prematurity randomized trial. *Arch Ophthalmol* 2003; 121: 1684–1696.
8. Azad R, Chandra P, Patwardhan SD, Gupta A. Importance of the 'third criterion' for retinopathy of prematurity

- screening in developing countries. *J Pediatr Ophthalmol Strabismus* 2009;46:332-4; quiz 5-6.
9. The International Committee for the Classification of the Late Stages of Retinopathy of Prematurity. An International Classification of Retinopathy of Prematurity. II. The classification of retinal detachment. *Arch Ophthalmol* 1987;105:906-12.
 10. The Committee for the Classification of Retinopathy of Prematurity. An international classification of retinopathy of prematurity. *Arch Ophthalmol* 1984; 102: 1130-1134.
 11. Good WV, ETROP Cooperative Group. Final results of the early treatment for retinopathy of prematurity (ETROP) randomized trial. *Trans Am Ophthalmol Soc.* 2004;102:233-250.
 12. Coats DK, Aaron MM, Mohamed AH. Involution of retinopathy of prematurity after laser treatment: Factors associated with development of retinal detachment. *Am J Ophthalmol.* 2005;140:214-22.
 13. Gilbert C: Retinopathy of prematurity: a global perspective of the epidemics, population of babies at risk and implications for control. *Early Hum Dev* 2008, 84:77-82.
 14. Campbell K: Intensive oxygen therapy as a possible cause of retrolental fibroplasia; a clinical approach. *Med J Aust* 1951, 2:48-50.
 15. Gilbert C, Jugnoo Rahi. Retinopathy of prematurity in middle-income countries. *The Lancet.* July 1997,vol 350:12-14.
 16. João B. Fortes Filho,1 Gabriela U. Eckert,2 Fabiana B. Valiatti,2 Marlene C. da Costa,3 Pedro P. Bonomo,4 and Renato S. Prociányo 5 *Rev Panam Salud Publica/Pan Am J Public Health* 26(3), 2009.
 17. *Int J Ophthalmol.* 2013; 6(3): 381-384. Prevalence of retinopathy of prematurity in Brunei Darussalam. Nadir Ali Mohamed Ali,1 Joshua George,1 Nayan Joshi,1 and Elizabeth Chong2.
 18. Peripheral retinal ablation for threshold retinopathy of prematurity in preterm infants. Andersen CC1, Phelps DL. *Cochrane Database Syst Rev.* 2000;(2):CD001693.
 19. Retinopathy of Prematurity: A Study of Prevalence and Risk Factors Abdel H. A. A. Hakeem, Gamal B. Mohamed, and Mohamed F. Othman. *Arch Ophthalmol.* 2003 Dec;121(12):1684-94.
 20. An International Committee for the Classification of Retinopathy of Prematurity: The International Classification of Retinopathy revisited. *Arch Ophthalmol* 2005, 123:991-999.
 21. Section on Ophthalmology. American Academy of Pediatrics, American Academy of Ophthalmology, American Association for Pediatric Ophthalmology and Strabismus. Screening examination of premature infants for retinopathy of prematurity. *Pediatr* 2006, 117:572-576.
 22. Cordelia C, Alistair F, Edmund A. Management of retinopathy of prematurity. *Current Paediatr.* 2005;15:99-105.
 23. Hunter DG, Repka MX. Diode laser photocoagulation for threshold retinopathy of prematurity. A randomized study. *Ophthalmology* 1993; 100: 238-244.
 24. Laser ROP Study Group. Laser therapy for retinopathy of prematurity. *Arch Ophthalmol* 1994; 112: 154-156.
 25. Ng EY, Connolly BP, McNamara JA, Regillo CD, Vander JF, Tasman W. A comparison of laser photocoagulation with cryotherapy for threshold retinopathy of prematurity at 10 years: part 1. Visual function and structural outcome. *Ophthalmology* 2002; 109: 928-934, discussion 935.
 26. G. Sanghi, M R Dogra, A vinekar, A Gupta. Frequency doubled YAG laser versus diode laser in the treatment of retinopathy of prematurity. *Br J of Ophthalmol* 2010;94:1264-1265.
 27. Lira, Rodrigo Pessoa Cavalcanti et al. Efficacy and safety of green laser photocoagulation for threshold retinopathy of prematurity. *Arq. Bras. Oftalmol.* [online]. 2008, vol.71, n.1 [cited 2015-08-27], pp. 49-51.