

# OCT Normative Database of Macula in the Paediatric Population

Ojha Sushil<sup>1,\*</sup>, Jain Vaibhav<sup>2</sup>, Sharma Reena<sup>3</sup>, Singh Brijesh<sup>4</sup>, Shukla Dipendra<sup>5</sup>

<sup>1</sup>Senior Resident, <sup>2,3</sup>Assistant Professor, <sup>4</sup>Lecturer, <sup>5</sup>Junior Resident,  
Dept. of Ophthalmology, UP RIMS and R, Saifai, Etawah, UP

**\*Corresponding Author**

E-mail: drsushilojha@gmail.com

## ABSTRACT

**Purpose:** Macular thickness parameters in normal paediatric population of central India

**Materials and Methods:** This observational cross sectional study was conducted at UPRIMS AND R (Uttar Pradesh Rural Institute of Medical Sciences and Research) Saifai, Etawah to detect normative optical coherence tomography database for paediatric population in central Indian region. The total 70 of normal Indian children (eyes) after thorough ocular examination were enrolled from eye out patient department (OPD).

The macular thickness was measured using cirrus high definition optical coherence tomography (OCT)

### Inclusion criteria

- Children with normal 6/6 visual acuity,
- Any child of any age 5- 17 years but cooperative for doing OCT

### Exclusion criteria

- Children with strabismus or amblyopia
- family history of glaucoma
- any hereditary eye disease
- history of intraocular surgery or any kind of laser therapy,
- mentally challenged children with neurological, metabolic, vascular disorders,
- other systemic disease possibly affecting the eye, presence of a media opacity,
- best corrected visual acuity of less than 6/9,
- hypermetropia more than + 3D, myopia more than -5D, or astigmatism more than 2D were also excluded.

In most of the cases both eyes were examined, using OCT and selected for normative database calculation. We also further tried to analyse whether sex and different age subgroups had any significant difference or not.

The subjects enrolled had no ocular problems. The children came for routine eye examination in Ophthalmology OPD or paediatrics OPD or brother of patient or cousin of patient were enrolled when they met the inclusion and exclusion criteria.

The complete Ophthalmological examination was done in all children including BCVA (best corrected visual acuity), IOP (intraocular pressure by tonopen), anterior segment examination by slit lamp, assessment of squint by cover test, cover-uncover test and posterior segment examination under mydriasis with slit lamp using 90D or Indirect ophthalmoscopy.

Dilatations of pupil were done with tropicamide 1% for posterior segment examination. If required cycloplegia was done using homatropine or cyclopentolate (1% or 2%). The macular thickness was then measured with OCT. The OCT machine used was Stratus OCT, software version 4.0.4, Carl Zeiss, Dublin, CA.

### Results:

**Demographics:** 70 subjects consented for the study. Out of these 5 (7.1%) were uncooperative and scan could not be done in them. One(1) subject had leucomatous corneal opacity in the left eye. 12 (9.3%) scans out of 129 were excluded because of poor scan quality. So a total of 59 children (117 eyes) were included in statistical analysis there were 36 male and 23 females. Among the total children 28 children were between 5-10years age group and 31 were between 11-16 years age group. There was no statistically significant difference between male and female average macular thickness, despite having higher male in the study. (36 male and 23 female)

**Macular thickness:** The mean central macular thickness was  $243.26 \pm 22.136 \mu\text{m}$  (range was from  $183 \mu\text{m}$ - $290 \mu\text{m}$ ). The mean macular thickness in males was  $241.97 \pm 22.773 \mu\text{m}$  (range  $219$ - $264 \mu\text{m}$ ) and that in females was  $239.70 \pm 23.092 \mu\text{m}$  (range  $216$ - $262 \mu\text{m}$ ). There was no statistical difference in the CMT in between males and females. This data has been shown in fig:4 (histogram). In regression analysis, it was found that in between 5-10 years age group mean CMT was  $238.96 \pm 20.723 \mu\text{m}$  (range was from  $260 \mu\text{m}$  - $218 \mu\text{m}$ ) and between 11-16 years age group mean CMT was  $243.00 \pm 24.576 \mu\text{m}$  ( range was from  $267 \mu\text{m}$  - $218 \mu\text{m}$ ) but this had no statistically significant ( $P = 0.0702$ ) effect on macular thickness.

The macular thickness was found to be greatest in nasal quadrant followed by superior, inferior and then temporal (table 1). Furthermore thickness was found to be more in the inner macular area (3 mm area).

**Conclusion:** In conclusion we analysed the normative database on OCT for for macular thickness in paediatric age in rural population of central India. The macular thickness noted in our study is comparable to that than reported in literature. The data obtained from the study would help in OCT evaluation for macular disorders. The Study would further help in characterising OCT scan to be normal or pathological if it lies outside the 2 standard deviation obtained in our study in children of central India.

**Keywords:** Indian children, OCT, macular thickness

Access this article online	
Quick Response Code:	Website: www.innovativepublication.com
	DOI: 10.5958/2395-1451.2015.00021.9

## INTRODUCTION

Optical coherence tomography (OCT) is a noninvasive, noncontact, trans-pupillary imaging method that performs objective high-resolution cross-sectional images of retinal tissue. The spectral domain OCT (SD-OCT) has now superseded time-domain OCT in most parts of the world. SD-OCT provides measurements of the macula with greatly improved image acquisition speed and image resolution up to  $5 \mu\text{m}^{(1)}$ . This is particularly helpful during the examination of an uncooperative children. Several reports suggest that the macular thickness vary between ethnic groups<sup>(2)</sup> Therefore, data documenting normal macular measurements in healthy Indian subjects are imperative to clinicians to help them make informed decisions on pathologic changes in this ethnic group. Several studies have proved the feasibility of OCT in the paediatric population<sup>(3-10)</sup>. Nevertheless, all OCT devices have an integrated normative database only for adult subjects 18 years of age and older. Only a few studies in the literature aimed at reporting normative reference ranges using SD-OCT<sup>(11-16)</sup>. Normative measurements in children using Cirrus are least reported, especially with regards to macular parameters. The clinical applications of SD-OCT are increasingly expanding<sup>(17)</sup> so normal reference values for macular thickness are needed in the paediatric population where the OCT has no nomogram for comparison. The purpose of this study was to collect normative values for SD-OCT measurements of macular thickness in healthy eyes of normal children using the most recent commercially available Cirrus SD-OCT.

## MATERIALS AND METHODS

It is an observational cross sectional study done at Uttar Pradesh Rural Institute of Medical Sciences and Research, Saifai, Etawah.

The study was done to detect normative optical coherence tomography database for paediatric population in central Indian region. The total 70 of normal Indian children(eyes) after thorough ocular examination were enrolled from eye out patient department (OPD).

The macular thickness was measured using cirrus high definition optical coherence tomography (OCT)

### Inclusion Criteria

- Children with normal 6/6 visual acuity,
- Any child of any age 5- 17 years but cooperative for doing OCT

### Exclusion Criteria

- Children with strabismus or amblyopia
- family history of glaucoma
- any hereditary eye disease
- history of intraocular surgery or any kind of laser therapy,
- mentally challenged children with neurological, metabolic, vascular disorders,
- other systemic disease possibly affecting the eye, presence of a media opacity,
- best corrected visual acuity of less than 6/9,
- hypermetropia more than + 3D, myopia more than – 5D, or astigmatism more than 2D were also excluded.

Most of cases both eyes were examined using OCT and selected for normative database calculation. We also further tried to analyse whether sex and different age subgroups had any significant difference or not.

The subjects enrolled had no ocular problems. The children came for routine eye examination in Ophthalmology OPD or paediatrics OPD or brother of patient or cousin of patient were enrolled when they met the inclusion and exclusion criteria.

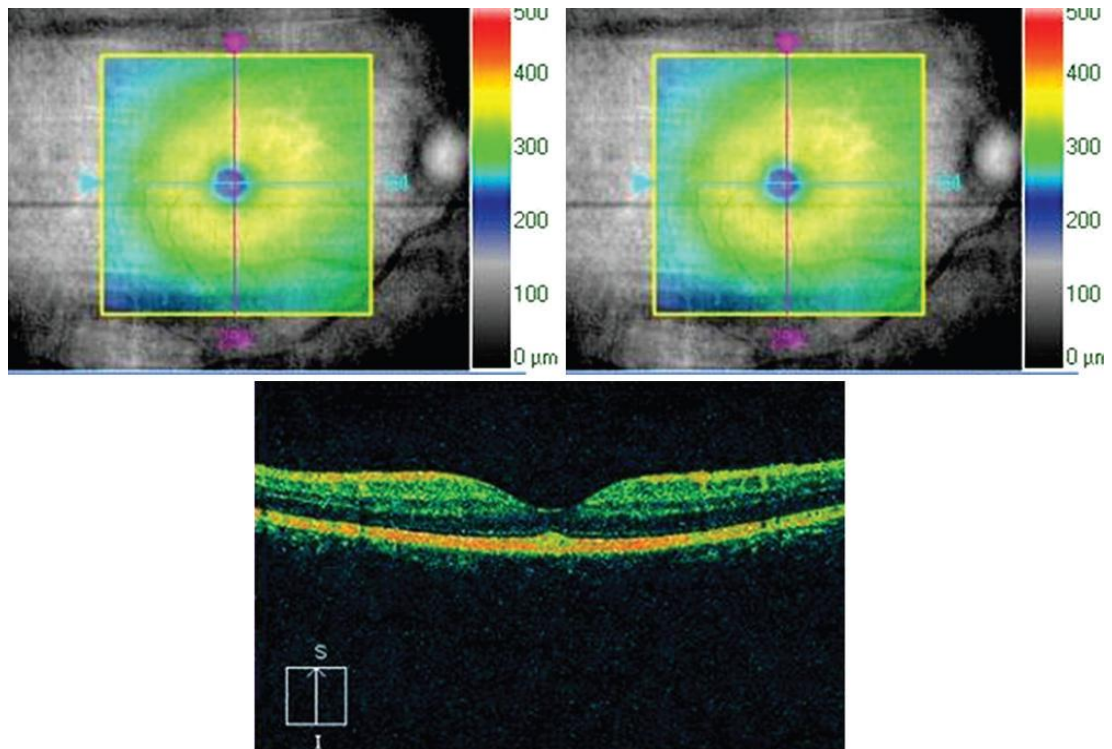
The complete Ophthalmological examination was done in all children. It included BCVA(best corrected visual acuity), IOP (intraocular pressure by tonopen), slit lamp anterior segment examination, assessment of squint by cover test, cover-uncover test and dilated posterior segment examination with slit lamp using 90D or Indirect ophthalmoscopy.

Dilatation of pupil were done with tropicamide 1% for posterior segment examination. If required cycloplegia was done using homatropine or cyclopentolate (1% or 2%).The macular thickness was then measured with OCT. The OCT machine used was Cirrus OCT, software version 4.0.4, Carl Zeiss, Dublin, CA.

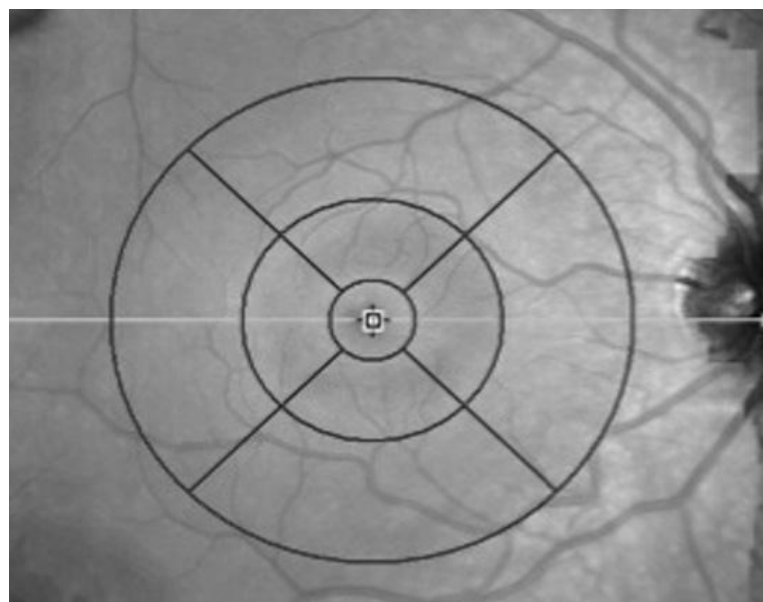
The OCT uses partial coherence interferometry using wavelength of 840nm for obtaining cross sectional image and achieves axial resolution of  $5\mu\text{m}$  and scanning rate of 27kHz. OCT is the very good diagnostic tool which has very high intra-observer and inter-observer reproducibility<sup>(18,19)</sup>. OCT reading is not affected by pupillary diameter or optical aberrations, but in our study we used only dilated pupil for measurement on OCT scans, as children are not very cooperative for the examination<sup>(20)</sup>.  $512 \times 128$  B-scans from top to bottom protocol were used for retinal thickness assessment. The software then constructs a retinal map by aligning the B-scans. In addition to creating a retinal thickness map, the SD-OCT software calculates the retinal volume for each map.[14,15] Each scan was individually reviewed, and segmentation lines were adjusted to ensure the accuracy in macular thickness measurements. Macular thickness is reported in a modified Early Treatment of Diabetic Retinopathy Study (ETDRS) macular map with the central subfield 1 mm in diameter and the inner and outer subfields

having diameters of 3 mm and 6 mm, respectively [Fig. 1a-c]. The retinal thickness in the inner and outer subfields, the central foveal thickness (CFT), the centre point thickness (CPT), and the macular volume were calculated. CPT was defined as the average of 6 radial scans centred at the foveola, whereas the CFT was defined as the average of all points within the central 1 mm diameter circle surrounding fixation [Fig. 2].<sup>(16)</sup> All

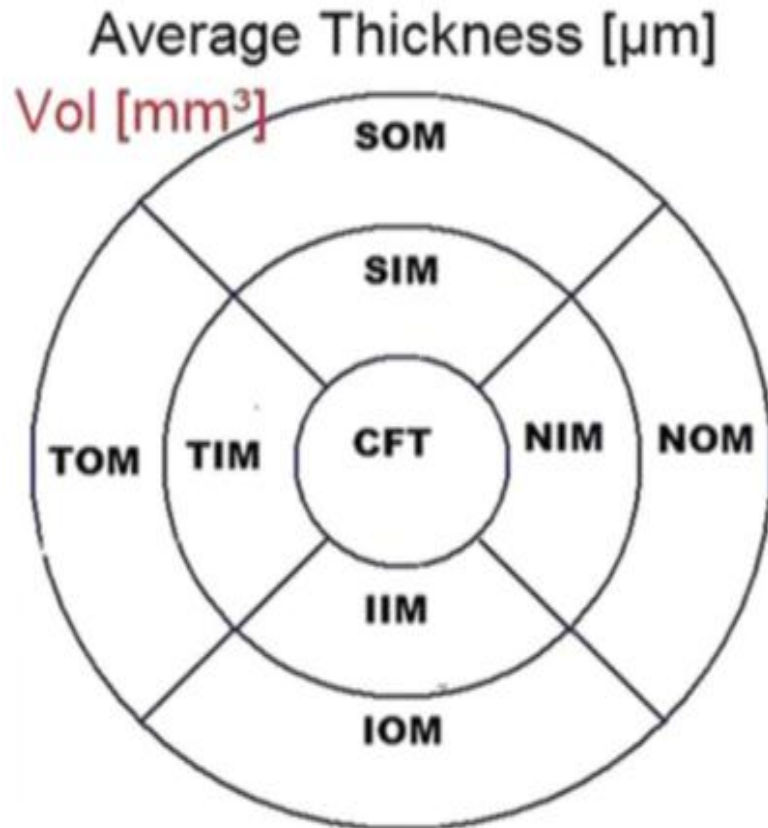
OCT scans were performed by the authors themselves. The internal fixation target was given in all children for scan and the proper centration was observed using inbuilt infrared sensitive live camera view before taking OCT scan on computer monitor. The OCT scan was taken only if they were not having any artefacts and signal strength  $\geq 7$ .



**Fig. 1:** Macular thickness map as seen on OCT(above), Section of various layers of retina through fovea as seen on OCT(below).



**Fig. 2:** Early Treatment Diabetic Retinopathy Study subfield template used to derive macular thickness measurements from different regions of the macula. Circles are 1, 3, and 6 mm in diameter



**Fig. 3: division of macula into central fovea, inner macula, and outer macula. CFT: Central foveal thickness, SIM: Superior inner macula, NIM: Nasal inner macula, IIM: Inferior inner macula, TIM: Temporal inner macula, SOM: Superior outer macula, NOM: Nasal outer macula, IOM: Inferior outer macula, TOM: Temporal outer macula. Measurements have been done under these headings.**

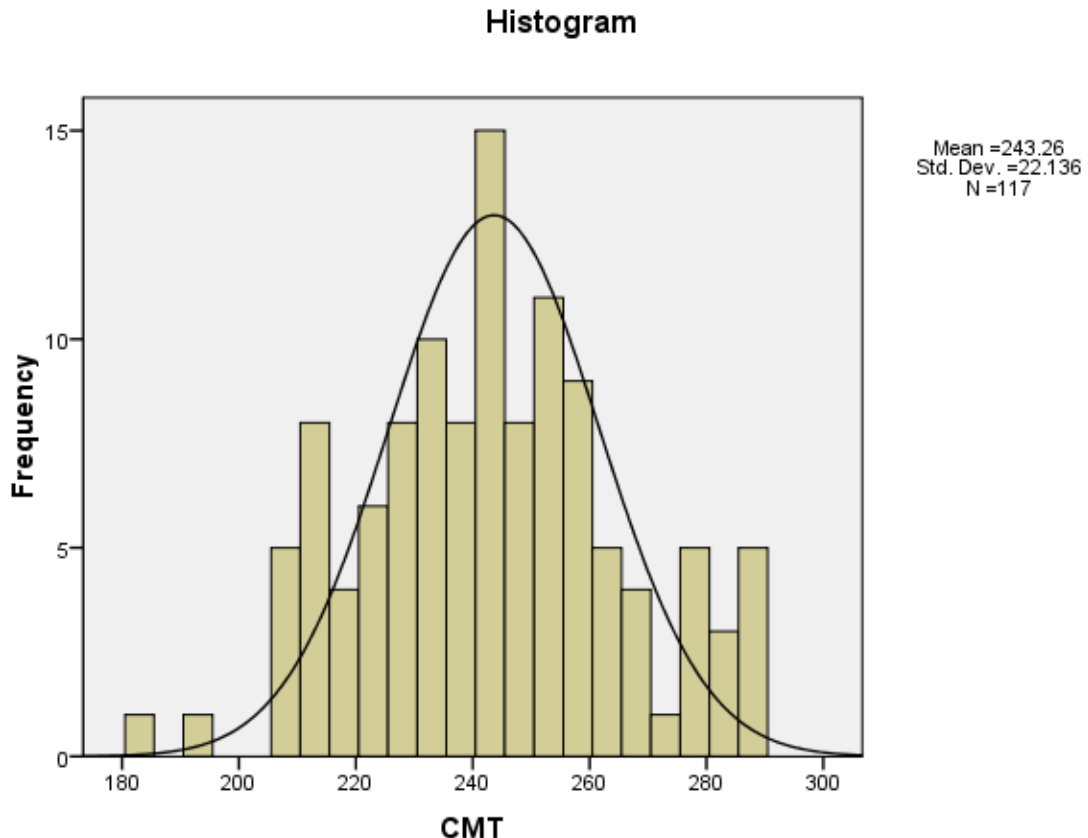
## RESULTS

**Demographics:** 70 subjects consented for the study. Out of these 5 (7.1%) were uncooperative and scan could not be done in them. One(1) subject had leucomatous corneal opacity in the left eye. 12 (9.3%) scans out of 129 were excluded because of poor scan quality. So a total of 59 children (117 eyes) were included in statistical analysis there were 36 male and 23 females. Among the total children 28 children were between 5-10years age group and 31 were between 11-16years age group. There was no statistically significant difference between male and female average macular thickness, despite having higher male in the study. (36 male and 23 female)

**Macular Thickness:** The mean central macular thickness was  $243.26 \pm 22.136 \mu\text{m}$  (range was from

$183\mu\text{m}$ - $290\mu\text{m}$ ). The mean macular thickness in males was  $241.97 \pm 22.773\mu\text{m}$  (range 219-264 $\mu\text{m}$ ) and that in females was  $239.70 \pm 23.092 \mu\text{m}$  (range 216-262  $\mu\text{m}$ ). There was no statistical difference in the CMT in between males and females. This data has been shown in fig:4 (histogram). In regression analysis, it was found that in between 5-10 years age group mean CMT was  $238.96 \pm 20.723 \mu\text{m}$  (range was from 260  $\mu\text{m}$  -218 $\mu\text{m}$ ) and between 11-16 years age group mean CMT was  $243.00 \pm 24.576 \mu\text{m}$  ( range was from 267 $\mu\text{m}$  -218 $\mu\text{m}$ ) but this had no statistically significant ( $P = 0.0702$ ) effect on macular thickness.

The macular thickness was found to be greatest in nasal quadrant followed by superior, inferior and then temporal (Table 1). Furthermore thickness was found to be more in the inner macular area (3 mm area).



**Fig 4: Histogram showing distribution of macular thickness in normal pediatric population from mean.**

**Table 1: Distribution of macular measurements using Cirrus optical coherence tomography**

Measurements	All ages	
	Mean $\pm$ standard deviation	
	Male	Female
<b>Macular thickness, <math>\mu\text{m}</math></b>		
Central	<b>249.20<math>\pm</math>19.381</b>	<b>239.83<math>\pm</math>23.671</b>
<b>Inner Circle</b>		
Superior	315.22 $\pm$ 31.545	308.04 $\pm$ 22.035
Nasal	316.1 $\pm$ 24.701	311.48 $\pm$ 20.565
Temporal	303.10 $\pm$ 23.156	296.89 $\pm$ 18.570
Inferior	312 $\pm$ 30.347	307.13 $\pm$ 17.180
<b>Outer Circle</b>		
Superior	277.4 $\pm$ 12.18	276.43 $\pm$ 14.53
Nasal	292.8 $\pm$ 17.92	295.17 $\pm$ 19.30
Temporal	258.16 $\pm$ 32.03	256.41 $\pm$ 14.29
Inferior	268.93 $\pm$ 11.68	264.34 $\pm$ 15.09

## DISCUSSION

Optical coherence tomography is increasingly being utilized as a diagnostic and monitoring tool in children with visual loss. SD-OCT being noninvasive, is gaining more popularity in identifying, monitoring, and classifying children with genetic retinal diseases such as Leber congenital amaurosis, retinitis pigmentosa, and Stargardt disease, or with abnormal retinal development such as in retinopathy of prematurity<sup>(21)</sup>. SD-OCT, the latest generation of the technology, provides higher resolution and decreased acquisition time, hence is

more useful in the pediatric population. Direct comparison of macular parameters between TD-OCT and SD-OCT is not possible due to different scanning algorithms.<sup>(21-23)</sup> Studies using the earlier TD-OCT in children have shown good reproducibility<sup>(19,5)</sup> Altemir *et al.* showed good reliability and repeatability in children using cirrus SD-OCT<sup>(5)</sup>. With Stratus OCT, good quality scans could be obtained in 93% and 96% of children. Using spectralis SD-OCT, Turk, *et al.* reported higher feasibility of 99%.<sup>(22)</sup> Using cirrus OCT scans Al-Haddad *et al.*<sup>(13)</sup> reported a feasibility of 96%



of enrolled children. In our study, we were able to get a good scan (signal strength  $\geq 6$ ) in 92.35% enrolled children. Most available literature reporting normative macular thickness OCT values in children either used TD-OCT<sup>(6-10)</sup> or recently, Spectralis in Turkish and North American children<sup>(21,22)</sup> and RTVue-100 OCT in Chinese children.<sup>(23)</sup> While Elia and Barrio-Barrio<sup>(12)</sup> reported normative values in the Spanish population. The study by Barrio-Barrio tried to address similar objectives as the current study; differences in design include the multicenter nature of their study and the different age group (4–17 years in their study, 6–17 years in our study). During macular thickness analysis we have excluded 12 eyes out of 129 eyes (9.3%) due to poor signal strength. So, we can conclude that even after following strict inclusion and exclusion criteria around 9.3% scan were of low signal strength proves that, getting a good quality OCT scan in children requires experience in dealing with children and optimized image before capturing OCT scan.

The normative database of OCT is normally feeded only for the individuals more than 18 years, which limits its widespread application in childhood disorders. The mean central macular thickness was  $243.26 \pm 22.136 \mu\text{m}$  (range was from  $183 \mu\text{m}$ - $290 \mu\text{m}$ ). The mean macular thickness in males was  $241.97 \pm 22.773 \mu\text{m}$  (range  $219$ - $264 \mu\text{m}$ ) and that in females was  $239.70 \pm 23.092 \mu\text{m}$  (range  $216$ - $262 \mu\text{m}$ ). There was no statistical difference in the CMT in between males and females. between 5-10 years age group mean CMT was  $238.96 \pm 20.723 \mu\text{m}$  (range was from  $260 \mu\text{m}$  - $218 \mu\text{m}$ ) and between 11-16 years age group mean CMT was  $243.00 \pm 24.576 \mu\text{m}$  (range was from  $267 \mu\text{m}$  - $218 \mu\text{m}$ ) but this had no statistically significant ( $P = 0.0702$ ) effect on macular thickness. The mean CMT measured in present study is not affected by different age groups. Macular parameters show the greatest variability among different OCT devices and algorithms<sup>(24)</sup>. Discrepancies have also been noted across different versions of OCT<sup>(25,26,27)</sup>. Average macular thickness was highest on Spectralis ( $326 \mu\text{m}$ ), followed by Cirrus ( $280$ - $284 \mu\text{m}$ ) and Stratus ( $240$ - $270 \mu\text{m}$ ). Yanni et al. Reported mean macular thickness ( $271 \mu\text{m}$ ) on Spectralis.

### LIMITATION

The study is conducted in children of rural India only. So, it's not a representation of general population. So, generalised use of normative database is questionable. But it can be useful for the rural children and making gross evaluation of macular thickness in Indian children.

Another limitation was axial lengths were not calculated in the children.

### CONCLUSION

This study established normal reference ranges for macular parameters measured by Cirrus SD-OCT in healthy northern central population in <18 years age

group. This adds another database to the available literature on normative values using other OCT devices and facilitates evaluation of OCT measurements in children with macular diseases. The data presented is of north Indian children; hence, other subjects of other regions of India should be studied in future research. The study emphasizes the need for the development of a separate database of cirrus SD-OCT for Indian paediatric population for reference. It establishes the importance of the fact that age and gender warrants special consideration during Cirrus SD-OCT interpretations in children.

### REFERENCES

1. Leung CK, Cheung CY, Weinreb RN, Qiu Q, Liu S, Li H, et al. Retinal nerve fiber layer imaging with spectral-domain optical coherence tomography: A variability and diagnostic performance study. *Ophthalmology* 2009;116:1257-63,1263.e1.
2. Bendschneider D, Tornow RP, Horn FK, Laemmer R, Roessler CW, Juenemann AG, et al. Retinal nerve fiber layer thickness in normals measured by spectral domain OCT. *J Glaucoma*. 2010;19:475-82.
3. Altemir I, Pueyo V, Elía N, Polo V, Larrosa JM, Oros D. Reproducibility of optical coherence tomography measurements in children. *Am J Ophthalmol* 2013;155:171-176.e1.
4. Salchow DJ, Oleynikov YS, Chiang MF, Kennedy-Salchow SE, Langton K, Tsai JC, et al. Retinal nerve fiber layer thickness in normal children measured with optical coherence tomography. *Ophthalmology* 2006;113:786-91.
5. Eriksson U, Holmström G, Alm A, Larsson E. A population-based study of macular thickness in full-term children assessed with Stratus OCT: Normative data and repeatability. *Acta Ophthalmol* 2009;87:741-5.
6. El-Dairi MA, Asrani SG, Enyedi LB, Freedman SF. Optical coherence tomography in the eyes of normal children. *Arch Ophthalmol* 2009;127:50-8.
7. Leung MM, Huang RY, Lam AK. Retinal nerve fiber layer thickness in normal Hong Kong chinese children measured with optical coherence tomography. *J Glaucoma* 2010;19:95-9.
8. Huynh SC, Wang XY, Rohtchina E, Mitchell P. Peripapillary retinal nerve fiber layer thickness in a population of 6-year-old children: Findings by optical coherence tomography. *Ophthalmology* 2006;113:1583-92.
9. Huynh SC, Wang XY, Rohtchina E, Mitchell P. Distribution of macular thickness by optical coherence tomography: Findings from a population-based study of 6-year-old children. *Invest Ophthalmol Vis Sci* 2006;47:2351-7.
10. Ahn HC, Son HW, Kim JS, Lee JH. Quantitative analysis of retinal nerve fiber layer thickness of normal children and adolescents. *Korean J Ophthalmol* 2005;19:195-200
11. Hess DB, Asrani SG, Bhide MG, Enyedi LB, Stinnett SS, Freedman SF. Macular and retinal nerve fiber layer analysis of normal and glaucomatous eyes in children using optical coherence tomography. *Am J Ophthalmol* 2005;139:509-17.
12. Barrio-Barrio J, Noval S, Galdós M, Ruiz-Canela M, Bonet E, Capote M, et al. Multicenter Spanish study of spectral-domain optical coherence tomography in normal children. *Acta Ophthalmol* 2013;91:e56-63.
13. Al-Haddad C, Barikian A, Jaroudi M, Massoud V, Tamim H, Nouredin B. Spectral domain optical coherence tomography in children: Normative data and biometric correlations. *BMC Ophthalmol* 2014 22;14:53.

14. Gupta V, Gupta P, Singh R, Dogra MR, Gupta A. Spectral-domain Cirrus high-definition optical coherence tomography is better than time-domain Stratus optical coherence tomography for evaluation of macular pathologic features in uveitis. *Am J Ophthalmol* 2008;145:1018-1022.
15. Leung CK, Cheung CY, Weinreb RN, Lee G, Lin D, Pang CP, *et al.* Comparison of macular thickness measurements between time domain and spectral domain optical coherence tomography. *Invest Ophthalmol Vis Sci* 2008;49:4893-7.
16. Appukuttan B, Giridhar A, Gopalakrishnan M, Sivaprasad S. Normative spectral domain optical coherence tomography data on macular and retinal nerve fiber layer thickness in Indians. *Indian J Ophthalmol* 2014;62:316-21.
17. Salchow DJ, Hutcheson KA: Optical coherence tomography applications in pediatric ophthalmology. *J Pediatr Ophthalmol Strabismus* 2007, 44:335-349.
18. Blumenthal EZ, Williams JM, Weinreb RN, Girkin CA, Berry CC, Zangwill LM. Reproducibility of nerve fiber layer thickness measurements by use of optical coherence tomography. *Ophthalmology*. 2000;107:2278-82.
19. Wang XY, Huynh SC, Burlutsky G, Ip J, Stapleton F, Mitchell P. Reproducibility of and effect of magnification on optical coherence tomography measurements in children. *Am J Ophthalmol*. 2007;143:484-8.
20. Savini G, Zanini M, Barboni P. Influence of pupil size and cataract on retinal nerve fiber layer thickness measurements by Stratus OCT. *J Glaucoma*. 2006;15:336-40.
21. Yanni SE, Wang J, Cheng CS, Locke KI, Wen Y, Birch DG, *et al.* Normative reference ranges for the retinal nerve fiber layer, macula, and retinal layer thicknesses in children. *Am J Ophthalmol* 2013;155:354-360.e1.
22. Turk A, Ceylan OM, Arici C, Keskin S, Erdurman C, Durukan AH, *et al.* Evaluation of the nerve fiber layer and macula in the eyes of healthy children using spectral-domain optical coherence tomography. *Am J Ophthalmol* 2012;153:552-559.e1.
23. Tsai DC, Huang N, Hwu JJ, Jueng RN, Chou P. Estimating retinal nerve fiber layer thickness in normal schoolchildren with spectral-domain optical coherence tomography. *Jpn J Ophthalmol* 2012;56:362-70.
24. Geitzenauer W, Kiss CG, Durbin MK, Abunto MT, Callan TM, Stetson PF, Wieland MR, Bressier NM, Gregori G, Schmidt-Erfurth UM: Comparing retinal thickness measurements from Cirrus spectral domain- to Stratus time domain- optical coherence tomography. *Retina* 2010, 30:596-606.
25. Kanamori A, Nakamura M, Tomioka M, Kawaka Y, Yamada Y, Negi A: Agreement among three types of spectral-domain optical coherent tomography instruments in measuring parapapillary retinal nerve fibre layer thickness. *Br J Ophthalmol* 2012, 96:832-837.
26. Pierre-Kahn V, Tadayoni R, Haouchine B, Massin P, Gaudric A: Comparison of optical coherence tomography models OCT 1 and Stratus OCT for macular and retinal thickness measurement. *Br J Ophthalmol* 2005, 89:1581-1585.
27. Ojha Sushil , Sharma Reena, Tandon Anupama, Jain Vaibhav, Singh Brijesh, Babbar Meenu and Shukla Dipendra Retinal Nerve Fiber Layer Thickness in Normal Indian Pediatric Population of North India Measured with Optical Coherence Tomography *Ophthalmology Research: An International Journal* 2016 Vol 5(2): 1-6, 2016, 1-6.