



## Case Report

## Fulminant orbital cellulitis with compartment syndrome and vision loss due to streptococcus pyogenes: A case report

Pratima Chavhan<sup>1,\*</sup>, Nirupama Kasturi<sup>1</sup>, Gayathri Panicker<sup>1</sup><sup>1</sup>Dept. of Ophthalmology, Jawaharlal Institute of Postgraduate Medical Education and Research, Puducherry, India

## ARTICLE INFO

## Article history:

Received 22-02-2020

Accepted 06-04-2020

Available online 30-01-2020

## Keywords:

Abscess

Compartment syndrome

Orbital cellulitis

Orbit

Pain

Streptococcus pyogenes

## ABSTRACT

**Purpose:** To describe an unusual case of fulminant orbital cellulitis with complete vision loss despite timely medical and surgical management.

**Observation:** Orbital cellulitis is an infective condition of the ocular adnexal structures (fat, periorbita, and muscles) behind the orbital septum. A 22-year-old female presented with rapidly progressing orbital cellulitis and was started on empirical intravenous antibiotics. Orbital imaging showing marked proptosis with optic nerve stretching and an extraconal abscess in the medial aspect of left orbit. Emergency lateral canthotomy and orbital decompression was done. Streptococcus pyogenes was isolated on culture and antibiotics changed according to the sensitivity pattern. Lid edema, proptosis, and extraocular movements improved but vision deteriorated to absent light perception. Fundus showed disc pallor on follow up. A case of fulminant orbital cellulitis with compartment syndrome and ischemic necrosis of optic nerve is reported, which led to permanent vision loss despite timely antibiotics and surgical management.

**Conclusion:** Despite prompt surgical intervention and administration of intravenous antibiotics, the patient may develop compartment syndrome, ischemic necrosis or infiltration of the optic nerve leading to complete vision loss. Orbital cellulitis is an infective condition of the ocular adnexal structures (fat, periorbita, and muscles) behind the orbital septum. This condition is more common in children and young adults and usually results from a paranasal sinus or any facial infection.<sup>1</sup> The majority of the organisms isolated are Staphylococcus aureus, Streptococcus pneumoniae, Haemophilus influenzae B and Moraxella catarrhalis. Beta-hemolytic streptococci are rarely implicated. Bacterial cellulitis usually responds well to antibiotics but rarely may result in vision or life-threatening complications.

© 2020 Published by Innovative Publication. This is an open access article under the CC BY-NC license (<https://creativecommons.org/licenses/by-nc/4.0/>)

### 1. Case Report

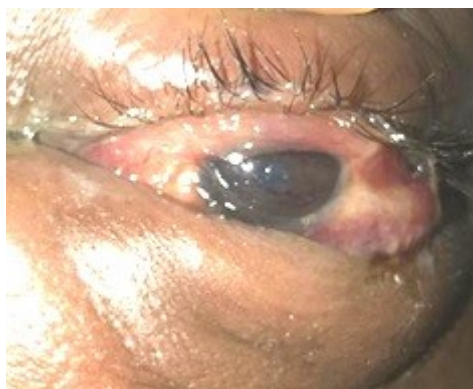A 22-year-old woman hailing from Pondicherry, a housemaid by occupation, without any co-morbidities presented with a history of sudden onset swelling and pain of the left eye (LE) associated with redness and discharge of 2 days duration. On examination, best-corrected visual acuity (BCVA) in the LE was 20/30. The severe lid and periorbital edema, conjunctival congestion, mild temporal chemosis with limitation of the extraocular movement were noted. The patient was admitted as a case of orbital cellulitis and started on empirical broad-spectrum

antibiotics including intravenous vancomycin 1 gram twice a day, ceftriaxone 1 gram twice a day and metronidazole 500 mg thrice a day. An initial diagnostic nasal endoscopy was reported normal. However, within the next 24 hours, the patient rapidly worsened and developed severe chemosis, proptosis, tense lid swelling marked restriction of extraocular movements and grade 3 relative afferent pupillary defects (RAPD). (Figure 1) Vision in the left eye deteriorated to light perception. The emergency computed tomography (CT) scan showed proptosis of 26.38mm, marked stretch of the optic nerve and posterior tenting of the globe (guitar pick sign). (Figure 2 a) Emergency lateral canthotomy and cantholysis of LE was done following which vision improved to finger counting at  $\frac{1}{4}$  meter,

\* Corresponding author.

E-mail address: [pratimachavhan85@gmail.com](mailto:pratimachavhan85@gmail.com) (P. Chavhan).

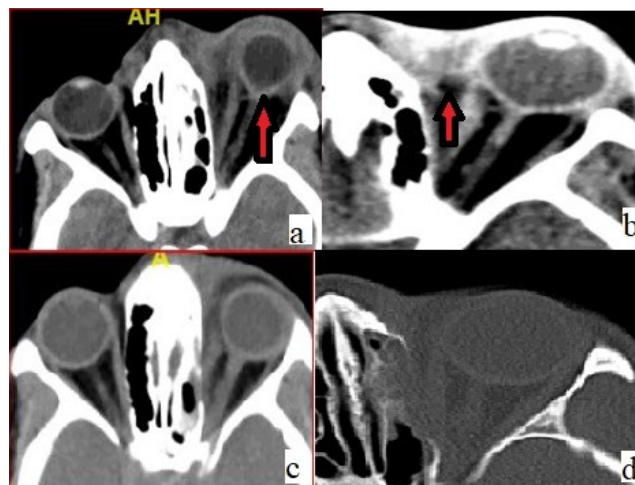
proptosis, and tense lid swelling slightly reduced but RAPD and limitation of extraocular movements remained the same. She also received intravenous corticosteroids to decrease inflammation and optic nerve compression. On 3rd day of presentation, a contrast-enhanced CT showed a possible extraconal abscess anteromedially with medial extraconal fat stranding in the left orbit. (Figure 2 b) On day 5 of presentation, culture reports of conjunctival swab yielded streptococcus pyogenes sensitive to ciprofloxacin, clindamycin, erythromycin, and penicillin. Since there was no significant improvement clinically with 5 days of empirical treatment, antibiotic was changed to intravenous ciprofloxacin. On day 7 of admission, the patient was taken up for left medial orbital decompression with drainage of extraconal abscess (0.5ml). Postoperatively there was marked reduction in proptosis, lid swelling and improvement of extraocular movements, however, grade 3 RAPD remained and vision progressively deteriorated to denying light perception. On follow-up, after 2 weeks the vision persisted to no light perception with grade 3 RAPD, and disc pallor. (Figure 3 a) There was resolution of proptosis and extraocular movements completely improved with residual left exotropia. (Figure 3 b) Repeat imaging showed thickened optic nerve with no evidence of any residual disease at 2 weeks (Figure 2 c) whereas imaging done at 3 months showed normal findings. (Figure 2 d)



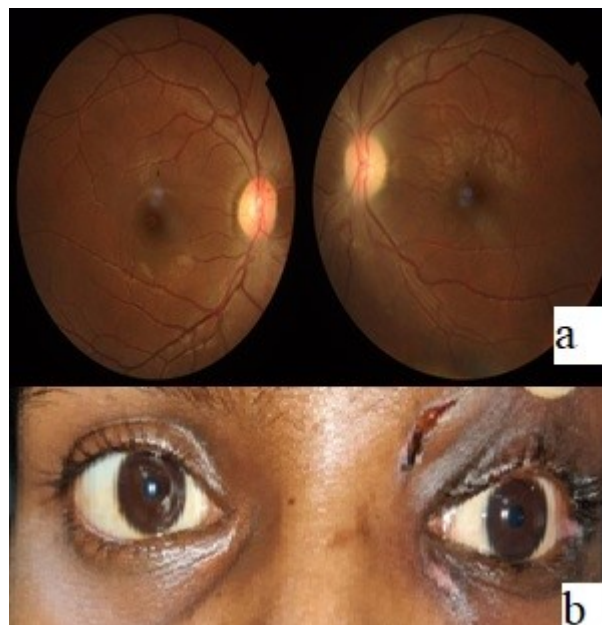
**Fig. 1:** Left eye lid edema, congestion, tense chemosis with proptosis

## 2. Discussion

Orbital cellulitis most frequently present as a complication of sinusitis, dacryocystitis, eyelid or facial injury, dental or ear abscess. Ethmoid and maxillary sinuses are most frequently implicated followed by sphenoid and frontal sinusitis.<sup>2</sup> Incidence is around 1.6/100000 in children and 0.1/100000 in adults.<sup>3</sup> Both pre-septal cellulitis and orbital cellulitis can present similarly as eyelid swelling and pain but key signs that indicate orbital cellulitis are diminution of vision, RAPD, proptosis, pain and



**Fig. 2:** (a): Posterior tenting of the left globe (guitar pick sign) (red arrow) (b): LE extraconal abscess anteromedially with medial extraconal fat stranding (red arrow) (c): Postcanthotomy and cantholysis, CT showing left optic nerve thickening and reduction of proptosis and posterior nerve stretch and posterior globe tenting; (d): CT at 3 months follow up showing normal findings



**Fig. 3:** (a): Left eye mild disc pallor; (b): Clinical picture showing improvement with residual exotropia

absent or reduced ocular movements. CT or MRI scan is the essential tool for diagnosing and following the disease process as it delineates the source and extent of tissue involvement. Chandler et al. classified orbital infections into five groups, namely preseptal cellulitis, orbital cellulitis, subperiosteal abscess, orbital abscess and cavernous sinus thrombosis based on the severity. Vision loss is more common with orbital abscess and mortality with cavernous sinus thrombosis and intracranial spread, especially in the pre-antibiotic era.<sup>4</sup> In a review of 148 cases of orbital cellulitis with proven abscess formation, permanent blindness developed in 7 (15%) cases.<sup>5</sup> Previous studies have suggested multiple factors that are responsible for vision loss in orbital cellulitis including vascular compromise to the retina or optic nerve, compressive optic neuropathy, inflammatory or infiltrative (direct infection) optic neuritis, and even septic vasculitis and that irreversible loss of vision was more likely to be due to vascular cause.<sup>6</sup> A case of fulminant orbital cellulitis with permanent blindness following *Streptococcus pyogenes* infection, despite emergent drainage and intravenous antibiotics there was no improvement in vision, authors suggested ischemic necrosis of a posterior part of the optic nerve as probable cause for unexplained vision loss.<sup>7</sup> Orbital compartment syndrome is a rare, ophthalmic surgical emergency that occurs due to an acute rise in orbital volume within confined orbital spaces which results in sudden increase orbital tension. It may result in acute retinal and optic nerve vascular compromise causing irreversible vision loss. Orbital cellulitis is the most important etiology causing orbital compartment syndrome and lateral canthotomy and cantholysis remain the mainstay of management.<sup>8</sup> Patients with orbital cellulitis are at high risk of developing severe visual loss, and such patients should be monitored very closely and treated promptly with systemic antibiotics and, when indicated, with abscess drainage surgery such as transnasal endoscopic surgery, sinus anastomy, ethmoidectomy, and orbital decompression. Ultrasound-guided fine-needle aspiration and catheter drainage for orbital abscess has also been tried.<sup>9</sup> Few studies have recommended adjunctive intravenous or oral steroids in order to hasten the resolution of inflammation in acute bacterial orbital cellulitis with a low risk of exacerbating infection.<sup>10</sup> Prompt diagnosis and appropriate management are imperative to prevent vision-threatening complications.

### 3. Conclusion

Ophthalmologists need to monitor the patient closely for any signs that the infection is worsening or not responding

to the antibiotics. Despite prompt surgical intervention and administration of intravenous antibiotics, the patient may develop compartment syndrome, ischemic necrosis or infiltration of the optic nerve leading to complete vision loss.

### 4. Source of Funding

None

### 5. Conflict of Interest

None.

### References

1. Chaudhry IA, Shamsi FA, Elzaridi E, Al-Rashed W, Al-Amri A, Al-Anezi F. Outcome of Treated Orbital Cellulitis in a Tertiary Eye Care Center in the Middle East. *Ophthalmol.* 2007;114(2):345-54.
2. Hoxworth JM, Glastonbury CM. Orbital and Intracranial Complications of Acute Sinusitis. *Neuroimag Clin N Am.* 2010;20(4):511-26.
3. Orbital cellulitis, uptodate. Available from: <http://www.uptodate.com>.
4. Chandler JR, Langenbrunner DJ, Stevens ER. The pathogenesis of orbital complications in acute sinusitis. *Laryngosc.* 1970;80(9):1414-28.
5. Hornblase A, Herschorn BJ, Stern K, Grimes C. Orbital abscess. *Surv Ophthalmol.* 1984;29(3):169-78.
6. Slavin ML, Glaser JS. Acute Severe Irreversible Visual Loss With Sphenoethmoiditis-'Posterior' Orbital Cellulitis. *Arch Ophthalmol.* 1987;105(3):345-8.
7. Connell B, Kamal Z, McNab AA. Fulminant orbital cellulitis with complete loss of vision. *Clin Exp Ophthalmol.* 2001;29(4):260-1.
8. Lima V, Burt B, Leibovitch I, Prabhakaran V, Goldberg RA, Selva D. Orbital Compartment Syndrome: The Ophthalmic Surgical Emergency. *Surv Ophthalmol.* 2009;54(4):441-9.
9. Wang Y, Zhang J, Dong L, Jiang H, Song X. Orbital abscess treated by ultrasound-guided fine needle aspiration and catheter drainage: A case report. *Med (Baltimore).* 2019;98(39):17365.
10. Chen L, Silverman N, Wu A, Shinder R. Intravenous Steroids with Antibiotics on Admission for Children with Orbital Cellulitis. *Ophthalmic Plast Reconstr Surg.* 2018;34(3):205-8.

### Author biography

**Pratima Chavhan** Senior Resident

**Nirupama Kasturi** Associate Professor

**Gayathri Panicker** Junior Resident

**Cite this article:** Chavhan P, Kasturi N, Panicker G. Fulminant orbital cellulitis with compartment syndrome and vision loss due to streptococcus pyogenes: A case report. *Indian J Clin Exp Ophthalmol* 2020;6(3):467-469.