



## Original Research Article

# A comparative study of graft stability, complication profiles and patient comfort among sutureless glue-free and sutured conjunctivo limbal autograft in pterygium surgery of Western Rajasthan

Tek Chand<sup>1,\*</sup>, Arvind Chauhan<sup>1</sup>, Sarika Gaur<sup>1</sup>

<sup>1</sup>Dept. of Ophthalmology, Dr. S. N. Medical College, Jodhpur, Rajasthan, India



## ARTICLE INFO

## Article history:

Received 06-03-2020

Accepted 07-04-2020

Available online 30-09-2020

## Keywords:

Graft stability

Pterygium

Sutured conjunctival autograft

Sutureless glue-free autograft

## ABSTRACT

**Background:** Pterygium is a triangular encroachment of bulbar conjunctiva on to the cornea known for high recurrence rate. Various adjunctive measures were used to reduce the recurrence rate. Nowadays though sutureless and glue-free conjunctival autograft has been encouraged for treating primary pterygium yet sutured conjunctival autograft is also extensively performed.

**Objectives:** To assess and compare graft stability, complication profiles and patient comfort in sutureless glue-free and sutured conjunctivo limbal autograft in pterygium surgery and to assess postoperative improvement in parameters associated with visual defects due to pterygium.

**Materials and Methods:** Sutured conjunctival autograft were done in 25 patients (group A), and sutureless and glue-free conjunctival autograft was done in 25 patients (group B). Postoperative discomfort was assessed for 90 days during which graft related complications and recurrence if any were noted. Pre and postoperative parameters associated with visual defects due to pterygium were also compared.

**Results:** Total number of patients who developed postoperative complications was 22(88%) in Group A and 15(60%) patients in Group B. Number of patients with postoperative discomfort was significantly less in group B after 1 week and almost nil on 30<sup>th</sup> day. In Group A one patient graft instability and in Group B two patients showed graft instability.

**Conclusion:** Sutureless glue free auto conjunctivo limbal stem cell transplantation showed significantly better patients comfort and decreases suture related complications.

© 2020 Published by Innovative Publication. This is an open access article under the CC BY-NC license (<https://creativecommons.org/licenses/by-nc/4.0/>)

## 1. Introduction

Pterygium (greek pterygos- a wing) is a triangular fibrovascular subepithelial ingrowth of bulbar conjunctival tissue over limbus onto cornea. There is hyalinization and elastotic degeneration of subconjunctival tissue which invades cornea and destroys superficial stroma and Bowman's membrane.<sup>1</sup>

The disease is more prevalent in countries nearer to equator, persons living in hot and sunny climate, those who do not wear sunglasses, farmers etc. and in patients with chronic inflammation and pingecula.<sup>2</sup> Deficiency of the stem cells is considered as one of the reasons for pterygium

in various studies.<sup>3</sup> It is two times more common in men than women with highest incidence amongst 20-40 years age group.<sup>4</sup> A small pterygium, not involving the visual axis can be subjected to medical treatment involving tear substitutes, lubricants and short course of topical steroids. Sunglasses can protect from dust, hot wind and sunlight.<sup>5</sup>

Progressive pterygium can cause decrease in visual acuity, astigmatism, increased glare and rarely cause diplopia. Intermittent episodes of inflammation cause irritation, watering and foreign body sensation.<sup>6</sup> Surgical treatment is reserved for such cases seen in spite of medical treatment and those with cosmetic complaints. Pterygium can be incised, removed, excised, transplanted, cauterized, diathermised or irradiated.<sup>7</sup> Major limitation of pterygium

\* Corresponding author.

E-mail address: [drtechahal@yahoo.com](mailto:drtechahal@yahoo.com) (T. Chand).

surgery is high recurrence rate and various adjuncts to surgery such as use of ionizing radiation ( $\beta$ -rays), heat (thermal cautery), laser (excimer laser, argon laser) and antiproliferative agents like mitomycin C, 5 fluorouracil, daunorubicin on bare sclera have been advocated to reduce recurrence significantly. Antiproliferative agents can produce potentially serious complications like delayed healing, scleral melting and necrosis.<sup>8</sup> In 1977 Thoft, first time described the use of conjunctiva for damaged ocular surface.<sup>9</sup> The conjunctival autograft can be attached at the site of conjunctival defect (created by pterygium excision) by using 'sutures' or 'fibrin glue' or sutureless and glue free.<sup>10</sup>

Autograft fixation done by suturing takes longer time and there are chances of abscesses, buttonholes and granuloma formation. Tissue adhesives may be used instead of suturing but cost and risk of anaphylactic reaction, PRION mediated disease, risk of transmitted infections (HBV, HCV, HIV) are the major concerns with the commercial fibrin glue. Sutureless and glue-free conjunctival autograft has shown beneficence by Malik et al.<sup>10</sup>

A generalized consensus has been reached upon pterygium excision with autologous limbal stem cell transplantation as the best procedure in preventing recurrence with minimal complications.<sup>11,12</sup> Hence with this background present study was planned to compare graft stability, postoperative complication profiles and patient comfort between sutureless glue-free and sutured conjunctivo limbal autograft in pterygium surgery and to assess postoperative improvement in parameters associated with visual defects due to pterygium.

## 2. Materials and Methods

This study was conducted in the department of Ophthalmology, MDM Hospital associated with Dr. S.N. Medical College Jodhpur during the period of September 2019 to January 2020 after approval from the Institutional Ethics Committee. Fifty patients of age above 18 years having primary pterygium with encroachment over cornea  $>2.1$ mm were included in the study after obtaining an informed consent. Patients with recurrent pterygium, pseudo-ptyerygium, conjunctival malignancy, inflammation in anterior and posterior segment, ocular surface disorders, old atrophic pterygium, bleeding disorder, uncontrolled, hypertension and diabetes mellitus, connective tissue disorder were excluded from the study.

Preoperative ophthalmic evaluation comprised of detailed ocular and systemic history, a thorough ocular examination done by Slit lamp biomicroscopy, visual acuity by Snellen's chart, refraction, keratometry, ocular movements, direct ophthalmoscopy for examining the posterior segment and Fluorescein staining.

Patients were divided into two groups of 25 cases in each group: Group A comprising of cases with

sutured conjunctivo-limbal autograft transplantation and Group B with sutureless glue-free conjunctivo-limbal autograft transplantation in pterygium surgery by standard procedures<sup>13</sup>. All patients were called on the next day of surgery for postoperative examination i.e. on day 1 and subsequent examinations were done on days 7<sup>th</sup>, 14<sup>th</sup>, 30<sup>th</sup>, 60<sup>th</sup> and 90<sup>th</sup>. Various parameters were recorded on every follow up.

The parameters studied during each visit were: any complaint such as pain, foreign body sensation, lacrimation, photophobia, blepharospasm, etc.; Visual acuity with snellen's test both unaided and aided, slit lamp examination for lids: swelling, conjunctiva for congestion, subconjunctival haemorrhage or chemosis, conjunctival cyst, granuloma; cornea for corneal oedema, corneal thinning or corneal opacity; iris for any signs of iritis and recurrence if present. Particular care was taken to note the time of recurrence. Also, note was taken to see whether the recurrent growth involved the cornea or not. Ocular movements, Fluorescein staining, Keratometry and examination of Posterior segment was also done.

The observations were recorded in number/percentage or mean  $\pm$  SD and statistical analysis was done by applying chi square and t-test.

## 3. Results

In this study total number of females was 28 (56%); 16 in Group A and 12 in Group B. Males were 22 (44%) in number of which 9 were in Group A and 13 in Group B. Mean age of the total patients in Group A was  $42.08 \pm 8.28$  years where as it was  $38 \pm 8.59$  years in Group B (Table 1).

In the present study 11 (44%) patients in Group A and 10 (40%) patients in Group B were house wives and by occupation 5 (20%) patients Group A and 4 (16%) patients in Group B were farmer, 3 patients in both the group were labours (12%). Rest of the patients belonged to other occupational groups like teachers, businessman, government servant etc. History of exposure to sunlight was present in 42 (84%) patients; 21 (84%) in each group while it was absent in remaining 4 (16%) patients in both the groups (Table 1).

20 patients were having progressive pterygium in Group A while in Group B 19 cases had stationary pterygium in the present study. The mean size of pterygium in this study was  $2.77 \pm 0.54$  mm in Group A and  $2.63 \pm 0.45$  mm in Group B (Table 1).

In this study, on day 1, almost all patients were complaining of ocular pain, foreign body sensation, itching, mucus discharge, photophobia. Subconjunctival haemorrhage and Lacrimation was more in Group A as compared to Group B. Severity remained more in group A after this period. On 14<sup>th</sup> day, group B patients had symptoms of mild grade but in group A more number of patients were complaining of discomfort. On 30<sup>th</sup> day in

group B complains were nil but in group A all patients had discomfort but of mild grade only. On 60<sup>th</sup> day, group B patients had no complains but in group A still 20 patients were complaining of grade 1 foreign body sensation and 15 of itching (Table 2).

In this study up to 90<sup>th</sup> day follow up period, as postoperative complication other than patient's ocular discomfort; in Group-A, 20 patients had lacrimation, 5 patients showed subconjunctival haemorrhage, 1 patient developed granuloma and graft instability, 1 patient developed recurrence and 3 patients were with no other complications except ocular discomfort. In Group-B 11 patients had lacrimation, 2 patients showed subconjunctival haemorrhage, 2 patients showed graft instability, 1 patient developed recurrence and 10 patients were with no other complications except ocular discomfort. Total number of patients who developed complications was 22(88%) in Group A and 15(60%) patients in Group B and it was found to be significant with p value < 0.05. (Figure 1)

Keratometry reading was noted along the flattest meridian (0°) and steepest meridian (90°). Postoperative mean Keratometry readings of Group A was compared with that of Group B along both the meridians and were found to be significant with p value <0.05 (Table 3).

In present study 14 patients in Group A and 23 patients in Group B had preoperative visual acuity in range of 6/6 - 6/12, 8 patients in Group A and 2 patients in Group B had in the range of 6/18 to 6/24 and 3 patients in Group A had between 6/36 to 6/60. Postoperatively 17 patients in Group A and 24 patients in Group B had visual acuity in range of 6/6 - 6/12, 5 patients in Group A and 1 patient in Group B had between 6/18 to 6/24 and 3 patients in Group A had from 6/36 to 6/60. Postoperatively, total 4 patients (3 in Group A and 1 in Group B) of 6/18-6/24 range improved by 1 line on Snellen's chart (Table 3).

#### 4. Discussion

Pterygium is a triangular encroachment of bulbar conjunctiva on to the cornea known for high recurrence rate. Pterygium has been incised, removed, split, excised, transplanted, cauterized, grafted, inverted, dissected, heated, rotated, coagulated, and irradiated without much success. Various adjunctive measures were used to reduce the recurrence rate i.e. Triethylene thiophosphoramidate, beta radiation, argon laser, excimer laser, mitomycin-C, Conjunctival autograft and stem cell transplantation.<sup>8</sup>

In recent years, pterygium excision with limbal stem cell autograft has become standard procedure as it is associated with least recurrence rate<sup>11,12</sup> and in suture-less and glue-free pterygium surgery patients are free from all problems associated with usage of sutures or fibrin glue.

In this study total number of females was more and other studies have reported male predominance.<sup>9</sup> This study was hospital based study with small sample size and patients

were randomly selected. Number of females could also be more because of cosmetic purpose. Maximum number of female patients was housewife from rural background, who had more exposure to sun light which is a causative factor for pterygium. Relationship of pterygium to sunlight was also taken into account in present study and it was found that patients had higher degree of exposure to sunlight. This observation is consistent with that of Malik et al.<sup>10</sup>

During the follow up period patients were having ocular discomfort. Subconjunctival haemorrhage and Lacrimation was also observed. Discomforts like pain and itching are expected speculations after any surgery initially but postoperative discomfort was less in group B after 1 week and almost nil on 30<sup>th</sup> day. Other studies have also shown lesser postoperative complication after this surgery.<sup>3,13</sup>

After the follow up period of 90 day number of graft retraction, granuloma formation, absence of graft and recurrence was very few. Moreover serious complication like glaucoma, corneal edema, perforation, symblepheron, rapid development of cataract did not occur in any case. Number of postoperative complications other than patient ocular discomfort were more in Group A as compared to Group B which were similar to other study.<sup>3,14</sup> The reason for the above findings could be in sutureless glue free technique lids lie in apposition to the bulbar conjunctiva hence allowing faster healing by forming a protective covering. Also tension over the graft surface spreads evenly without direct tension on its edges.<sup>13</sup>

Recurrence was found in one patient in each group. Lesser recurrence in both the groups is probably because limbal stem cells provide a barrier between conjunctival cells and cornea.<sup>10</sup> According to Gimeno et al. the recurrence rates differs depending on individual technique and surgical experience and suggested that cases should be followed for duration of one year.<sup>15</sup>

Significant change in postoperative keratometry reading along both the meridian was observed between both the groups. Pterygium causes maximum astigmatism along vertical meridian, i.e. with the rule astigmatism and the other is that there is significant change in Keratometry along the vertical meridian and astigmatism after surgery. These findings correlate with other studies which state that once pterygium reaches a critical size, they induce visually significant central with the rule astigmatic change that may not be apparent on subjective refraction.<sup>16</sup> This finding helps to identify those patients who may benefit from surgical intervention. A successful pterygium surgery reduces the pterygium induced refractive astigmatism and improves the visual acuity.<sup>13</sup>

In present study visual acuity improved which was in concert with study by Maheshwari who found significant difference between pre operative and post operative visual acuity.<sup>17</sup> The increase in visual acuity in patients was due to change in corneal astigmatism. Number of patient was

**Table 1:** Characteristics of the patients in both the groups

		Group A (N=25)	Group B (N=25)
Male/ Female ratio (No. of patients)		9/16	13/12
Mean age (years) (Mean±SD)		42.08±8.25	38±8.59
Size of pterygium (mm) (Mean±SD)		2.71±0.54	2.63±0.45
Eye operated (Left/Right) (No. of patients)		15/10	12/13
Type of pterygium (Progressive/Stable) (No. of patients)		20/5	19/6
Exposure to sunlight No. of patients(percentage)		21(84%)	21(84%)
Occupation No. of patients(percentage)	Housewife	11(44%)	10(40%)
	Farmer	5(20%)	4(16%)
	Labour	3(12%)	3(12%)
	Others	6(24%)	8(32%)

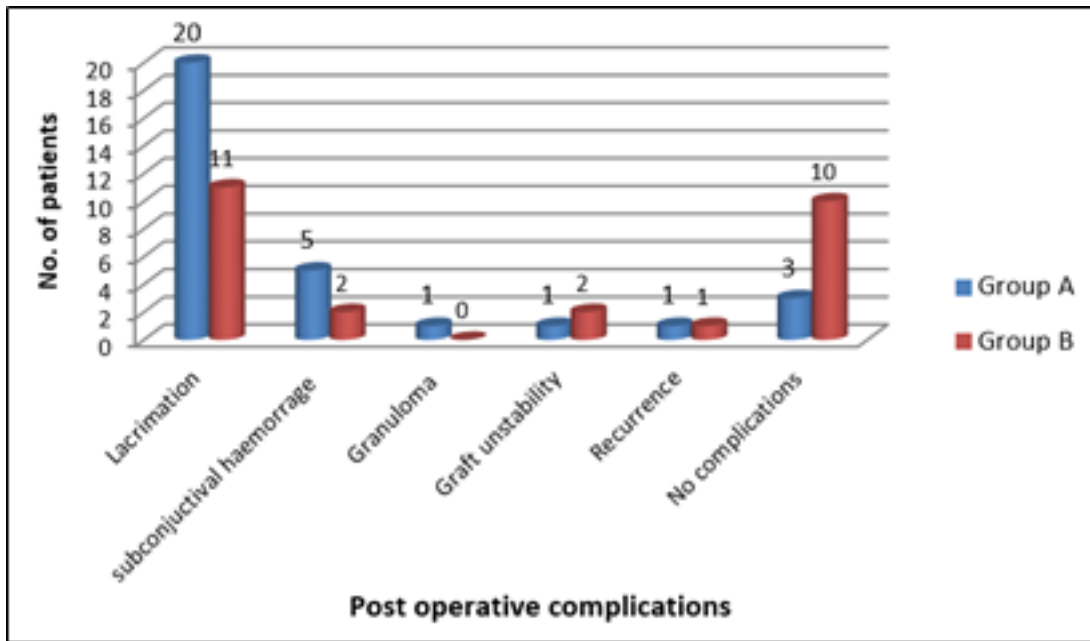
**Table 2:** Comparison of post operative complications on Day 1, 7, 14, 30, 60 and 90 in both the groups

Complications	Day 1		Day 7		Day 14		Day 30		Day 60		Day 90	
	A	B	A	B	A	B	A	B	A	B	A	B
Foreign body sensation No. (Grade)	25(3)	25(3)	25(3)	25(2)	25(2)	25(1)	24(1) 1 (2)	0	20(1)	0	-	-
Itching No. (Grade)	25(3)	24(2) 1 (1)	25(3)	25(1)	25(2)	0	25(1)	0	15(1)	0	-	-
Mucus discharge No. (Grade)	25(3)	25(2)	23(2) 2 (3)	25 (1)	24(2) 1(1)	0	25(1)	0	0	0	-	-
Photophobia No. (Grade)	25(3)	24(3) 1 (2)	25(2)	24(2) 1 (1)	24(2) 1(1)	1(1)	25(1)	0	0	0	-	-
Hyperemia No. (Grade)	24(3) 1(2)	24(3) 1 (2)	25(2)	24(1) 1 (2)	24(1) 1(2)	1(1)	25(1)	0	0	0	-	-
Punctate keratitis No. (Grade)	25(1)	25(1)	0	0	0	0	0	0	0	0	-	-
Subconjunctival haemorrhage	5	2	5	2	2	0						
Lacrimation	20	11	11	2	4	0	2	0	0	0	-	-
Graft retraction			0	1	1	0						
Graft lost/absent			0	1	1	1						
Granuloma					1							
Recurrence									1	1		
Graft instability											1	2

**Table 3:** Keratometry value, visual acuity and corneal astigmatism in both the groups

		Pre operative		Post operative		P value
		Group A	Group B	Group A	Group B	
Keratometry (Mean±SD in Diopters)	At 0°	44.12±1.18	42.96±1.05	44.13±1.18	43.02±1.06	<0.05*
	At 90°	45.37±1.27	42.96±1.05	44.77±1.14	43.57±57	<0.05*
Astigmatism (Mean±SD in Diopters)		1.21±0.91	1.13±1.00	0.64±1.36	0.55±0.91	<0.05*
Visual acuity (no. of patients)	6/6-6/12	14	23	17	24	
	6/18-6/24	8	2	5	1	
	6/36-6/60	3	0	3	0	

\* significant post operative p value between group A and B



**Fig. 1:** Comparison of post operative complications other than ocular discomfort between the two groups

more in Group A which could be explained on the basis that already visual acuity was of the range of 6/6 to 6/12 in 23 patients in Group B.

Limitations of this study were small sample size and no analysis for bigger pterygium graft as size of pterygium included were smaller. Moreover the follow up period was 90 days which was a limitation for observing recurrences in long term.

## 5. Conclusion

This study concludes sutureless glue free auto conjunctivo limbal stem cell transplantation provide better patients comfort and decreases suture related complications and with lesser recurrence.

## 6. Source of Funding

None.

## 7. Conflict of Interest

None.

## References

- Ginger-Eke HA, Ogbonnaya CE, Ezisi CN. PTERYGIUM: Recent trends and perspectives—A review of pathogenesis and current management options. *Niger J Ophthalmol.* 2018;26(2):89–98.
- Arenas E, Armas G, Ramirez A. Pinguecula. *Pan Am J Ophthalmol.* 2019;1(1):9.
- Damle V. A Study to Compare Conjunctival Autografting with Sutures and Glue-free Sutureless Technique after Primary Pterygium Excision. *Int J Sci Stud.* 2017;5(9):142–7.
- Hashemi H, Khabazkhoob M, Yekta A, Jafarzadehpour E, Ostadimoghaddam H, Kangari H. The prevalence and determinants of pterygium in rural areas. *J Curr Ophthalmol.* 2017;29(3):194–8.
- Mohammed I. Treatment of pterygium. *Ann Afr Med.* 2011;10:197–203.
- Chourasia P, Mehta AD, Kumar P. Comparison of astigmatism before and after pterygium surgery. *Int J Health Sci Res.* 2014;4(3):97–102.
- Massaoutis P, Khemka S, Ayliffe W. Clinical outcome study of a modified surgical technique for pterygium excision. *Can J Ophthalmol.* 2006;41(6):704–8.
- Fakhry M. The use of mitomycin C with autologous limbal-conjunctival autograft transplantation for management of recurrent pterygium. *Clin Ophthalmol.* 2011;5:123.
- Thoft RA. Conjunctival Transplantation. *Arch Ophthalmol.* 1977;95(8):1425–7.
- Malik KPS, Goel R, Gupta A, Gupta SK, Kamal S, Malik VK, et al. Efficacy of sutureless and glue free limbal conjunctival autograft for primary pterygium surgery. *Nepalese J Ophthalmol.* 2012;4(2):230–5.
- Fayez MA. Limbal versus conjunctival autograft transplantation for advanced and recurrent pterygium. *Ophthalmol.* 2002;109(9):1752–5.
- Hirst LW. Recurrent Pterygium Surgery Using Pterygium Extended Removal Followed by Extended Conjunctival Transplant: Recurrence Rate and Cosmesis. *Ophthalmol.* 2009;116(7):1278–86.
- Sharma A, Raj H, Gupta A, Raina AV. Sutureless and Glue-free Versus Sutures for Limbal Conjunctival Autografting in Primary Pterygium Surgery: A Prospective Comparative Study. *J Clin Diagn Res.* 2015;9:6–9.
- Elwan SAM. Comparison between sutureless and glue free versus sutured limbal conjunctival autograft in primary pterygium surgery. *Saudi J Ophthalmol.* 2014;28(4):292–8.
- Torres-Gimeno A, Martínez-Costa L, Ayala G. Preoperative factors influencing success in pterygium surgery. *BMC Ophthalmol.* 2012;12(1):38.
- Mohammad-Salih PAK, Sharif AFMD. Analysis of Pterygium Size and Induced Corneal Astigmatism. *Cornea.* 2008;27(4):434–8.
- Maheshwari S. Effect of pterygium excision on pterygium induced astigmatism. *Indian J Ophthalmol.* 2003;51(2):187–8.

**Author biography**

**Tek Chand** Senior Resident

**Arvind Chauhan** Senior Professor and Head

**Sarika Gaur** Associate Professor

**Cite this article:** Chand T, Chauhan A, Gaur S. A comparative study of graft stability, complication profiles and patient comfort among sutureless glue-free and sutured conjunctivo limbal autograft in pterygium surgery of Western Rajasthan. *Indian J Clin Exp Ophthalmol* 2020;6(3):457-462.