



Case Report

Bilateral lacrimal gland enlargement in a patient with thyroid orbitopathy

Nagalakshmi Narayana-swamy^{1,*}, Alhaj Farhath Tasneem¹

¹Dept. of Ophthalmology, Vydehi Institute of Medical Sciences and Research Centre, Bangalore, Karnataka, India



ARTICLE INFO

Article history:

Received 18-11-2019

Accepted 11-12-2019

Available online 17-03-2020

Keywords:

Lacrimal Gland

Orbit

Thyroid Orbitopathy

ABSTRACT

Purpose: Thyroid Orbitopathy is a condition associated with thyroid dysfunction. In addition to exophthalmos, eyelid retraction, eyelid oedema, restrictive extra-ocular myopathy, lacrimal gland enlargement can also be observed in these patients. However thyroid orbitopathy is not usually been considered in the differential diagnosis of cases of isolated lacrimal gland enlargement.

Materials and Methods: An elderly male patient at our institution presented with bilateral lacrimal gland enlargement as the clinical or radiologic sign and was later diagnosed as thyroid orbitopathy. Computerized tomography and/or magnetic resonance imaging of the orbits were obtained and demonstrated isolated lacrimal gland enlargement with enlargement of lateral rectus and inferior rectus.

Result: A case of bilateral lacrimal gland enlargement found in a patient with thyroid orbitopathy was noted. Patient was investigated and kept on follow up.

Conclusion: This case represents, enlargement of lacrimal gland as a presenting sign of thyroid orbitopathy. Further clinical and radiological studies are essential for a better understanding of the timing of lacrimal gland involvement. In such patients presenting with lacrimal gland enlargement, thyroid orbitopathy should be strongly considered in the differential diagnosis in addition to causes such as dacryoadenitis and neoplasms.

© 2020 Published by Innovative Publication. This is an open access article under the CC BY-NC-ND license (<https://creativecommons.org/licenses/by/4.0/>)

1. Introduction

Thyroid Orbitopathy is the most common cause of proptosis and orbital inflammation in adults. Thyroid orbitopathy is characterized by inflammation, congestion, hypertrophy, fat and orbital muscles fibrosis leading to increase in volume of the muscles.¹

The signs and symptoms present within one year of the onset of the disease and extra-ocular muscles are involved as an immunological phenomenon and present with increase in volume.² Characteristic ocular signs include exophthalmos, eyelid retraction, eyelid oedema, restrictive extra-ocular myopathy, and optic neuropathy associated with thyroid dysfunction.

The lacrimal gland can be affected in thyroid orbitopathy, though not commonly considered as a primary sign.³⁻⁵ We

present a case of thyroid orbitopathy where bilateral lacrimal gland enlargement detected on imaging studies was the predominate clinical sign in addition to other features of lacrimal gland enlargement.

2. Case Report

A 65-year-old male presented with complaints of swelling and protrusion of left eye (Figures 1 and 2) since 4 years. Patient has been treated in an institution outside with oral steroids and found no remission. He was a known case of hypertension on treatment and no other comorbidities. On examination visual acuity in right eye was 6/36 and 6/18 in left eye with normal near vision. Colour vision was normal in both eyes.

External exam showed upper eyelid fullness of right eye more than left eye and left side proptosis of 4 millimetre. Motility testing demonstrated a mild elevation deficit of the right eye and a 3 prism dioptre left Hypotropia. There was

* Corresponding author.

E-mail address: anushkanarayan5@gmail.com (N. Narayana-swamy).

sub-conjunctival fat prolapse was left side noted. (Figure 3)

Rest of the anterior segment was normal. Fundus showed normal optic disc with some drusens at the macula. Her examination was consistent with a clinical diagnosis of thyroid orbitopathy.

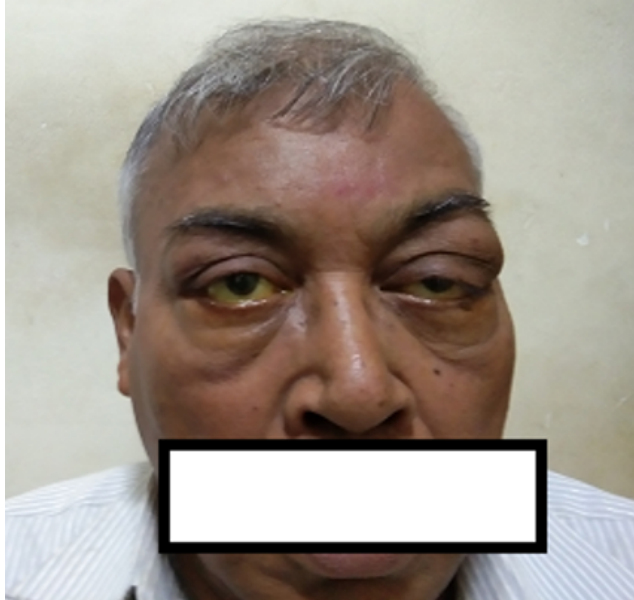

Fig. 1: Patient's image showing proptosis and fullness of lids more evident on left side

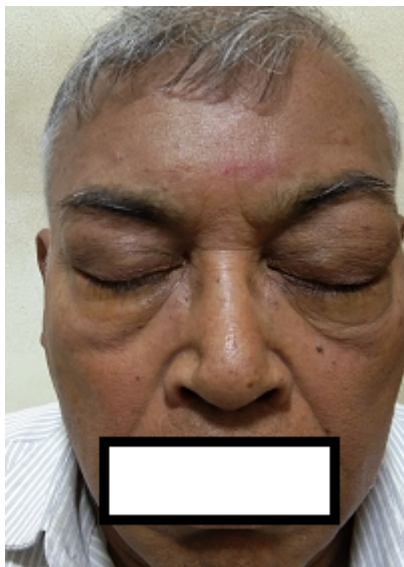

Fig. 2: Patient's image showing proptosis and fullness of lids more evident on left side

Tear film tests were abnormal.

1. Tear break up time: 3 seconds
2. Schirmer's test I: 8mm

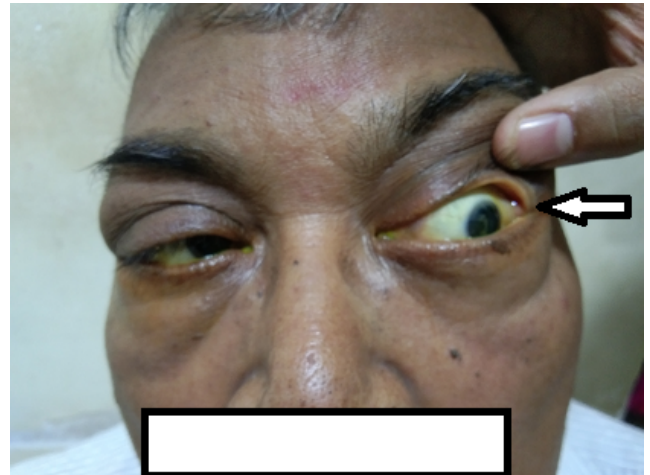

Fig. 3: Patient's image showing prolapse of fat tissue noted

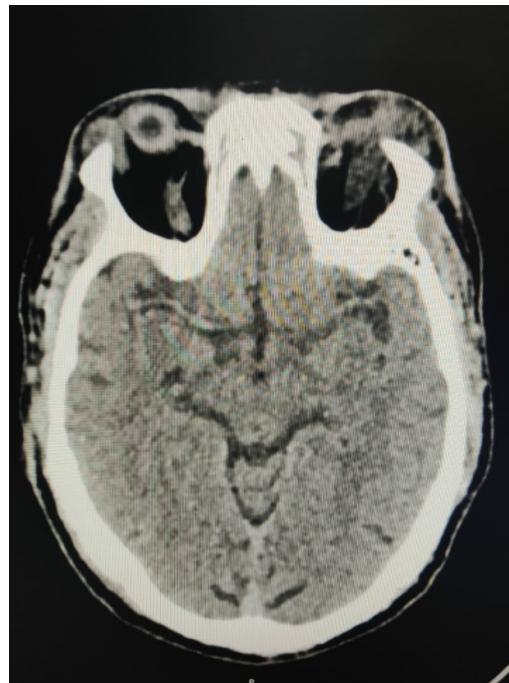


Fig. 4: Computerised tomography image showing proptosis on left side more than right side

3. Schirmer's test II: 8-9mm
4. Rose Bengal Stain: Mild staining noted

BELL'S Phenomenon: Normal in both eyes

Cogan's twitch test: Negative

Ice pack test: Negative

Laboratory testing including erythrocyte sedimentation rate was 38mm/hour and antinuclear antibodies were negative. However, Thyroid stimulating hormone level was low and free t3 and t4 were elevated. Computerised tomography showed proptosis more evident on left side

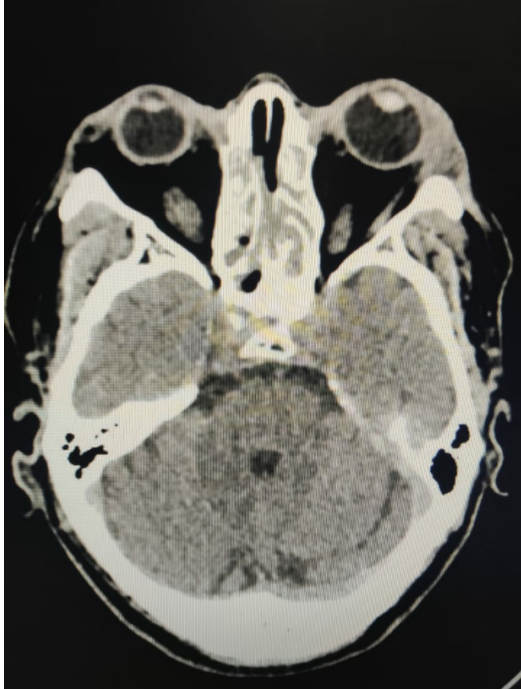


Fig. 5: Computerised tomography image showing proptosis, lacrimal gland enlargement and extraocular muscle enlargement more evident on left side

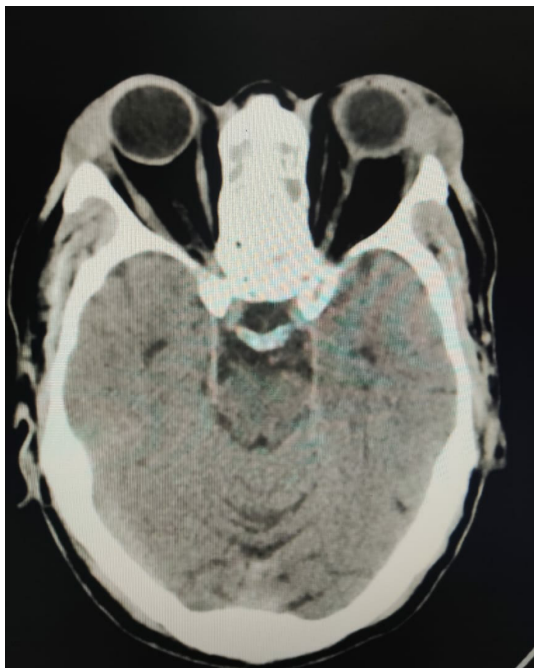


Fig. 6: Computerised tomography image showing extraocular muscle enlargement

(Figure 4), lacrimal gland enlargement (Figure 5) and extraocular muscle enlargement (Figure 6)

This further supported the diagnosis of Thyroid orbitopathy. The patient subsequently developed a progressive restrictive myopathy of the right inferior rectus muscle and right eyelid retraction.

3. Discussion

Thyroid orbitopathy is primarily a clinical diagnosis. When the characteristic ocular signs coincide with a dysthyroid state, the diagnosis can be made without further workup or imaging studies. As in our study the patient had lacrimal gland enlargement and on further investigations enlargement of extra-ocular muscles and thyroid dysfunction was noted.

Lacrimal gland involvement is generally not included in the discussion of thyroid ophthalmopathy; In addition to the involvement of extra-ocular muscles it is, the only tissue in the orbit consistently involved in thyroid dysfunction is the lacrimal gland involvement.^{6,7}

Also Huang noted that the lacrimal gland was enlarged in Thyroid orbitopathy patients as compared to patients without thyroid dysfunction and the lacrimal gland⁵ was even larger in patients with increased inflammatory cytokines in tears.

Imaging methods (CT and MRI) play a vital role as an aid in the evaluation of patients with thyroid ophthalmopathy, especially in demonstration of involvement of orbital structures in different stages of the disease and also aid in follow-up.

We present a case of bilateral lacrimal gland enlargement in a patient with thyroid dysfunction. Further clinical and radiological studies looking at the natural history of thyroid orbitopathy would be useful to better understand the frequency and timing of lacrimal gland involvement.

4. Source of Funding

None.

5. Conflict of Interest

None.

References

1. Cakirer S, Cakirer D, Basak M, Durmaz S, Altuntas Y, Yigit U. Evaluation of Extraocular Muscles in the Edematous Phase of Graves Ophthalmopathy on Contrast-Enhanced Fat-Suppressed Magnetic Resonance Imaging. *J Computer Assist Tomography*. 2004;28(1):80–86.
2. Kahaly GJ. Recent developments in Graves' ophthalmopathy imaging. *J Endocrinol Invest*. 2001;27:254–258.
3. Bingham CM, Harris MA, Realini T, Nguyen J, Hogg JP, Sivak-Callcott JA. Calculated Computed Tomography Volumes of Lacrimal Glands and Comparison to Clinical Findings in Patients With Thyroid Eye Disease. *Ophthalm Plast Reconstr Surg*. 2014;30(2):116–118.
4. Harris MA, Realini T, Hogg JP, Sivak-Callcott JA. CT Dimensions of the Lacrimal Gland in Graves Orbitopathy. *Ophthalmic Plast Reconstr Surg*. 2012;28(1):69–72.
5. Huang D, Luo Q, Yang H, Mao Y. Changes of lacrimal gland and tear inflammatory cytokines in thyroid associated ophthalmopathy. *Invest Ophthalmol Vis Sci*. 2014;55(8):4935–4943.
6. Trokel SL, Jakobiec FA. Correlation of CT Scanning and Pathologic Features of Ophthalmic Graves' Disease. *Ophthalmol*. 1981;88(6):553–564.
7. Ueno H, Ariji E, Izumi M, Uetani M, Hayashi K, Nakamura T. MR imaging of the lacrimal gland. Age-related and gender dependent changes in size and structure. *Acta Radiol*. 1996;37:714–719.

Author biography

Nagalakshmi Narayana-swamy PG Resident

Alhaj Farhath Tasneem Professor

Cite this article: Narayana-swamy N, Tasneem AF. **Bilateral lacrimal gland enlargement in a patient with thyroid orbitopathy.** *Indian J Clin Exp Ophthalmol* 2020;6(1):151-154.