



Case Report

Vitiligo Iridis: A case report

Pragati Garg^{1,*}, Aditi Gupta¹, Priyanka Raj¹

¹Dept. of Ophthalmology, Era's Lucknow Medical College and Hospital, Lucknow, Uttar Pradesh, India



ARTICLE INFO

Article history:

Received 20-12-2019

Accepted 07-01-2020

Available online 17-03-2020

Keywords:

Iris

Small pox

Vitiligo iridis

Variola

ABSTRACT

Aim: To report an unusual case of vitiligo iridis.

Case Report: We examined a 55 year old woman attending our OPD with diminution of vision. Upon examination, we found multiple greyish-white circular spots on the anterior surface of the iris with punched out margins in the left eye. She also had a history of small pox in the past.

Vitiligo iridis is a rare sequelae of Variola (small pox) infection. There are a few causes like surgical trauma, chronic iridocyclitis, chronic glaucoma, etc., which can cause iris atrophic patches but Variola infection is the most common cause of vitiligo iridis presenting with focal areas of iris atrophy.

Conclusion: Even though the small pox has been eradicated, the patients of the elderly age group might present with the incidental findings of vitiligo iridis, which may or may not be associated with elevated intraocular pressure. Vitiligo iridis can present as a complication of a number of conditions. Hence, finding out the probable cause becomes of great importance to help prevent misdiagnosis as an unrelated cause of focal or multifocal iris atrophy. This can in turn help further management of the underlying cause.

© 2020 Published by Innovative Publication. This is an open access article under the CC BY-NC-ND license (<https://creativecommons.org/licenses/by/4.0/>)

1. Introduction

Vitiligo iridis is a condition characterized by focal areas of iris atrophy secondary to some ocular disease. These atrophic areas on iris appear hypopigmented, hence the name vitiligo iridis. This report highlights a peculiar case of vitiligo iridis which presented with areas of rounded white spots on the anterior surface of iris. It is one of the rare sequelae of small pox infection and thus makes this case an interesting study subject.

2. Case History

A 55-year-old woman reported in ophthalmology OPD with diminution of vision without any other associated ocular complaints. There was no history of any eyelid infections, conjunctivitis, corneal involvement, chronic iridocyclitis, glaucoma, or any other ocular diseases in the past. There was a positive past history for small pox in childhood around

5-6 years of age and to the best knowledge of the patient, she was not vaccinated against pox. Details regarding the course of the disease could not be elicited as the patient was very young at that time. Patient also had a history of pulmonary tuberculosis 20 years back for which the patient took antitubercular treatment for one year. Upon examination, we found no significant findings in eyelids, conjunctiva and cornea. There were multiple greyish-white circular spots varying from one to two mm on the anterior surface of the iris in the left eye which were diffusely scattered throughout the iris surface (Figure 1). On higher magnification with a slit lamp these spots appeared to be situated in a depression with punched-out margins. The blood vessels over iris were normal without any pupillary margin thinning and brisk pupillary reaction was present. There was no iris pigmentation on lens capsule in the left eye while right pseudophakic eye showed posterior capsular opacification (Figure 2). There was no history of any genetic disorders, herpes zoster ophthalmicus or ocular trauma.

The intraocular pressure in both eyes was normal and gonioscopy showed open angle in both eyes (Schaffer's

* Corresponding author.

E-mail address: dpriyankarajy@gmail.com (P. Garg).

grade IV in all quadrants) with no abnormal pigmentations. Fundus examination showed hypermetropic disc without other evident abnormality and mild thinning in the central subfield on OCT macula. The best corrected visual acuity in the right and left eye was 1/60 and 6/36 by Snellen's visual acuity chart, respectively. The retinoscopy in left eye was +8.5 in both the principal meridians. In the right eye fundus evaluation was not possible due to posterior capsular opacification.

Based on the clinical findings a diagnosis of unilateral vitiligo iridis of left eye was made.

Informed and written consent was obtained from the patient for the use of photographs for publication of this article and the procedures followed were in accordance with the ethical standards of the Helsinki Declaration of 1975, as revised in 2000.

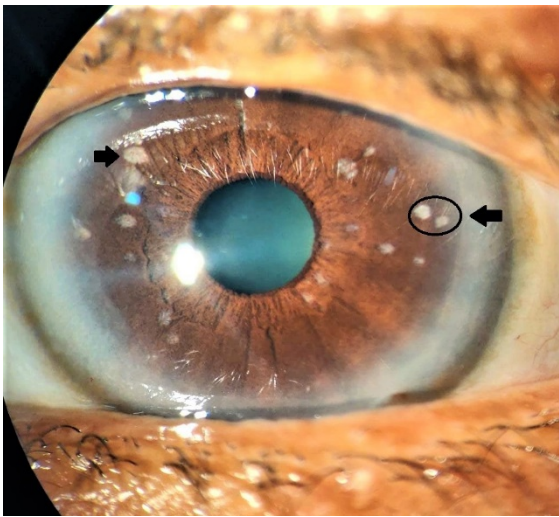


Fig. 1: Picture of the left eye showing multiple greyish-white circular spots on the anterior surface of the iris (circled and marked in black arrow).

3. Discussion

When in 1967 the World Health Organization launched an intensified plan to eradicate the disease, variola virus was estimated to infect 15 million people annually worldwide.¹ Three of every four people infected with smallpox survived. Although 2019 marks the 39th anniversary of the global eradication of small pox, a large number of those infected before 1980 are still surviving, particularly in Africa and Asia, including India, who are now approaching an age when they might be expected to seek eye care, most commonly for cataract, as in our case.

Multifocal areas of iris atrophy are termed as vitiligo iridis, has been previously reported as a late complication of small pox. However, it has not been associated with any vision-threatening consequences. Variola virus,

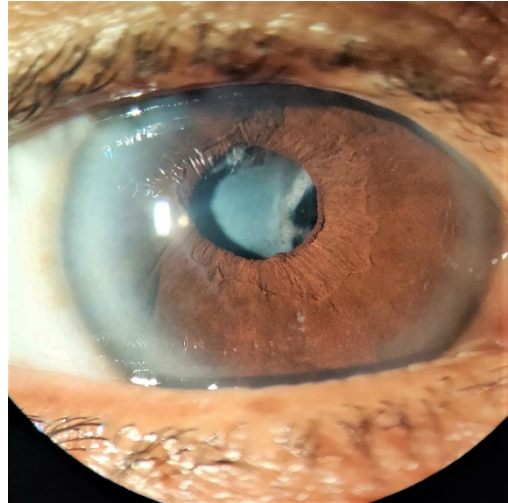


Fig. 2: Picture of right eye showing no iris lesions as in the opposite eye. However, posterior capsular opacification is present.

the cause of smallpox, and vaccinia virus, used in smallpox immunization, are both orthopoxviruses that are associated with serious ocular complications, including eyelid and conjunctival infection, corneal ulceration, disciform keratitis, iritis, optic neuritis, and blindness.² About 5% to 9% of patients with smallpox develop ocular complications and vitiligo iridis has been reported in such patients in the past.³

Plenty of conditions can cause atrophy of iris, such as chronic iridocyclitis, chronic glaucoma, iridodialysis, adherent leucoma, xeroderma pigmentosum, essential progressive atrophy of the iris, a history of any of which was absent in our case. When these patches of iris atrophy are well circumscribed, multiple and punched out, the condition is termed as vitiligo iridis.

Vitiligo iridis commonly results from variola infection (smallpox) and is due to circumscribed effacing of the iris pigment, resulting in rounded white spots on its anterior surface. Shukla et al reported two cases of unilateral vitiligo iridis with small pox as the probably etiological factor.⁴ Similarly, Rathinam et al reported seven patients with multifocal vitiligo iridis, with both unilateral and bilateral presentation, following past history of small pox infection.⁵ This condition may closely mimic iris lesions of xeroderma pigmentosum (Fuchs, 1923).⁴ Kriuckman described this condition in tuberculous iridocyclitis.⁴

Kavitha et al reported three cases of unilateral vitiligo iridis out of which two cases presented with secondary glaucoma in the same eye.¹ The probable mechanism for secondary open-angle glaucoma could be small pox virus-induced trabecular damage with reduced residual function, which may have led to raised IOP later in life. The patchy hyperpigmentation on gonioscopy suggested that the raised IOP could be a variant of pigmentary glaucoma. However,

intraocular pressure as well as the gonioscopy in our case was normal and there was no abnormal pigmentation of the trabecular meshwork.

In our case the patient had a positive history of small pox inclining our diagnosis towards the vitiligo iridis being due to the past small pox infection. Vitiligo iridis as a sequelae of small pox do not require any treatment but demands through examination of the eye to look for any other treatable consequences of the disease. However, vitiligo iridis due to other causes like tuberculosis need prompt treatment of the underlying ocular tuberculosis which can cause vision threatening diseases in the eye. Hence, it becomes of utmost importance to establish the correct cause and diagnosis of the vitiligo iridis.

4. Conclusion

Vitiligo iridis can present as a complication of a number of conditions and hence finding out the probable cause might be slightly difficult, especially when two conditions co-exist as in our case. Since Small pox, tuberculosis and herpetic eye diseases are the most important causes of vitiligo iridis, it is therefore important to find out the causative factor to help prevent misdiagnosis as an unrelated cause of focal or multifocal iris atrophy for further management of the underlying cause.

5. Source of Funding

None.

6. Conflict of Interest

None.

References

1. Kavitha S, Patel SR, Mohini P, Venkatesh R, Sengupta S. Vitiligo iridis and glaucoma: a rare sequelae of small pox. *Eye*. 2015;29(10):1392–1394.
2. Semba RD. The Ocular Complications of Smallpox and Smallpox Immunization. *Arch Ophthalmol*. 2003;121(5):715–719.
3. Russo A. Alterazioni post-vaiuolose dell'iride. *Ann Ottol Clin Ocul*. 1933;61:923–946.
4. Shukla B, Srivastava SP, Jain SC. Unilateral vitiligo iridis. *Br J Ophthalmol*. 1966;50(7):436–437.
5. Rathinam SR, Cunningham ET. Vitiligo iridis in patients with a history of smallpox infection. *Eye*. 2010;24(10):1621–1622.

Author biography

Pragati Garg Professor and Head

Aditi Gupta Junior Resident

Priyanka Raj Junior Resident

Cite this article: Garg P, Gupta A, Raj P. Vitiligo Iridis: A case report. *Indian J Clin Exp Ophthalmol* 2020;6(1):145-147.