



Original Research Article

Comparative study of meibomian gland dysfunction and dry eye in post-cataract surgery patients treated with topical dexamethasone-moxifloxacin versus topical prednisolone-moxifloxacin combination eye drops

Sonia Bhargav^{1,*}, Tarun Arora²¹Bhagat Phool Singh Government Medical College for Women, Sonapat, Haryana, India²Centre for Sight Group of Eye Hospital, New Delhi, India

ARTICLE INFO

Article history:

Received 01-11-2018

Accepted 25-12-2018

Available online 17-03-2020

Keywords:

Dry eye

Meibomian gland dysfunction

Post-cataract surgery

Topical steroids

ABSTRACT

Introduction: Postoperative dry eye and meibomian gland dysfunction (MGD) is common cause of morbidity. Its cause is still elusive and probably multifactorial. Various studies in the past have thrown some light on its mechanism but still we are not able to prevent its occurrence. Till date no study has analyzed the role of topical steroid as one of the factors influencing postoperative MGD and dry eye.

Purpose: The aim of this study was to compare the symptoms and signs of MGD and dry eye in post-cataract surgery patients treated with topical dexamethasone-moxifloxacin versus topical prednisolone-moxifloxacin combination eye drops.

Materials and Methods: Seventy eyes of seventy patients of senile cataract who had no dry eye signs preoperatively, and had undergone uncomplicated phacoemulsification surgery were selected. The patients were divided randomly into two study groups – Group 1 patients were started on dexamethasone sodium phosphate -moxifloxacin hydrochloride and Group 2 patients were started on prednisolone acetate – moxifloxacin hydrochloride combination eye drops postoperatively in a tapering dose for 6 weeks. The data collected by scoring of clinical dry eye signs (corneal staining, TBUT, Schirmer test I and meibomian gland dysfunction assessed by meibum expressibility and meibum quality score) and symptoms scoring by SPEED II questionnaire. The study was done in both the groups preoperatively and at 1 week, 4 weeks and 8 weeks postoperatively. Both the groups were compared using independent paired t- test and Mann – Whitney test.

Results: The mean values of SPEED II, TBUT, corneal staining, meibomian gland expressibility, meibum quality were statistically significantly higher in all followup visits (at 1week, 4 weeks, and 8 weeks) in group 2 as compared to group 1.($p < .001$).

Conclusion: Post cataract surgery patients treated with dexamethasone – moxifloxacin eye drops had statistically significantly lesser symptoms and signs of dry eye and MGD as compared to patients treated with prednisolone-moxifloxacin combination eye drops.

© 2020 Published by Innovative Publication. This is an open access article under the CC BY-NC-ND license (<https://creativecommons.org/licenses/by/4.0/>)

1. Introduction

Many patients complain of dry eye and irritation after cataract surgery and it has been shown that both incidence and severity of dry eye increase after surgery.¹ Prolonged period of morbidity in some patients leads to significant financial and social burden on society. In spite of doing

excellent cataract surgery, the surgeon is often held responsible by the patients for the postoperative discomfort arising from dry eye and this affects his/her reputation and credibility. In the past, studies have reported various factors responsible for development of dry eye after cataract surgeries but none have been clearly understood. The cause may be multifactorial which may include prolonged use of antibiotic-steroid eye drops, surface irregularity at incision site causing decreased tear film break-up time,

* Corresponding author.

E-mail address: soniabhargav@yahoo.co.in (S. Bhargav).

and mucin production from the conjunctiva. Decreased corneal sensation is due to surgical incision which disrupts the cornea-lacrimal reflex which further leads to reduced tear secretion, poor tear film production and stability due to surgically induced ocular inflammation and exposure to light from the operating microscope.^{2–4} Various studies also show strong correlation of meibomian gland dysfunction (MGD) with increase in dry eye symptoms and signs after cataract surgery but the cause of increase in incidence and severity of MGD after cataract surgery is still not known. This study compares two commonly used topical steroids used in their combination form postoperatively i.e. prednisolone acetate-moxifloxacin combination and dexamethasone phosphate-moxifloxacin combination with respect to dry eye and MGD.

2. Materials and Methods

This prospective observational study was done from February 2017 to May 2017 at Centre for Sight eye hospital, New Delhi. All the patients enrolled in the study were informed verbally about the procedures and an informed written consent was obtained from each of them.

Seventy eyes of seventy patients of senile cataract who had no dry eye signs preoperatively were selected consecutively. All the patients underwent uncomplicated phacoemulsification surgery by a single surgeon. The study was done over a period of 4 months. The patients were divided randomly into two study groups – Group 1 patients were started on dexamethasone sodium phosphate (0.1%)-moxifloxacin hydrochloride (0.5%) combination eye drops and Group 2 patients were started on prednisolone acetate (1%)–moxifloxacin hydrochloride (0.5%) combination eye drops postoperatively in a tapering dose for 6 weeks. The data collected by scoring of dry eye parameters and MGD was studied in both the groups preoperatively and at 1 week, 4 weeks and 8 weeks postoperatively.

2.1. Clinical evaluation of dry eye and meibomian gland

Patients were evaluated pre and post operatively based on signs and symptoms of dry eye and MGD. Symptoms were assessed by a Structured Symptom Based Survey Questionnaire (SPEED II questionnaire).⁵ Signs were assessed by bio-microscopic examination of eye consisting of tear film break-up time (TBUT), Schirmer test 1 (ST1), corneal fluorescein staining and MGD based on quality and expressibility of meibum.

2.1.1. Schirmer test-1 (ST1)

Schirmer test 1 was performed by bending and placing the Schirmer strip beneath the temporal lid margin at lateral 1/3rd and medial 2/3rd junction and patient allowed to blink normally. After 5 minutes, the strip was removed and

amount of wetting was measured in mm. Preoperative wetting of the Schirmer strip ≤ 10 mm was considered dry eye and these patients were excluded from the study.

2.1.2. Tear film break-up time (TBUT)

5 μ l of 2% fluorescein solution was instilled in the conjunctival sac, and the integrity of the tear film was monitored and measured up to the time until one or more dry spots appeared in the precorneal tear film from the last blink by slit-lamp microscopy. The test was repeated three times, and the average was calculated. Preoperative TBUT < 10 sec was indicative of dry eye and these patients were excluded from the study. The time interval between ST-1 and TBUT was 10 min.

2.1.3. Standard patient evaluation of eye dryness (SPEED II) questionnaire

A structured symptom based survey was conducted to identify patients with symptoms suggestive of dry eyes and these patients were excluded from the study. Patients were evaluated from score of 0 to 28 based upon the response to a questionnaire of seven questions. Patients with a score of more than 2 were excluded from the study.

2.1.4. Corneal fluorescein staining

Examination through slit-lamp evaluation with cobalt blue illumination was done after instilling 2% fluorescein in the conjunctival sac. The staining was measured for each of the five regions of the cornea: central, superior, temporal, nasal, and inferior. The degree of the staining was based on the following: grade 0-no staining; grade 1-superficial stippling and micro-punctate staining; grade 2-macro-punctate staining with some coalescent areas; and grade 3- numerous coalescent macro-punctate areas. Each of the five regions was graded on a scale from 0 to 3. The scores of the five areas were added to obtain a total score for each eye. Patients with score of more than 0 were excluded in the study.

2.1.5. Biomicroscopic evaluation of meibomian glands–

Patients with preexisting MGD were excluded from the study. The diagnosis of the MGD was made by examining expressibility and quality of meibum.

a) Expressibility of the meibum was scored by the application of the digital pressure to the upper and lower tarsus, and the degree of ease with which the meibum was induced was evaluated semi quantitatively as follows: 0 - clear meibum easily expressed, 1- cloudy meibum expressed with mild pressure, 2- cloudy meibum expressed with more than moderate pressure and 3- meibum not expressed even with the hard pressure. Patients with score of more than 1 were excluded.

b) Quality of the meibum was scored by the digital pressure over meibomian glands of the lower lid and upper

lids. The meibum secretion was graded as follows: 0- clear; 1- cloudy; 2- cloudy with granular debris and 3 - thick like toothpaste. Patients with meibum quality score of more than 1 were excluded.

2.2. Exclusion criteria

Patients with pre-existing lid margin abnormalities like anterior or posterior displacement of the mucocutaneous junction, irregular lid margin, and plugged meibomian gland orifices were excluded. Patients having ocular surgery in past year, history of ocular injury, infection, ocular surface diseases, use of topical ocular medications or contact lens in past year were also excluded from the study. Eyes with any intraoperative complications and in which total surgery time was more than 30 minutes were also excluded.

2.3. Statistical analysis

The collected data was entered in Microsoft Excel spread sheet. Mean \pm SD was calculated for quantitative data of all parameters in both groups. To compare the two groups, the values were analysed using independent t-test and Mann – Whitney U Tests. p- value $<$ 0.001 was considered statistically significant.

2.4. Surgery

One surgeon performed all cataract surgeries. A 2.8 mm sized temporal clear corneal incision was made. Phacoemulsification was performed with stop – chop technique and a foldable intraocular lens was implanted in the posterior chamber.

3. Results

Seventy eyes of seventy patients were recruited in the study. There were 19 males and 16 females in group 1 and 18 females and 17 males in group 2. Mean age in group 1 and group 2 was 64.32 ± 4.76 and 64.89 ± 7.0 respectively. There was no statistical significance between the preoperative values of mean scores of SPEED II questionnaire, TBUT, Schirmer test I, meibum expressibility, meibum quality and corneal staining in both the groups.(Table 1)

3.1. SPEED II questionnaire

There was increase in mean SPEED questionnaire scores in both the groups at all follow-up visits postoperatively. The SPEED score was statistically significantly worse in group 2 (prednisolone+ moxifloxacin) as compared to group 1 (dexamethasone+ moxifloxacin) at 1 week (7.6 ± 1.26 , 2.97 ± 1.8 respectively), 4 weeks (11.6 ± 2.0 , 3.6 ± 1.33 respectively) and 8 weeks postoperatively (18.3 ± 3.1 , 4.57 ± 2.4 respectively) ($P < 0.001$). Each value represents the mean \pm standard error of the mean (SEM). Significance was evaluated with independent t test with $P < .001$.

(Figure 1A)

3.2. TBUT

TBUT values were statistically significantly lower in the group 2 as compared to the group 1 at 1 week (10.8 ± 1.47 , 13.8 ± 1.4 , respectively), 4 weeks (6.80 ± 1.56 , 16.0 ± 1.5 , respectively) and 8 weeks (6.4 ± 1.83 , 16.7 ± 0.95 respectively) ($P < 0.001$, respectively). Interestingly mean TBUT value in group 1 worsened at 1 week (13.97 ± 1.46) from pre operative levels (17.37 ± 1.92) but improved thereafter at 4 weeks (16 ± 1.49) and at 8 weeks (16.74 ± 0.95) reached close to preoperative levels. (Figure 1B)

3.3. Corneal staining

The corneal staining score were statistically significantly worsened in the group 2 as compared to the group 1 at 1 week (0.89 ± 0.1 , 0.14 ± 0.43 respectively), 4 weeks (1.8 ± 1.1 , 0.23 ± 0.5 respectively) and 8 weeks (2.8 ± 1.4 , 0.14 ± 0.35 respectively) ($p < 0.001$). In group 1 there was improvement in mean score at 8 wks (0.14 ± 0.35) from 4 wk (0.23 ± 0.49). In group 2, mean corneal staining value constantly increased in all follow up visits. (Figure 1C)

3.4. Evaluation of meibomian gland

3.4.1. Meibum expressibility

The meibum expressibility worsened in both the groups in all follow up visits. But it was significantly worse in group 2 than in group 1 at 1 week (1.23 ± 0.55 , 0.29 ± 0.46 respectively), 4 weeks (1.60 ± 0.60 , 0.37 ± 0.49 respectively) and 8 weeks postoperatively (1.97 ± 0.68 , 0.29 ± 0.46 respectively) ($P < 0.001$, $P < 0.001$, respectively). At 8 weeks, mean score in group 1 reached close to the preoperative score. (0.17 ± 0.38) (Figure 1D), Table 4

3.4.2. Meibum quality-

The meibum quality was significantly worse in Group 2 than in the group 1 at 1 week (1.34 ± 0.54 , 0.34 ± 0.48 , respectively) and 4 weeks postoperatively (1.57 ± 0.56 , 0.40 ± 0.50 , respectively) and 8 weeks postoperatively (2.00 ± 0.68 , 0.29 ± 0.45 respectively) ($P < 0.001$, respectively). At 8 weeks, mean score in group 1 reached close to the preoperative score. (0.17 ± 0.38) (Figure 1 E), Table 4

3.5. Schirmer test I

Schirmer values were increased in both the groups in all the postoperative follow up visits as compared to the preoperative values. At 1 week and 4 weeks postoperatively, group 1 (18.4 ± 1.6 , 21.6 ± 1.3 respectively) and group 2 (19.7 ± 2.3 , 22.1 ± 2.7 respectively) had no statistically significant difference in values, p value ≥ 0.001 . Tables 2 and 3 At 8 weeks postoperatively, there is statistically

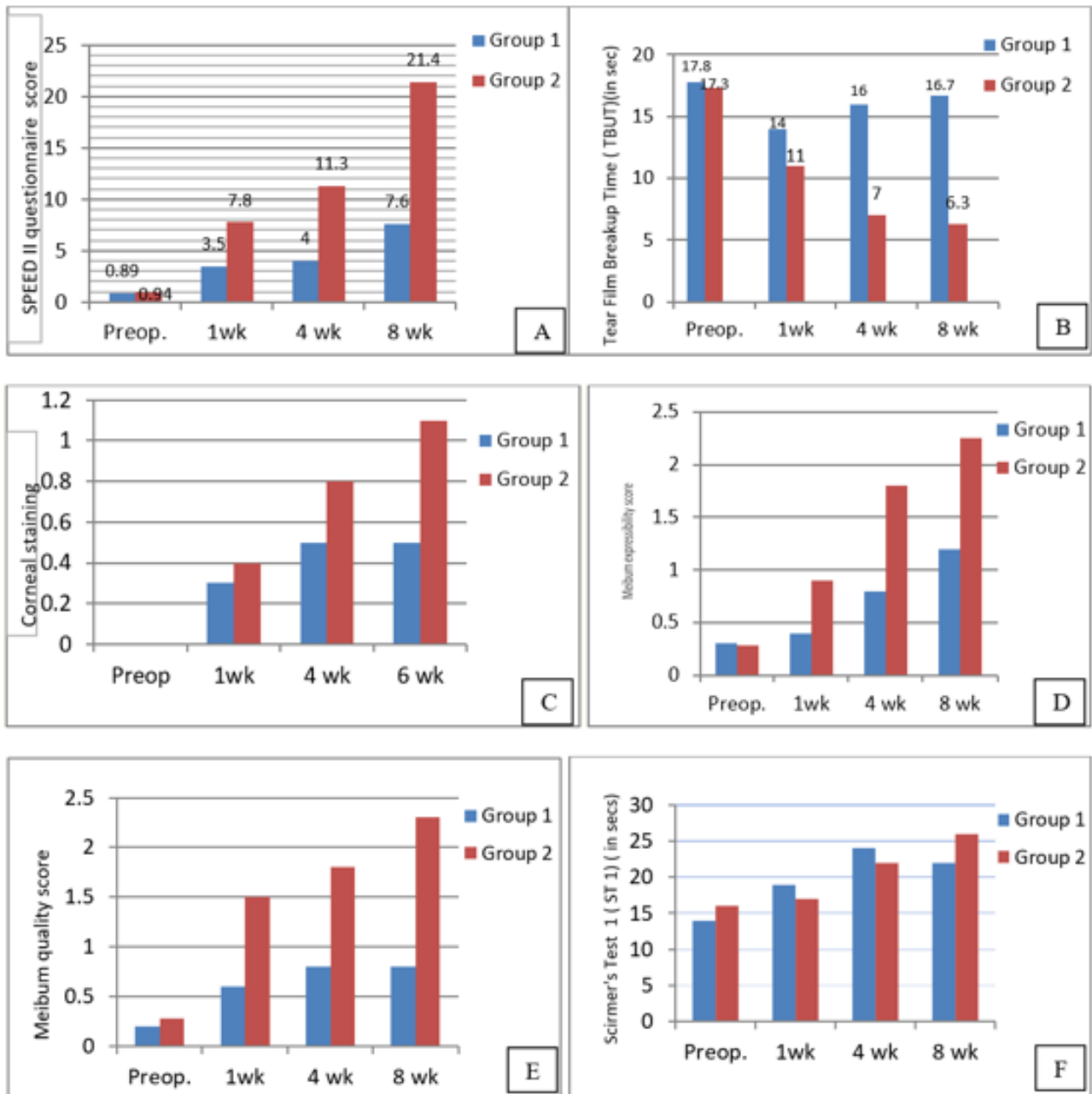


Fig. 1: Graphical representation of mean scores of clinical parameters of dry eye and MGD

(A): Graph showing SPEED II questionnaire mean scores in group 1 and group 2 at pre-operative, 1week, 4weeks and 8 weeks postoperatively.

(B): Graph showing TBUT (insec) mean scores in group 1 and group 2 at pre-operative, 1week, 4 weeks and 8weeks postoperatively.

(C): Graph showing corneal staining mean scores in group 1 and group 2 at pre-operative, 1week, 4 weeks and 8 weeks postoperatively.

(D): Graph showing meibum expressibility mean scores in group 1 and group 2 at pre-operative, 1week, 4weeks and 8 weeks postoperatively.

(E): Graph showing meibum quality mean scores in group 1 and group 2 at pre-operative, 1 week, 4 weeks and 8 week spostoperatively.

(F): Graph showing Shirmer test 1 (in sec) mean scores in group 1 and group 2 at pre-operative, 1week, 4weeks and 8 weeks postoperatively.

Table 1: Preoperative values (mean \pm SD) of SPEED II, TBUT, corneal staining, meibum expressibility, meibum quality, ST 1 scores in group 1 and group 2 and their corresponding p values

	Group 1	Group 2	p value
SPEED II	0.86 \pm 1.00	0.91 \pm 1.01	0.813
TBUT	17.37 \pm 1.92	17.2 \pm 1.47	0.677
Corneal staining	0 \pm 0	0 \pm 0	–
Meibum expressibility	0.17 \pm 0.38	0.23 \pm 0.43	0.557
Meibum quality	0.17 \pm 0.38	0.23 \pm 0.43	0.557
ST I	13.86 \pm 1.91	14.91 \pm 2.11	0.031

significant difference between 2 groups, group1 (20.6 \pm 2.6) and group 2 (23.2 \pm 2.6), p value \leq 0.001. (Figure 1F).

4. Discussion

After cataract surgery, patients often experience dry eye symptoms such as eye irritation and complain of tear film dysfunction.⁶ Various studies have shown that ocular discomfort after cataract surgery could possibly be caused by MGD. Kim et al reported thinning of lipid layer after cataract surgery.⁷ The DEWS management and therapy subcommittee reported that any severity levels of the dry eye may have MGD.⁸ Modified or deficient meibum causes evaporative type dry eye that are features of MGD.^{9,10} Statistically significant worsening of lid margin abnormality, deterioration of meibum quality and expressibility has been demonstrated after cataract surgery performed by the phacoemulsification.¹¹ Alterations in the meibomian gland expressibility and TBUT which persist for up to 3 months postoperatively suggesting a direct role of cataract surgery in causing MGD by an obstructive mechanism.¹²

Despite its clinical importance in postoperative dry eye, the cause of MGD has not been investigated sufficiently and remains elusive. Till date no study has been done to evaluate relationship of topical steroid with increase in MGD postoperatively.

Patients with MGD demonstrate significantly higher culture positivity and more complex bacterial profiles than the normal population. Bacterial related cytotoxicity and/or inflammation may contribute to the pathological process of MGD.¹³ In view of this, infective etiology of MGD cannot be ruled out in spite of using potent topical broad spectrum antibiotics after cataract surgery.

In our study, there was increase in MGD and dry eye symptoms and signs in prednisolone acetate group as compared to dexamethasone sodium phosphate group which was statistically significant. This establishes a strong relation of MGD to topical prednisolone acetate suspension. In dexamethasone group after initial worsening of dry eye symptoms and signs, there was improvement in subsequent follow up visits and by 8 weeks SPEED II, TBUT, meibum expressibility and meibum quality scores reached close to their respective preoperative levels.

Indiscriminate use of steroid is known to cause secondary infection. Topical steroids which are often used to treat MGD may also be responsible for causing MGD due to secondary bacterial infection of glands which is augmented by loss of normal ocular surface microbiome due to the use of betadine and broad spectrum antibiotics topically. Lid dysfunction resulting from the use of a lid speculum, decrease in blink rate derived from a decrease in corneal sensation, ocular surface inflammation further add to the insult. In our study prednisolone was involved in MGD. This may be due to its physical properties. Topical prednisolone acetate is a suspension which gets deposited over the lid margin and lashes of patients postoperatively. Moreover washing of eyes with water is not done for at least 2 weeks as part of general precautions being followed routinely after cataract surgery. The crystallization and deposition of prednisolone acetate over meibomian gland orifices may cause secondary infection of these glands due to constant exposure to steroid leading to their dysfunction and dry eye. In contrast, dexamethasone sodium phosphate is a clear solution and after a brief contact with the gland orifices, gets washed away by tears in a few blinks leading to less contact time.

Dexamethasone has been shown to give similar results to prednisolone in controlling postoperative inflammation in uncomplicated cases. In a study by Brandon J. Baartman et al comparing Prednisolone versus dexamethasone for prevention of pseudophakic cystoid macular edema there was no significant difference in the rate of pseudophakic CME when either prednisolone acetate or dexamethasone sodium phosphate was used after cataract surgery.¹⁴

Currently, two drug groups are used to control ocular inflammation postoperatively: steroids and NSAIDs. Generally both are prescribed postoperatively. Steroids are potent anti-inflammatory agents that work by acting on a number of intercellular inflammatory mediators, whereas NSAIDs work by inhibiting the cyclooxygenase enzymes. Globally topical steroids have been used as a gold standard in controlling intraocular inflammation after cataract surgery. But in today's scenario with advanced and micro incision techniques of cataract surgery which are minimally invasive, role of steroids is relatively less compared to previous era of surgeries involving more manipulation of internal eye structures leading to greater

Table 2: 1 week postoperative values (mean \pm SD) of SPEED II, TBUT, corneal staining, meibum expressibility, meibum quality, ST I scores in group 1 and group2 and their corresponding p values

	Group 1	Group 2	p value
SPEED II	2.97 \pm 1.29	7.66 \pm 1.26	<.001
TBUT	13.97 \pm 1.46	10.80 \pm 1.47	<.001
Corneal staining	0.14 \pm 0.43	0.89 \pm 0.10	<.001
Meibum expressibility	0.29 \pm 0.46	1.23 \pm 0.55	<.001
Meibum quality	0.34 \pm 0.50	1.34 \pm 0.54	<.001
ST I	18.40 \pm 1.63	19.71 \pm 2.32	0.008

Table 3: 4 week postoperative values (mean \pm SD) of SPEED II, TBUT, corneal staining, meibum expressibility, meibum quality, ST I scores in group 1 and group2 and their corresponding p values

	Group 1	Group 2	p value
SPEED II	3.57 \pm 1.33	11.66 \pm 2.07	<.001
TBUT	6.86 \pm 1.56	16 \pm 1.49	<.001
Corneal staining	0.23 \pm 0.49	1.80 \pm 1.15	<.001
Meibum expressibility	0.37 \pm 0.50	1.60 \pm 0.60	<.001
Meibum quality	0.40 \pm 0.50	1.57 \pm 0.56	<.001
ST I	21.60 \pm 1.30	22.14 \pm 2.18	0.315

Table 4: 8 weeks postoperative values (mean \pm SD) of SPEED II, TBUT, corneal staining, meibum expressibility, meibum quality, ST I scores in group 1 and group 2 and their corresponding p values

	Group 1	Group 2	p value
SPEED II	4.57 \pm 2.50	18.29 \pm 3.16	<.001
TBUT	6.40 \pm 1.83	16.74 \pm 0.95	<.001
Corneal staining	0.14 \pm 0.35	2.83 \pm 1.40	<.001
Meibum expressibility	0.29 \pm 0.46	1.97 \pm 0.68	<.001
Meibum quality	0.29 \pm 0.46	2.00 \pm 0.69	<.001
ST I	20.54 \pm 1.16	23.23 \pm 2.60	<.001

intraocular inflammation.

Recent studies have favored use of topical NSAIDs alone over topical steroids to control inflammation post surgery. Kessel et al, in a systematic literature search identified fifteen randomized trials comparing topical steroids with topical NSAIDs in controlling inflammation and preventing postoperative cystoid macular edema in patients undergoing phacoemulsification with posterior chamber intraocular lens implantation, topical NSAIDs were found to be more effective in controlling postoperative inflammation after cataract surgery which was also not associated with increased intraocular pressure. They were also more effective than topical steroids in preventing postoperative cystoid macular edema.¹⁵

5. Conclusion

Post cataract surgery dry eye may be caused by MGD. Topical prednisolone acetate used in suspension form may induce or aggravate MGD and dry eye after surgery possibly due to secondary bacterial infection of glands. Dexamethasone in comparison causes lesser morbidity due to MGD and dry eye. In our opinion, judicious and limited use of topical steroids can reduce the incidence and aggravation of MGD post surgery. NSAIDs are equally

effective alternative in uncomplicated cases and can be used alone.

6. Source of Funding

Nil.

7. Conflicts of Interest

Nil.

References

- Ram J, Gupta A, Brar GS, Kaushik S, Gupta A. Outcomes of phacoemulsification in patients with dry eye. *J Cataract Refract Surg*. 2002;28(8):1386–1389. doi:10.1016/s0886-3350(02)01387-1.
- Sutu C, Fukuoka H, Afshari NA. Mechanisms and management of dry eye in cataract surgery patients. *Curr Opin Ophthalmol*. 2016;27(1):24–30.
- Cho YK, Kim MS. Dry eye after cataract surgery and associated intraoperative risk factors. *Korean J Ophthalmol*. 2009;23:65–73.
- Li XM, Hu L, Hu J, Wang W. Investigation of dry eye disease and analysis of the pathogenic factors in patients after cataract surgery. *Cornea*. 2007;26(9):16–20.
- Ngo W, Situ P, Keir N, Korb D, Blackie C, Simpson T. Trefford Dip Optom, Psychometric Properties and Validation of the Standard Patient Evaluation of Eye Dryness Questionnaire. *Cornea*. 2013;32(9):1204–1210.

6. Hardten DR. Dry Eye Disease in Patients After Cataract Surgery. *Cornea*. 2008;27(7):855. doi:10.1097/ico.0b013e31816f6854.
7. Kim JS, Lee H, Choi S, Kim EK, Seo KY, Kim TI. Assessment of the tear film lipid layer thickness after cataract surgery. *Semin Ophthalmol*. 2018;33(2):231–236.
8. Pflugfelder SC, Geerling G, Kinoshita S. Management and Therapy of Dry Eye Disease: Report of the Management and Therapy Subcommittee of the International Dry Eye Workshop. *Ocul Surf*. 2007;5:163–178.
9. Han KE, Yoon SC, Ahn JM, Nam SM, Stulting RD, Kim EK. Evaluation of dry eye and meibomian gland dysfunction after cataract surgery. *Am J Ophthalmol*. 2014;157(6):1144–1150.
10. Goto E, Endo K, Suzuki A, Fujikura Y, Matsumoto Y, Tsubota K. Tear Evaporation Dynamics in Normal Subjects and Subjects with Obstructive Meibomian Gland Dysfunction. *Invest Ophthalmol Vis Sci*. 2003;44(2):533–539. doi:10.1167/iops.02-0170.
11. Park Y, Hwang HB, Kim HS. Observation of influence of cataract surgery on the ocular surface. *PLOS One*. 2016;.
12. Ameen AE, Majzoub S, Vandermeer G, Pisella PJ. Influence of cataract surgery on Meibomian gland dysfunction. *J Fr Ophthalmol*. 2018;41(5):526–535.
13. Zhang SD, He JN, Niu TT, Chan CY, Pang CP. Bacteriological profile of ocular surface flora in meibomian gland dysfunction. Shao Dan Zhang, Jing Na He. *Ocul Surface*. 2017;15(2):242–247.
14. Baartman BJ, Gans R, Goshe J. Prednisolone versus dexamethasone for prevention of pseudophakic cystoid macular edema. *Can J Ophthalmol*. 2018;53(2):131–134. doi:10.1016/j.cjjo.2017.08.012.
15. Kessel L, Tendal B, Jørgensen KJ, Erngaard D, Flesner P, et al. Post-cataract Prevention of Inflammation and Macular Edema by Steroid and Nonsteroidal Anti-inflammatory Eye Drops. *Ophthalmol*. 2014;121(10):1915–1924. doi:10.1016/j.ophtha.2014.04.035.

Author biography

Sonia Bhargav Assistant Professor

Tarun Arora Senior Consultant

Cite this article: Bhargav S, Arora T. Comparative study of meibomian gland dysfunction and dry eye in post-cataract surgery patients treated with topical dexamethasone-moxifloxacin versus topical prednisolone-moxifloxacin combination eye drops. *Indian J Clin Exp Ophthalmol* 2020;6(1):50-56.