



Original Research Article

A clinical study of secondary glaucoma

Suresh Ramanarao^{1,*}, Divya Jain¹¹Dept. of Ophthalmology, Shadan Institute of Medical Sciences, Hyderabad, Telangana, India

ARTICLE INFO

Article history:

Received 31-10-2019

Accepted 11-11-2019

Available online 17-03-2020

Keywords:

Age

Diabetes

Lens induced glaucoma

Secondary glaucomas

ABSTRACT

Introduction: Secondary Glaucoma is a group of disorders in which raised intraocular pressure is associated with some primary ocular or systemic cause. This prospective study aims to evaluate the various commonly seen causes of secondary glaucoma.

Materials and Methods: A total of 50 patients with raised intraocular pressure coming to a teaching hospital during a period of three years were studied. Patients with primary glaucoma were excluded from this study. Clinical evaluation was done in all the cases and the visual acuity, intraocular pressure and the optic nerve head changes were recorded. The various age groups and the gender distribution were noted. Also history of diabetes, hypertension and trauma was specifically asked for.

Results: Out of 50 patients, a total of 29 (58%) patients were above 60 years of age. Predominantly 28 (56%) were male patients. Visual acuity was less than 3/60 in 34 (68%) of all patients. The mean intraocular pressure recording was 34 mm of Hg, within a range of 21 to 46 mm of Hg. Only 23 (46%) patients showed optic neuropathy. The most common causes were lens induced glaucoma seen in 24 (48%) cases and next 14% each seen in neovascular glaucoma and pseudoexfoliative glaucoma. Diabetes and/or Hypertension were present in 8 (16%) patients.

Conclusion: This study identifies ocular factors like cataracts in lens induced glaucoma, age factor in pseudoexfoliative glaucoma and systemic factors like diabetes and/or hypertension in neovascular glaucoma, and also emphasizes that the prompt detection of these causes can prevent severe visual impairment.

© 2020 Published by Innovative Publication. This is an open access article under the CC BY-NC-ND license (<https://creativecommons.org/licenses/by/4.0/>)

1. Introduction

Secondary glaucoma is a group of disorders in which the increased intraocular pressure is associated with some identifiable primary ocular or systemic disease. This can potentially lead to severe visual impairment and blindness. The mean prevalence of secondary glaucoma is 18% of the mean prevalence of primary open angle glaucoma in the world.¹ Individuals with secondary glaucoma tend to report promptly to the ophthalmologist since there is often marked reduction in visual acuity, apart from pain.² In a large tertiary eye care centre in South India, various secondary glaucoma registered in the year 2000 were about 6.0 % of total new cases of glaucoma seen annually.³

Depending on primary cause, secondary glaucoma are classified as: lens induced (phacomorphic, phacolytic, lens particle and phacoanaphylactic) glaucoma, neovascular glaucoma, pseudoexfoliative, uveitic glaucoma, pigmentary, traumatic glaucoma, aphakic/pseudophakic glaucoma, steroid induced, and glaucoma associated with iridocorneal dysgenesis. On gonioscopic examination, all these patients were found to have either secondary open angle or secondary angle closure.

Aim of this prospective study is for the early identification of the commonly occurring ocular and systemic diseases that predispose to the secondary glaucoma, and the further evaluation of these causes which would be important in limiting the severe visual impairment and blindness.

* Corresponding author.

E-mail address: suresh_ramanarao@yahoo.com (S. Ramanarao).

2. Materials and Methods

A total of 50 patients of secondary glaucoma attending the department of Ophthalmology, Shadan Institute of Medical Sciences, Hyderabad over a period of 3 years from July 2015 to June 2018 were included in the study. The institute ethical committee approval was obtained before commencement of the study. Prior informed consent was taken from every patient in the study. Patients with primary open angle and primary angle closure glaucoma were excluded. Patients included in the clinical study underwent a detailed history taking for age, sex, duration of symptoms and in addition a specific history of cataract surgery, steroid usage and trauma was asked for.

A comprehensive ophthalmic examination included visual acuity by Snellen's chart and anterior segment examination by slit lamp biomicroscopy. Glaucoma examination included intraocular pressure recording by Goldmann applanation tonometer, gonioscopy by Goldmann 3 mirror gonioscope and stereoscopic fundus examination by the Volk +90 D convex lens. Laboratory investigations were done for common systemic diseases like diabetes, hypertension, tuberculosis and autoimmune disorders. All secondary glaucoma presenting in the acute condition with very high intraocular pressure were managed with intravenous Mannitol. The data collected was statistically analysed in tables and graphs and wherever possible photographic images were taken.

3. Results

In the study undertaken by us over a period of 3 years, a total of 50 patients were identified and examined. Raised intraocular pressure of more than 21 mm Hg was taken for the study and all cases of primary glaucoma were excluded. In the age group distribution (Table 2), from 0-20 years there were n=5 patients, 21-40 age group had 6 patients, from 41-60 years there were 10 patients, and in the age group of 60 years and above significantly there were 29 (58%) patients. Predominantly n=28 (56%) patients were males and the remaining 22 (44%) were females.

After detailed clinical examination, the various common causes found in our study were tabulated (Figure 1). A large total of 24 (48%) of all patients were diagnosed as having lens induced glaucoma, and in this sub group 10 were diagnosed as phacomorphic glaucoma, 11 were having phacolytic glaucoma and 2 had lens particle glaucoma. Incidentally there was 1 case due to lens subluxation. Out of 7 (14%) cases of neovascular glaucoma, 6 patients were found to have proliferative diabetic retinopathy and 1 patient had ischemic central retinal vein occlusion. Diabetes and/or hypertension were significant in these 7 patients. This was followed by 7 (14%) patients having pseudoexfoliative glaucoma. In aphakic / pseudophakic patients, 4 (8%) developed secondary glaucoma. 3 patients of uveitis

recorded raised intraocular pressure and 1 of them was diagnosed as having Fuch's heterochromic iridocyclitis. In 2 (4%) patients of closed globe injury having secondary glaucoma, 1 case showed presence of angle recession. 1 patient of secondary glaucoma having high myopia showed pigments in the trabecular meshwork, and a history of prolonged steroid misuse was the cause in 1 patient with secondary glaucoma. Lastly, 1 young female patient diagnosed as having Axenfeld Rieger syndrome and showing iridocorneal dysgenesis had secondary glaucoma in our study.

Visual acuity recorded was divided into 4 groups as (Table 1) : VA <3/60, VA 3/60-6/60, VA 6/60-6/18 and VA >6/18-6/6. A total of 34 patients (68%), i.e. including all the lens induced, neovascular and traumatic glaucoma had visual acuity <3/60. Further 10 of the patients recorded VA <6/ 60, and the remaining 06 cases had visual acuity in the range of 6/60 upto 6/6. The mean of the intraocular pressure recordings was found to be 34 mm of Hg, in a range from 21 mm to 46 mm of Hg in all the patients. The highest intraocular pressure was recorded in neovascular glaucoma and also in patients with lens induced glaucoma. These acute cases were managed by intravenous Mannitol. Glaucomatous optic neuropathy diagnosed by optic nerve head changes and visual field defects were seen in only 23 (46%) of patients in this study.

Causes of secondary glaucoma

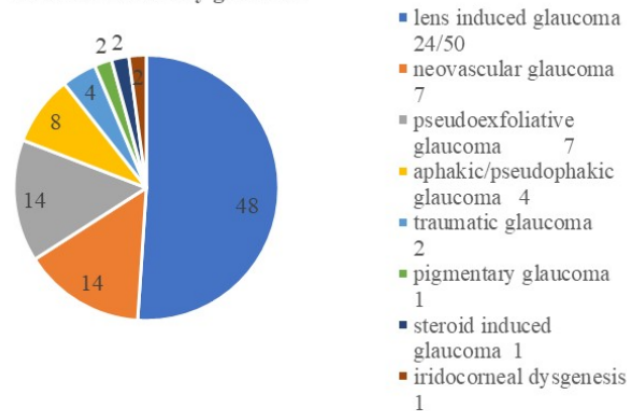


Fig. 1: Showing distribution according to cause of secondary glaucoma

4. Discussion

This prospective study of 50 cases of secondary glaucoma presenting at an urban teaching hospital was carried out by us over a period of 3 years from July 2015 to June 2018. The Glaucoma Services at the Aravind Eye Hospital, a large tertiary eye care centre in South India, registered 367 individuals with various secondary glaucoma in the year 2000.² This represents about 6.0% of total new cases of

Table 1: Visual acuity

Causes of secondary glaucoma	Visual Acuity <3/60	VA 3/60 -6/60	VA 6/60 -6/18	VA >6/18 -6/6
Lens induced glaucoma	24	-	-	-
Neovascular glaucoma	7	-	-	-
Pseudoexfoliative glaucoma	-	3	3	1
Aphakic/pseudophakic glaucoma	1	3	-	-
Uveitic glaucoma	-	2	1	-
Traumatic glaucoma	2	-	-	-
Pigmentary glaucoma	-	-	1	-
Steroid induced glaucoma	-	1	-	-
Iridocorneal dysgenesis	-	1	-	-
Total	34	10	5	1

Table 2: Age distribution

Causes of secondary glaucoma	Age 0-20 years	21-40 years	41-60 years	60 years & above
Lens induced glaucoma	2	2	5	15
Neovascular glaucoma	-	-	2	5
Pseudoexfoliative glaucoma	-	-	2	5
Aphakic/pseudophakic glaucoma	-	-	1	3
Uveitic glaucoma	-	2	-	1
Traumatic glaucoma	2	-	-	-
Pigmentary glaucoma	-	1	-	-
Steroid induced glaucoma	-	1	-	-
Iridocorneal dysgenesis	1	-	-	-
Total	5	6	10	29

glaucoma seen annually.³ Study from north India reports a 6.72% diagnosis of secondary glaucoma out of all glaucoma referrals in a five-year hospital-based retrospective analysis (1995- 99).⁴

In our study, in the age group distribution, from 41-60 years there were 10 (20%) patients, and in the age group of 60 years and above significantly there were 29 (58%) patients. Thus, in all 39 (78%) patients presented in the age group from 41 years to 60 years and above. Similarly in an epidemiology done in 1999 by Johnson GJ, he found a significantly high prevalence rate in Wales in the age group 40-74.⁵

In this study, n= 28 patients (56%) were males and the remaining 22 (44%) were females, showing a male predominance in a ratio of 1.3:1 In another study of patients having secondary glaucoma, male female ratio was 2.2:1, and also in India, men are more likely to reach a higher center, as reported in a tertiary glaucoma center in the year 2005 by Gadia R et al.⁶

In our study, significantly 24 (48%) patients were diagnosed as having lens induced glaucoma, and followed by 7 (14%) cases of neovascular glaucoma. Similarly the statistics of the Glaucoma Services of the Aravind Eye Hospital, Madurai, India in the year 2000, out of 367 individuals with various secondary glaucoma, lens

induced glaucoma showed 158 (43%) patients, followed by neovascular glaucoma with 58 (15%) patients.² As recorded in our study, and similarly in the above study too, lens induced glaucoma due to hypermature cataracts are an important cause of secondary glaucoma in the developing world.³ Secondary glaucoma associated with crystalline lens subluxation was studied by Inatani M, et al,⁷ and in our study we reported 1 case.

Out of our 7 patients with neovascular glaucoma, 6 were due to proliferative diabetic retinopathy and 1 patient had ischemic central retinal vein occlusion. In a study in 1974, Diabetic retinopathy and central retinal vein occlusion account for nearly two-thirds of patients with neovascular glaucoma.⁸ Other studies showed ocular neovascularisation and glaucoma may develop in 33 – 64% of eyes with untreated, proliferative diabetic retinopathy.⁹ Ischaemic central retinal vein occlusion (thrombotic glaucoma) is the second most common cause of ocular neovascularisation and glaucoma as seen in 58–86% of these eyes.¹⁰

In the post operative aphakic / pseudophakic patients seen by us, 4 (8%) cases developed secondary glaucoma. In the Aravind study, Aphakic/Pseudophakic glaucoma were also seen in 38 (10%) patients.² As per Gadia et al,⁶ thirty years earlier the commonest cause was aphakic glaucoma, which has dramatically reduced with

advancements in cataract surgery. In all eyes with pseudoexfoliation, Aqueous misdirection syndrome has to be carefully evaluated.

In our findings, out of 2 (4%) patients having closed globe injury and secondary glaucoma, 1 patient showed presence of angle recession. Irido-corneal angle recession was seen in 61.9% of traumatic glaucoma as reported by Ellong et al.¹¹ Both patients had visual acuity of less than 3/60 in our study. In the current profile of secondary glaucoma by Gadia et al published in 2008,⁶ traumatic glaucoma cases have increased in incidence from 8.4% to 13%, and of all the traumatic glaucoma patients, 71% were below 30 years of age, and males were 90%. In their study, fifty per cent of traumatic glaucoma had an IOP of ≥ 30 mm Hg and 56% patients had a vision $\leq 20/200$.⁶

Out of 2 cases of uveitic glaucoma, in our study 1 patient had Fuch's heterochromic iridocyclitis with secondary glaucoma and this was also reported by La Hey E, et al in 1993.¹² Axenfeld-Rieger Syndrome associated with congenital glaucoma was studied by Mukesh Tanwar et al¹³ and we also had 1 similar case reporting to our Ophthalmology department.

Visual acuity findings were divided into 4 groups in our study and a total of n= 34 patients (68%), i.e. including all the lens induced and neovascular glaucoma and traumatic glaucoma had visual acuity $<3/60$ (20/200). Similarly secondary glaucoma had very poor vision of $<20/200$ at presentation in almost all types except steroid-induced and aphakic glaucoma in a large detailed study of 579 patients in 2005 reported by Gadia et al.⁶

The mean of the intraocular pressure recordings in our study of 50 patients was found to be 34 mm of Hg, in a range from 21 mm to 46 mm of Hg. The highest intraocular pressures recorded by us were in neovascular glaucoma and followed in patients with lens induced glaucoma. Ritu Gadia et al⁶ recorded a baseline IOP > 30 mm Hg in 78% cases of neovascular glaucoma, followed by 60% in pseudophakic glaucoma, 50% in traumatic glaucoma.

Glaucomatous optic neuropathy diagnosed by optic nerve head changes and visual field defects were seen in only 23 (46%) of all patients in our study. In contrast, in a study by Gadia et al,⁶ most of the 579 patients evaluated had optic neuropathy changes, with 75% in neovascular glaucoma, 58% in aphakic/pseudophakic glaucoma. But visual fields were available in only a few of their patients as the rest had very poor visual acuity.⁶

5. Conclusion

Of all patients of secondary glaucoma, lens induced glaucoma is still the major cause and we can conclude that prompt management of hypermature cataracts and high quality of cataract surgeries can prevent secondary

glaucoma. Good control of diabetes and hypertension is advised to bring down the high incidence of neovascular glaucoma. Awareness for avoiding ocular injuries can reduce the increasing incidence of traumatic glaucoma and also susceptible patients are cautioned against misuse of steroids. In conclusion the prompt diagnosis of common causes of secondary glaucoma can prevent the severe visual impairment and blindness as reported by us in this study.

6. Source of Funding

None.

7. Conflict of Interest

None.

References

1. Quigley H. The number of people with glaucoma worldwide. *Br J Ophthalmol*. 1996;80:389-393.
2. Krishnadas R, Ramakrishnan R. Secondary Glaucomas: The Tasks Ahead. *Community Eye Health*. 2001;14(39):40-42.
3. Ramakrishnan R, Nirmalan PK, Krishnadas R, Thulasiraj RD, Tielsch JM, et al. Glaucoma in a rural population of southern India: The Aravind comprehensive eye survey. *Ophthalmol*. 2004;111:331.
4. Das J, Bhomaj S, Chaudhuri Z, Sharma P, Negi A, Dasgupta A. Profile of glaucoma in a major eye hospital in north India. *Indian J Ophthalmol*. 2001;49:25-30.
5. Johnson GJ, Minassian DC, Weale R. The Epidemiology of Eye Disease. Chapman & Hall ; 1999,.
6. Gadia R, Sihota R, Dada T, Gupta V. Current profile of secondary glaucomas. *Indian J Ophthalmol*. 2008;56(4):285-289.
7. Inatani M. Secondary glaucoma associated with crystalline lens subluxation. *J Cataract Refract Surg*. 2000;26(10):1533-1536.
8. Grant WM, Symposium on ocular therapy. Management of neovascular glaucoma. vol. 7. The CV Mosby Co ; 1994,.
9. Madsen PH. Rubeosis of the iris and haemorrhagic glaucoma in patients with proliferative diabetic retinopathy. *Br J Ophthalmol*. 1971;55:368-371.
10. Sinclair SM, Gragoudas E. Prognosis for rubeosis iridis following central retinal vein occlusion. *Br J Ophthalmol*. 1979;63:735-742.
11. Ellong A, Ebana MC, Nyouma ME, Bella HA, Ngosso A, Njoh LC. Post-traumatic glaucoma with irido-corneal angle injuries in Cameroon. *Bull Soc Belge Ophthalmol*. 2005;298:21-28.
12. Hey EL. Treatment and prognosis of secondary glaucoma in Fuch's heterochromic iridocyclitis. *Am J Ophthalmol*. 1993;116(3):327-340.
13. Tanwar M, Dada T, Dada R. Axenfeld-Rieger Syndrome Associated with Congenital Glaucoma and Gene Mutations. *Case Rep Med*. 2010;2010:212656.

Author biography

Suresh Ramanarao Associate Professor

Divya Jain Assistant Professor

Cite this article: Ramanarao S, Jain D. A clinical study of secondary glaucoma. *Indian J Clin Exp Ophthalmol* 2020;6(1):5-8.