



## Original Research Article

## Evaluation of Central Corneal Thickness and clinical ocular profile of Patients presenting with Pseudoexfoliation at a tertiary care centre

Nishat Sultana<sup>1</sup>, Shalini<sup>1,\*</sup><sup>1</sup>Dept. of Ophthalmology, Minto Eye Hospital, Bengaluru, Karnataka, India

## ARTICLE INFO

## Article history:

Received 13-07-2019

Accepted 17-09-2019

Available online 27-11-2019

## Keywords:

Pseudoexfoliative glaucoma

central corneal thickness

intraocular pressure

## ABSTRACT

**Introduction:** Pseudoexfoliation syndrome is the most common identifiable cause of open angle glaucoma world-wide. It is a systemic disorder with important eye manifestations.

**Aims:** To compare central corneal thickness (CCT) in pseudoexfoliation syndrome (PEX) and pseudoexfoliative glaucoma (PXG) with the normal eyes.- To document ocular profile of PEX and PXG

**Material and Methods:** cross-sectional, hospital based observational study done from November 2018-May 2019. Sixty-five patients each in PEX and PXG were included for detailed study. To compare CCT, 65 age matched normal subjects were enrolled.

**Results and Conclusion:** The prevalence of PEX and PXG increases with age. It was predominantly seen in males. Most of the patients had bilateral presentation, with PEX material most commonly found at pupillary margins. Open angle in most patients but presence of narrow angles in PXG group was statistically significant than PEX. CCT was thinner in both PEX and PXG than normal which was statistically significant. Twenty-one patients in PXG group underwent combined cataract surgery and trabeculectomy owing to high pressure and advanced optic neuropathy.

© 2019 Published by Innovative Publication. This is an open access article under the CC BY-NC-ND license (<https://creativecommons.org/licenses/by/4.0/>)

### 1. Introduction

seudoexfoliation syndrome (PEX) first described by Lindberg in 1917,<sup>1</sup> is an idiopathic, age-related systemic microfibrilopathy, characterized by progressive accumulation and gradual deposition of extracellular grey and white material over various tissues.<sup>2</sup> The material is classically found on the corneal endothelium, pupillary border, the iris, trabecular meshwork, lens capsule, zonules and ciliary body. The pseudoexfoliative material can also be present in other organs, such as the heart, lungs, liver, gall-bladder, kidneys and meninges suggesting aberrant connective tissue metabolism.<sup>3</sup>

PEX occurs worldwide and prevalence rates vary from 10 to 20% of the general population over the age of 60 years.<sup>4</sup> Various hospital-based studies from India have reported a prevalence rate between 1.8<sup>5</sup> and 13.5%<sup>6</sup> in adults over 45

years of age.

Pseudoexfoliation syndrome predisposes to a number of ocular co-morbidities like corneal endothelial dysfunction, poor mydriasis, zonular weakness and is a risk factor for zonular dialysis and higher rate of vitreous loss during cataract surgery.<sup>7,8</sup> It is the most common identifiable cause of secondary glaucoma, accounting for approximately 25% of all open angle glaucoma's worldwide,<sup>9</sup> also being the most frequent cause of unilateral glaucoma. Pseudoexfoliative Glaucoma (PXG) is typically associated with higher mean intraocular pressure (IOP), greater diurnal variations, marked pressure spikes, greater severity of optic neuropathy and more rapid visual field loss.<sup>10,11</sup> PXG is more likely to be recalcitrant to treatment than primary open angle glaucoma and has a higher incidence of progression. Thus, the importance of early diagnosis of the disease cannot be overemphasized.

Goldmann's applanation tonometry (GAT) is considered the gold standard technique of measuring the IOP.<sup>12</sup> IOP

\* Corresponding author.

E-mail address: [shalinidocs08@gmail.com](mailto:shalinidocs08@gmail.com) (Shalini).

measurements by GAT are influenced by several factors among which Central Corneal Thickness is considered the most important.<sup>13,14</sup> GAT tends to overestimate the IOP in thicker corneas and underestimate the IOP in thinner corneas.<sup>15</sup> Though, measurement of CCT is an important component of a complete eye examination, special prominence must be given in those who are at considerable risk of developing glaucoma such as Pseudoexfoliation syndrome to enable early diagnosis and expedite apt management by de ducing the exact target pressure to be attained.

There is no consensus on CCT in patients with Pseudoexfoliation syndrome or glaucoma. Though m any studies have reported similar CCT in PEX and normal eyes,<sup>16-18</sup> there have been studies showing either thinner<sup>19,20</sup> or thicker<sup>21,22</sup> CCT in PEX eyes compared to normal.

Therefore, the primary aim of the present study was to compare CCT in eyes with Pseudoexfoliation syndrome and Pseudoexfoliative glaucoma with normal healthy eyes. The other purpose was to document the clinical profile of patients with Pseudoexfoliation.

## 2. Materials and Methods

### 2.1. Subjects

This study was a prospective, cross-sectional, observational study. 65 patients each with pseudoexfoliation syndrome, pseudoexfoliative glaucoma who underwent ophthalmological examination at a tertiary eye care center in South India between November 2018 and May 2019 were included in the study. PEX and PXG patients were diagnosed at the time of the study and had never used any anti -glaucoma medications before. To compare the CCT of PEX and PXG with the healthy eyes, 65 age matched patients with normal eyes were included in the study.

Exclusion criteria were previous intraocular surgery in the eye with PEX/PXG, use of anti-glaucoma medications or topical/systemic steroids within the last six months, history of ocular trauma, uveitis or corneal scars. Patients were explained about the study and informed consent for the same was obtained.

Relevant detailed medical and ocular history were noted for each patient.

### 2.2. Examination

All patients with pseudoexfoliation underwent thorough ocular examination that included vision and refraction, slit lamp bio-microscopy, intraocular pressure measurement by Goldmann's applanation tonometry mounted on a Haag Streit slit lamp, gonioscopy with Posner 4 mirror hand held indirect gonioscope and dilated fundus examination with +90 D lens. Indirect ophthalmoscopy was done in cases of advanced cataract resulting in hazy media.

Slit lamp examination included detailed anterior segment evaluation. PEX was recognized by the presence of typical white flakes or fibrillo -granular material at the margins of pupil in an un- dilated state and/or on anterior lens capsule after dilatation or on the trabecular meshwork on gonioscopy. The single tonometer used for the study, was calibrated weekly as part of the regular maintenance protocol of the department. Ultrasound pachymetry (Pocket 2, Quantel Medical, France) was done for all the patients included in the study. After anaesthetizing the cornea with proparacaine hydrochloride 0.5% eye drops, tip of the hand held pachymeter probe was placed perpendicularly on the cornea and centered over the undilated pupil and five measurements were taken. The Mean of five central corneal thickness readings was used for analysis. Gonioscopy was done to examine the status of the angle and grade it according to the Shaffer's grading. Indentation gonioscopy was performed wherever necessary. An occludable angle was diagnosed if the pigmented trabecular meshwork was not visible in more than 180° of the angles in dim illumination. The presence of pseudoexfoliative material or pigmentation in the angles were noted. Detailed fundus examination included changes in the optic disc, cup-disc ratio, width of the neuro- retinal rim, position of vessels and state of macula. Visual field assessment was performed using Humphrey's Field Analyzer (30-2 SITA standard, Carl Zeiss Meditec). Ultrasound B scan was done in selected patients. The normal subjects underwent IOP and CCT measurement.

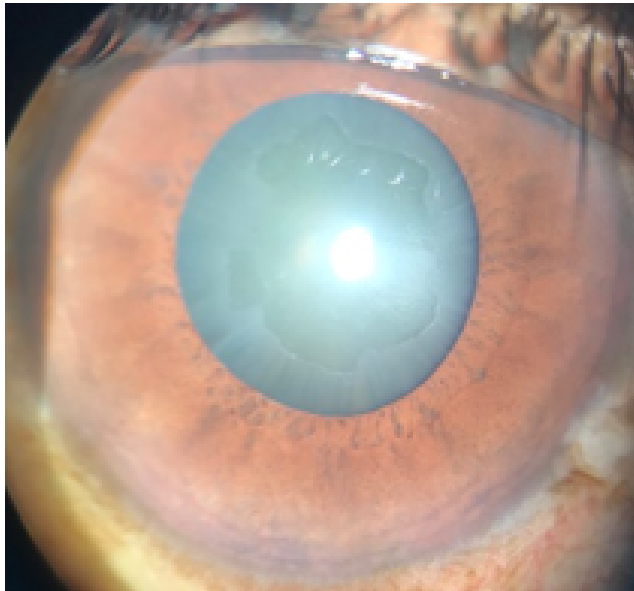
PEX was defined by the presence of typical pseudoexfoliative material, IOP less than 21 mmHg with no sign of glaucomatous optic nerve damage on fundus and/or visual field examination. PXG was diagnosed if the patient along with attributes of P EX had IOP  $\geq$  21 mmHg in either eyes with optic disc changes (vertical cup to disc [C/D] ratio  $>0.6$  or C/D asymmetry  $>0.2$  between the eyes, focal notching, localized nerve fiber layer defects or splinter hemorrhage) with compatible visual field defects.

### 2.3. Statistical analysis

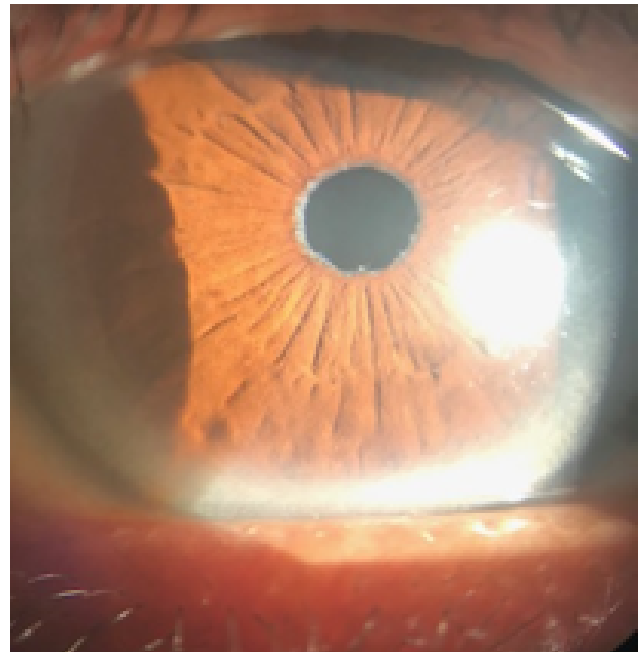
The continuous variables of the study subjects were described in terms of means and interpreted by ANOVA in respect of more than two groups. In respect of two groups, the independent " t " test was applied for interpretations. The categorical variables were described in terms of percentages and interpreted by  $\chi^2$  (Chi-square) test. The above statistical analysis and interpretation was done by IBM SPSS statistics -20. A probability level of p - value less than or equal to 0.05 ( $P \leq 0.05$ ) w as considered as statistically significant.

### 3. Results

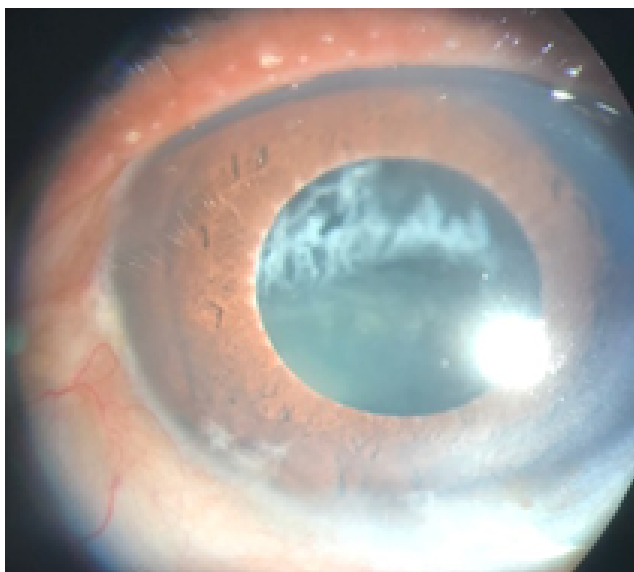
The mean age of the PEX group was  $67.5 \pm 7.7$  years and PXG group mean age was  $68.8 \pm 8.2$  years. The mean difference between the two groups was not statistically significant ( $P > 0.05$ ). The mean age of total subjects was  $68.2 \pm 7.9$  years.



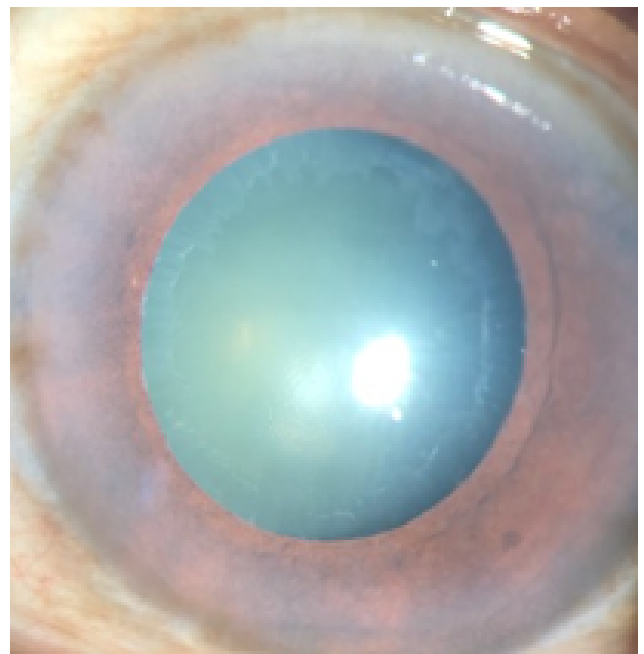
**Fig. 1:** Deposition of PEX material on Anterior lens capsule.



**Fig. 3:** Deposition of PEX material at



**Fig. 2:** Deposition of PEX material on lens Zonules leading to inferior subluxation



**Fig. 4:** Deposition of PEX material on anterior

**Table 1:** Age distribution of both groups:

Age group (years)	PEX		PXG		Total	
	No	%	No	%	No	%
50-59	10	7.7	8	6.2	18	13.8
60-69	25	19.2	29	22.3	54	41.5
70-79	25	19.2	20	15.4	45	34.6
80+	5	3.8	8	6.2	13	10.0
Total	65	50.0	65	50.0	130	100.0
Mean $\pm$ SD	67.5 $\pm$ 7.7		68.8 $\pm$ 8.2		68.2 $\pm$ 7.9 Range=51-86 years	
Significance	t=0.917, df 128 and P=0.361					

**Table 2:** Gender distribution:

Gender	PEX		PXG		Total		Results
	No	%	No	%	No	%	
Male	41	31.5	47	36.2	88	67.7	$\chi^2 = 1.266$ df=1 P=0.260
Female	24	18.5	18	13.8	42	32.3	
Total	65	50.0	65	50.0	130	100.0	

The proportion of males was higher than females in both PEX and PXG. The male to female ratio was 1.7:1 in PEX and 2.6:1 in PXG group.

**Table 3:** Laterality of eyes in PEX and PXG groups.

Laterality	PEX		PXG		Total		Results
	No	%	No	%	No	%	
Both	57	43.8	55	42.3	112	86.2	$\chi^2 = 0.702$ df=2 P=0.704
Right	2	1.5	4	3.1	6	4.6	
Left	6	4.6	6	4.6	12	9.2	
Total	65	50.0	65	50.0	130	100.0	

Most of the patients had bilateral presentation in both the groups.

**Table 4:** (a):Pseudoexfoliative material deposition in PEX, PXG of right eyes:

Eye structure	PEX		PXG	
	No	%	No	%
Endothelium	-	-	3	4%
Pupil	58	89%	58	89%
Lens	47	72%	54	83%
Angle	5	7%	5	7%
Zonules	-	-	1	1.5%

4(b): Pseudoexfoliative material deposition in PEX, PXG of left eyes:

Eye structure	PEX		PXG	
	No	%	No	%
Endothelium	-	-	5	7%
Pupil	60	92%	60	92%
Lens	43	66%	54	80%
Angle	6	9%	7	10%
Zonules	-	-	1	1.5%

Pseudoexfoliative material was most commonly seen at the pupillary border in both PEX and PXG

**Table 5:** (a): Gonioscopic angle grading for PEX, PXG of Right Eyes:

Right eyes	PEX		PXG		Total		Results
	No	%	No	%	No	%	
Closed	3	2.3	12	9.2	15	11.5	$\chi^2 = 6.469$ df=2 P=0.039
Occludable	3	2.3	4	3.1	7	5.4	
Open	59	45.4	49	37.7	108	83.1	
Total	65	50.0	65	50.0	130	100.0	

Sixteen patients in the pseudoexfoliative glaucoma group had narrow angles compared to 6 in pseudoexfoliation syndrome. The relationship was statistically significant ( $P < 0.05$ ).

**5(b):** Gonioscopy angle grading for PEX, PXG of left eyes:

Left eyes	PEX		PXG		Total		Results
	No	%	No	%	No	%	
Closed	2	1.5	14	10.8	16	12.3	$\chi^2 = 10.750$ df=2 P=0.005
Occludable	2	1.5	3	2.3	5	3.8	
Open	61	46.9	48	36.9	109	83.8	
Total	65	50.0	65	50.0	130	100.0	

Number of eyes with narrow angles was higher in PXG than PEX group. The relationship was statistically significant ( $P < 0.05$ ).

**Table 6:** (a) : IOP at the time of presentation of PEX, PXG for RE:

IOP	PEX		PXG		Total		Results
	No	%	No	%	No	%	
<10	5	3.8	0	0.0	5	3.8	$\chi^2 = 122.239$ df=2 P<0.001
10-21	60	46.2	0	0.0	60	46.2	
>21	-	-	65	50.0	65	50.0	
Total	65	50.0	65	50.0	130	100.0	

Table-6(b): IOP at the time of presentation of PEX, PXG for the LE:

IOP	PEX		PXG		Total		Results
	No	%	No	%	No	%	
<10	6	4.6	1	0.8	7	5.4	$\chi^2 = 45.349$ df=2 P<0.001
10-21	59	45.4	29	22.3	87	66.9	
>21	-	-	35	26.9	36	27.7	
Total	65	50.0	65	50.0	130	100.0	

Most of the patients in PXG group presented with high IOP. IOP of majority of the patients in PEX was between 10-21 mmHg.

**Table 7:** Comparison of CCT between PEX, PXG and normal:

Eyes	Groups	Mean	SD	"F"	df	Significance	Post Hoc Comparison
Right Eyes	1.PEX	519.4	31.6	8.187	2,192	P<0.001	1 and 2 not differed significantly. Both differed significantly with 3.
	2.PXG	512.5	31.0				
	3.Normal	534.4	31.9				
Left Eyes	1.PEX	503.7	94.8	4.455	2,192	P=0.013	1 and 2 not differed significantly. 1&3 differed. 2&3 not differed.
	2.PXG	516.1	30.8				
	3.Normal	534.7	27.3				

The above analysis and interpretations revealed that in respect of right eyes, the difference between mean CCT of PEX and PXG was not statistically significantly ( $P > 0.05$ ) but both significantly differed with normal eyes ( $P < 0.001$ ). In respect of left eyes, CCT of PEX significantly differed with both PXG and normal.

**Table 8:** CCT of Total eyes of PEX, PXG and Normal eyes.

Eyes	Groups	Mean	SD	"F"	df	Significance	Post Hoc Comparison
Both Eyes	1.PEX	511.5	70.6	8.992	2,387	P<0.001	1&2 not differed significantly. Both differed significantly with 3.
	2.PXG	514.3	30.9				
	3.Normal	534.5	29.8				

**Table 9:** (a) : CD Ratio seen in PEX, PXG for the RE:

CD Ratio	PEX		PXG		Total		Results
	No	%	No	%	No	%	
≤ 0.3	29	22.3	-	-	29	22.3	$\chi^2 = 46.286$ df=2 P<0.001
0.4-0.6	33	25.4	24	18.5	57	43.9	
> 0.6	3	2.3	41	31.5	39	33.8	
Total	65	50.0	65	50.0	130	100.0	

In the PEX group CDR 0.4-0.6 was seen in 33 patients. In the PXG subjects, the CDR >0.6 was seen in majority, i.e. 39 of the patients.

9(b): CD Ratio of PEX, PXG for the LE:

CD Ratio	PEX		PXG		Total		Results
	No	%	No	%	No	%	
≤ 0.3	34	26.2	-	-	34	26.2	$\chi^2 = 57.375$ df=2 P<0.001
0.4-0.6	31	23.8	15	11.5	46	35.3	
> 0.6	-	-	50	38.5	42	38.5	
Total	65	50.0	65	50.0	130	100.0	

Similar to right eye, C/D ratio was less than 0.3 for majority of the patients in PEX and more than 0.6 in PXG.

**Table 10:** Systemic association seen in PEX, PXG.

Systemic	PEX		PXG		Total		Results
	No	%	No	%	No	%	
Asthma	0	0.0	2	1.5	2	1.5	$\chi^2 = 6.464$ df=8 P=0.595
DM	6	4.6	3	2.3	9	6.9	
DM, HTN	6	4.6	7	5.4	13	10.0	
HTN	12	9.2	13	10.0	25	19.2	
HTN, IHD	1	0.8	0	0.0	1	0.8	
HTN, thyroid	1	0.8	0	0.0	1	0.8	
IHD	1	0.8	2	1.5	3	2.3	
TB	0	0.0	1	0.8	1	0.8	
Nil	38	29.2	37	28.5	75	57.7	
Total	65	50.0	65	50.0	130	100.0	

Hypertension alone or with other systemic diseases was the major systemic association found in 15.4% of the subjects in both the groups respectively.

**Table 11:** Treatment options in PEX and PXG

Treatment	PEX		PXG		Total		Results
	No	%	No	%	No	%	
Cataract surgery	43	33.1	4	3.1	47	36.2	$\chi^2 = 6.464$ df=8 P=0.595
Cataract, VR	1	0.8	0	0.0	1	0.8	
Internal procedures	3	2.3	2	1.5	5	3.8	
Medical	1	0.8	38	29.2	39	30.0	
Observation	9	6.9	-	-	9	6.9	
Refraction	4	3.0	0	0.0	4	3.0	
Combined cataract+ trab surgery	-	-	21	16.2	21	16.2	
VR opinion	4	3.1	0	0.0	4	3.1	
Total	65	50.0	65	50.0	130	100.0	

Majority of the patients had significant cataract at the time of presentation. 33.1% of PEX cases were advised cataract surgery whereas medical management was first advised for 29.2% patients in PXG group.

#### 4. Discussion

The prevalence of Pseudoexfoliation varies considerably among population where the rate can be as low as 0% in Eskimos,<sup>23</sup> and as high as 38% in Navajo Indians.<sup>24</sup>

Thus, the world - wide prevalence of Pseudoexfoliation or Glaucoma capsulare makes it critical for ophthalmologists to be familiar with the full clinical spectrum of the disease.<sup>2</sup>

The mean age of patients in our study was 68.2 years. Pseudoexfoliation is the disease of senility. The prevalence of PEX increases significantly with age. In the present study, 84% of patients in PEX and 86% of the patients in PXG group were more than 60 years of age. The youngest patient in our study was 51 and the oldest was 86 years old. This is in accordance to many other published studies such as the one done by Yeshigeta et al (68.8%),<sup>25</sup> Jawad et al<sup>26</sup> (63%) and Pranathi et al<sup>27</sup> (100%).

There are conflicting results regarding gender differences in the published reports. The male: female ratio in PEX was 1.7:1 and 2.6:1 in PXG group. Thus, male preponderance was noted in our study similar to the studies done by McCarty and Taylor,<sup>28</sup> Alia R Sufi,<sup>29</sup> Jawad et al<sup>26</sup> and Naseem et al.<sup>30</sup> Most of the males compared to females in our set up, being farmers are more exposed to ultraviolet radiation which may explain the higher incidence in males. This supports the association between environmental factors (possibly solar radiation, UV exposure) and PEX as documented by other studies.<sup>29,31</sup>

Some studies have reported higher incidence of unilateral cases while others bilateral. Most of the patients in our study in both PEX (43.8%) and PXG(42.3%) group had bilateral presentation that is comparable to the study done by Tiliskew et al.<sup>32</sup> One-third to half of the cases of exfoliation are unilateral at detection but 14-43% of these cases become bilateral over 5-10 years.<sup>33</sup> So, careful examination of both eyes at each visit is required.

In our study the most common site of PEX material deposition was at the pupillary margin followed by anterior lens capsule in both PEX (90%, 69%) and PXG (90%, 81.5%) group. This was well in accordance to other published reports such as the one by Sufi et al<sup>34</sup> and Yeshigeta et al.<sup>35</sup>

Though in both PEX (60 cases) and PXG (49 cases) open angle was seen in majority, cases with narrow angle were higher in PXG group which was statistically significant. A study of PEX in Chinese population by Young et al showed that 18 % of all eyes had narrow angles (defined as grade 0 to 2 by Shaffer grading)<sup>36</sup> Although nearly all eyes with PEX or PXG have open angles, approximately 9-18% of eyes can have occludable angles and patients may develop an acute attack of angle closure glaucoma. This may be attributed to zonular laxity leading to anterior displacement of the iris-lens diaphragm.

IOP at the time of presentation was less than 21 mmHg in the PEX group whereas it was more than 21 mmHg in either of the eyes in PXG group. It is quite accepted fact that compared to primary open angle glaucoma, patients with PXG have higher IOP at presentation with greater diurnal fluctuations and marked spikes that likely cause more severe optic neuropathy.<sup>37</sup>

A single IOP measurement is many times is not enough to assess the real IOP in such cases. This was one limitation in our study, we could not perform DVT (diurnal variation of tension) for all the patients.

Results published in the literature have varied with respect to CCT in pseudoexfoliative eyes. To name a few, studies done by Arnarsson et al,<sup>16</sup> Rufer et al<sup>38</sup> and Detorakis et al<sup>39</sup> showed similar CCT values in PEX, PXG and normal subjects. Studies done by Gorezis et al,<sup>40</sup> Aghaian et al,<sup>41</sup> Bechmann et al<sup>42</sup> showed thinner CCT in PXG and study by Ozcura et al<sup>43</sup> showed thinner CCT in PEX. In our study, in both the eyes, CCT was thinner in both PEX and PXG group when compared with age matched normal eyes and it was statistically significant but CCT in PEX and PXG did not differ significantly in the right eyes. Thin CCT is itself an independent risk factor for development of glaucoma. So, cases of PEX with thin cornea and IOP in higher teens as measured by GAT can be missed and can hamper early diagnosis and treatment of PXG.

Most of the patients in the PEX group (31 cases) had cup-disc ratio between 0.3-0.5

Whereas in PXG group majority (46 cases) had C/D ratio more than 0.6. Eighteen of the right eyes and 12 of the left eyes had advanced C/D ratio of 0.9 in the PXG group. The patients with high cup disc ratio in the PEX group had no focal thinning or visual field changes.

According to the Blue Mountains Eye Study, subjects with PEX in either eyes had a two- to threefold increased risk while eyes with bilateral PEX had fivefold increased risk for glaucoma even though it was often associated with only modest increase in intraocular pressure. proving a strong association between PXF and glaucoma.<sup>44</sup> In fact, it is an independent risk factor for development of glaucoma. The cumulative risk for PXG development in eyes with manifest PEX but without IOP elevation is approximately 30% in 10 years and most of these cases convert within first 5 years.<sup>45</sup> Needless to say, how important it is to follow up such patients regularly.

Another limitation of our study was that we were not able to document reliable visual fields in many of our patients who presented to us with visually significant cataract. The visual fields of such patients were repeated after the surgery.

Most of the patients had significant cataract at the time of presentation in PEX group (44 cases) and were advised simple cataract surgery. Patients with moderate glaucoma (37 patients) were started on medical treatment

starting with single eye-drop in 20 patients whereas patients with advanced disc changes (21 cases) were advised combined procedure of cataract extraction and trabeculectomy considering poor economic status and compliance of the patient.

In 6 of the patients in PEX group and 3 patients in PXG, inferior subluxation of cataractous lens without previous history of trauma was observed. This was due to deposition of PEX material leading to zonular weakness.

Also, in 7% of the patients in PEX there was co-existing Branch retinal vein occlusion and 15.5 % patients of PEX and PXG respectively were hypertensive. In a large population study like the Australian Blue Mountains Eye Study, PEX was significantly associated with history of hypertension, angina, or both.<sup>45</sup> Similar association has been established in various other studies. PEX is also a likely independent risk factor more for CRVO than BRVO.<sup>46</sup>

## 5. Conclusion

We conclude from our study that prevalence of PEX and PXG increases with age, is seen more commonly in males. CCT of both PEX and PXG was significantly thinner than normal subjects. Pseudoexfoliation and thinner CCT both being independent risk factors for glaucoma results into more severe optic neuropathy. So timely diagnosis, early treatment and frequent follow-up is the key to manage and prevent appreciable irreversible visual damage.

## 6. Source of Funding

None.

## 7. Conflict of Interest

None.

## References

- Lindberg JG. Clinical investigations on depigmentation of the pupillary border and translucency of the iris in cases of senile cataract and in normal eyes in elderly persons. *Acta Ophthalmol Suppl.* 1989;190:1–96.
- R R. Schlitzer-Schrehardt U. Exfoliation syndrome. *Survey Ophthalmol.* 2001;45(4):265–315.
- Schrehardt UM, Koca MR, Naumann G, Syndrome E. Ocular manifestation of a systemic disorder? *Arch Ophthalmol.* 1992;110(12):1752–1756.
- Naumann G, Schlötzer-Schrehardt U. Ocular and systemic exfoliation syndrome. *Am J Ophthalmol.* 2006;141(5):921–937.
- Sood NN. Prevalence of pseudoexfoliation of the lens capsule in India. *Acta Ophthalmol (Copenh).* 1968;46:211–214.
- Krishnadas R, Nirmalan PK, Ramakrishnan R, Thulasiraj RD, Katz J, et al. Pseudoexfoliation in a rural population of southern India: the Aravind Comprehensive Eye Survey. *Am J Ophthalmol.* 2003;135(6):830–837.
- Skuta GL, Parrish RK, Hodapp E, Forster RK, Rockwood EJ. Zonular dialysis during extra capsular cataract extraction in pseudoexfoliation syndrome. *Arch Ophthalmol.* 1987;105:632–634.
- Naumann G. The Erlanger Augenblatter- Group. Exfoliation syndrome as a risk factor for vitreous loss in extra capsular cataract surgery. *Acta Ophthalmol.* 1988;84:129–131.
- R R. Exfoliation syndrome-the most common identifiable cause of open-angle glaucoma. *J Glaucoma.* 1994;3:176–177.
- Hiller R, Sperduto RD, Krueger DE. Pseudoexfoliation, intraocular pressure, and senile lens changes in a population-based survey. *Arch Ophthalmol.* 1982;100:1080–1082.
- R R. Exfoliation Syndrome and occludable angles. *Trans Am Ophthalmol Soc.* 1994;92:845–944.
- Wessels IF, Oh Y. Tonometer utilization, accuracy, and calibration under field conditions. *Arch Ophthalmol.* 1990;108:1709–712.
- Ehlers N, Bramsen T, Sperling S. Applanation tonometry and central corneal thickness. *Acta Ophthalmol.* 1975;53:34–43.
- Whitacre MM, Stein RA, Hassanein K. The effect of corneal thickness on applanation tonometry. *Am J Ophthalmol.* 1993;115:592–596.
- Kohlhaas M, Boehm AG, Spoerl. Effect of central corneal thickness, corneal curvature, and axial length on applanation tonometry. *Arch Ophthalmol.* 2006;124:471–476.
- Arnarsson A, Damji KF, Sverrisson T, Sasaki H, Jonasson F. Pseudoexfoliation in the Reykjavik Eye Study: prevalence and related ophthalmological variables. *Acta Ophthalmol Scand.* 2007;85(8):822–827.
- Hepsen IF, Yagci R, Keskin U. Corneal curvature and central corneal thickness in eyes with pseudoexfoliation syndrome. *Can J Ophthalmol.* 2007;42(5):677–680.
- Detorakis ET, Koukoulas S, Chrisohou F, Konstas AG, Kozobolis VP. Central corneal mechanical sensitivity in pseudoexfoliation syndrome. *Cornea.* 2005;24(6):688–691.
- Gorezis S, G C, Stefanidou M, Moustaklis-Skyrlas K, Skyrlas A, et al. Comparative results of central corneal thickness measurements in primary open-angle glaucoma, pseudoexfoliating glaucoma, and ocular hypertension. *Ophthalmic Surg Lasers Imaging.* 2008;39(1):17–21.
- Inoue K, Okugawa K, Oshika T, Amano S. Morphological study of corneal endothelium and corneal thickness in pseudoexfoliation syndrome. *Jpn J Ophthalmol.* 2003;47(3):235–239.
- Puska P, Vasara K, Harju M, Setälä K. Corneal thickness and corneal endothelium in normotensive subjects with unilateral exfoliation syndrome. *Graefes Arch Clin Exp Ophthalmol.* 2000;238(8):659–663.
- Stefanidou M, Kalogeropoulos C, Razis N, Psilas K. The cornea in exfoliation syndrome. *Doc Ophthalmol.* 1992;80(4):329–333.
- Forsius H. Prevalence of pseudoexfoliation of the lens in Finns, Lapps, Icelanders, Eskimos and Russians. *Trans Ophthalmol Soc UK.* 1979;99:296–298.
- Faulkner HW. Pseudoexfoliation of the lens among Navajo Indians. *Am J Ophthalmol.* 1971;72:206–207.
- Yeshigeta G, Yenariamwork T. Clinical Characteristics of Cataract Patients with Pseudoexfoliation Syndrome at Jimma University Specialized Hospital, South West Ethiopia. *Ethiop J Health Sci.* 2012;22(1):1–6.
- Jawad M, Nadeem AU, Khan AU, Aftab M. Complications of cataract surgery in patients with pseudoexfoliation syndrome. *J Ayub Med Coll Abbottabad.* 2009;21:33–36.
- Pranathi K, Magdum RM, Maheshgauri R. A study of complications during cataract surgery in patients with pseudoexfoliation syndrome. *J Clin Ophthalmol Res.* 2014;2(1):7–11.
- Mccarty CA, Hr T. Pseudoexfoliation syndrome in Australian adults. *Am J Ophthalmol.* 2000;129:629–633.
- Sufi AR, Mufti AA, Nazir N, Qureshi T, Ramzan R. Prevalence of pseudoexfoliation syndrome in patients scheduled for cataract surgery in eye camps in Kashmir. *J Clin Ophthalmol Res.* 2014;2:137–139.
- Naseem A, Khan S, Khan MN. Cataract Surgery in Patients with Pseudoexfoliation. *Pak J Ophthalmol.* 2007;23(3):155–160.
- Taylor HR. The environment and the lens. *Br J Ophthalmol.* 1980;64:303–310.
- Tilikew T, Kefyalew R. Prevalence of pseudoexfoliation in Ethiopian patients scheduled for cataract surgery. *Acta Ophthalmol Scand.* 2004;82:254–258.



33. Henry JC. Long-term follow-up of pseudoexfoliation and the development of elevated intraocular pressure. *Ophthalmol.* 1987;94.
34. Sufi AR, Singh T, Mufti AA. Outcome of Phacoemulsification in patients with and without Pseudoexfoliation syndrome in Kashmir. *BMC Ophthalmol.* 2012;12:1471–2415.
35. Yeshigeta G, Yenariamwork T. Clinical Characteristics of Cataract Patients with Pseudoexfoliation Syndrome at Jimma University Specialized Hospital, South West Ethiopia. *Ethiop J Health Sci.* 2012;22(1):1–6.
36. Young WWT, Tang DSC, Lam DSC, Young AL. The prevalence of pseudoexfoliation syndrome in Chinese population. *Br J Ophthalmol.* 2004;88:193–195.
37. Essentials in Ophthalmology. Springer Verlag ; 2004.. p. 157–76.
38. Detorakis ET, Koukoula S, Chrisohou F, Konstas AG, Kozobolis VP. Central corneal mechanical sensitivity in pseudoexfoliation syndrome. *Cornea.* 2005;24(6):688–691.
39. Rüfer F, Westphal S, Erb C. Comparison of central and peripheral corneal thicknesses between normal subjects and patients with primary open angle glaucoma, normal tension glaucoma and pseudoexfoliation glaucoma. *Klin Monatsbl Augenheilkd.* 2007;224(8):636–640.
40. Gorezis S, Christos G, Stefaniotou M, Moustaklis K, Skyrilas A, et al. Comparative results of central corneal thickness measurements in primary open-angle glaucoma, pseudoexfoliation glaucoma, and ocular hypertension. *Ophthalmic Surg Lasers Imaging.* 2008;39(1):17–21.
41. Aghaian E, Choe JE, Lin S, Stamper RL. Central corneal thickness of Caucasians, Chinese, Hispanics, Filipinos, African Americans, and Japanese in a glaucoma clinic. *Ophthalmol.* 2004;111(12):2211–2219.
42. Bechmann M, Thiel MJ, Roesen B, Ullrich S, Ulbig MW, et al. Central corneal thickness determined with optical coherence tomography in various types of glaucoma. *Br J Ophthalmol.* 2000;84(11):1233–1237.
43. Ozcura F, Aydin S, Dayanir V. Central corneal thickness and corneal curvature in pseudoexfoliation syndrome with and without glaucoma. *J Glaucoma.* 2011;20(7):410–413.
44. Mitchell P, Wang JJ, Hourihan F. The relationship between glaucoma and pseudoexfoliation: The Blue Mountains Eye Study. *Arch Ophthalmol.* 1999;117:1319–1324.
45. Tarkkanen A, Kivela T. Cumulative incidence of converting from clinically unilateral to bilateral exfoliation syndrome. *J Glaucoma.* 2004;13:181–184.
46. Ali S, Sevgi T, Murat F, Süleyman K, Ergin M. Pseudoexfoliation and glaucoma in eyes with retinal vein occlusion. *Int Ophthalmol.* 1999;23:75–78. Available from: [10.1023/A:1026557029227](https://doi.org/10.1023/A:1026557029227).

### Author biography

**Nishat Sultana** Professor

**Shalini** Fellow

**Cite this article:** Sultana N, Shalini . Evaluation of Central Corneal Thickness and clinical ocular profile of Patients presenting with Pseudoexfoliation at a tertiary care centre. *Indian J Clin Exp Ophthalmol* 2019;5(4):543-551.