



## Original Research Article

## Study of choroidal neovascularization and its outcome after anti-vegf treatment

Richa Gour<sup>1,\*</sup><sup>1</sup>Dept. of Ophthalmology, Gandhi Medical College, Bhopal, Madhya Pradesh, India

## ARTICLE INFO

## Article history:

Received 29-06-2019

Accepted 27-07-2019

Available online 27-11-2019

## Keywords:

Optical coherence tomography (OCT)

Fundus fluorescence angiography

(FFA)

Pronata (PRN).

## ABSTRACT

**Aim:** To evaluate the visual outcome and clinical response in CNVM patient after Anti-VEGF treatment.**Material and Methods:** This prospective observational study was conducted on 38 diagnosed eye of CNVM and its presence was confirmed by FFA. Complete ocular examination was conducted with respect to CNVM. They were followed up post injection (inj.ranibizumab) at day 1,7,1 month and on PRN basis, change in visual acuity and OCT findings was recorded.**Results:** Mean age of study participants were  $62.2 \pm 15.9$ . Majority (63.3%) of the patients were more than 60 years of age. Out of 30 patients 18 were males and 12 were females with M: F ratio 6:4. Difference in visual acuity at pre and post treatment was significant with p value ( $<0.01$ ). Statistically significant difference was found between pre and post treatment macular thickness on OCT (p value  $<0.01$ ).**Conclusion:** Intravitreal ranibizumab injection was beneficial treatment for all type of CNVM administered on PRN basis over 18 month of follow-up achieved stabilization of vision with significant improvement in BCVA and decreased retinal thickness by OCT.© 2019 Published by Innovative Publication. This is an open access article under the CC BY-NC-ND license (<https://creativecommons.org/licenses/by/4.0/>)

## 1. Introduction

The choroidal neovascularisation is a manifestation of the diseases affecting choroid, Bruch's membrane and retinal pigment epithelium (RPE).<sup>1</sup> CNVM may occur as an idiopathic entity or in association with number of pathological conditions like age-related macular degeneration (ARMD),<sup>2</sup> pathologic myopia, trauma, ocular histoplasmosis (POHS),<sup>3</sup> angioid streaks, choroidal tears and in certain inflammatory diseases of choroid and retina. It can cause severe visual loss due to leakage, haemorrhage and scar tissue formation damaging the photoreceptors and the RPE.<sup>4</sup>

Initially the treatment approaches are laser photocoagulation, then approach change to photodynamic therapy with verteporfin, trans-pupillary thermotherapy, sub-macular surgery. Laser photocoagulation is only useful in a small percentage of patients that have well-defined areas of classic CNV. Moreover, recurrences after laser photocoagulation

are common and occur in approximately 50% of patients<sup>5</sup>

Now currently the treatment of choice for CNVM is intravitreal anti-VEGF therapy, anti-VEGF agent have revolutionized the treatment of CNVM.

Ranibizumab is a recombinantly produced, humanized antibody fragment that binds VEGF. It binds to and inhibits all active forms of VEGF-A and their active degradation products. The usual dose is 0.5mg in 0.05ML.<sup>6</sup>

Bevacizumab is a full-length humanized monoclonal antibody against human VEGF. Treatment with BCZ result in lower economic burden to healthcare system as compared to RBZ.

Aflibercept is recombinant solution VEGF receptor protein in which the binding domains of VEGF receptor 1 and 2 are combined with the Fc portion of immunoglobulin G.<sup>7</sup>

The present study is being done to evaluate the clinical profile and types of CNVM and the effectivity and outcome of anti VEGF therapy.

\* Corresponding author.

E-mail address: [richagour52@gmail.com](mailto:richagour52@gmail.com) (R. Gour).

### 1.1. Objectives

1. To evaluate the patients of CNVM with reference to etiological factors.
2. To evaluate the visual outcome and clinical response in CNVM patient after Anti-VEGF treatment.

## 2. Material and Methods

The present study was carried out as facility based cross sectional study in Department of Ophthalmology, Gandhi Medical College and associated Hamidia Hospital, Bhopal M.P. All the patients attending eye OPD and detected as choroidal neovascularization (CNVM) based on regular fundus examination. Study was undertaken from 1st March 2017 to 31st August 2018 that is for a period of eighteen months.

The inclusion criteria was all cases of CNVM diagnosed in eye OPD of Hamidia Hospital and giving consent for the study; patients referred from other departments having CNVM and patients referred from other special ophthalmic clinics with diagnosis of CNVM. The exclusion criteria was patients with other systemic diseases affecting retina; other retinal/ macular pathologies and previously treated macular disorders. All the patients diagnosed as CNVM, fulfilling inclusion criteria were selected using purposive sampling. After obtaining informed consent, all participants included in the study were interviewed and information was recorded on a pre-designed, pre-tested and semi-structured questionnaire. The questionnaire included socio-demographic variables and details regarding relevant history and thorough ocular examination.

Patients were explained regarding the seriousness of disease, nature of treatment that they would be offered, the potential risks, benefits, adverse effects, alternative treatment options and possible treatment outcomes. Once they consented for treatment, affected eye was dilated using topical mydriatic drug and then shifted to operation theatre. After taking all aseptic precautions, injection Ranibizumab 0.5 mg was given intravitreally at 4.0 mm from the limbus in phakic eye and 3.5 mm in pseudophakic eye under topical anesthesia. The patients were then instructed to take an antibiotic eye drop for a week. A repeat injection was given to all the patients after one month of first injection using aseptic precautions under topical anesthesia, followed by a course of topical antibiotic for a week. All the participants were followed up next day to look for site discomfort, transient elevation of intraocular pressure, inflammation, redness or any other discomfort to the patient and then after 7 days, 1 month and on PRN basis to look for response to treatment which mainly focussed on visual acuity. PRN is reference to dosage of prescribed medication that is not scheduled. The PRN regimen showed good visual result but requires monthly monitoring.

Change in BCVA by more than or less than 2 lines on Snellen chart was considered as improvement or worsening, respectively. Patients with change in visual acuity of less than 2 Snellen lines were considered to be stable.

### 2.1. Retreatment

The assessment of treatment response and decision of when to stop treatment was based on multiple factors, including visual acuity, symptomatology and clinical assessment. Patients were given retreatment based on visual acuity “treat to stable vision”

### 2.2. Statistical analysis

Data was entered into MS excel 2007, analysis was done with the help of Epi-Info software. Frequency and percentage were calculated & statistical test was applied wherever applicable;  $P < 0.05$  was taken as statically significant.

## 3. Observation and Results

Mean age of study participants is  $62.2 \pm 15.9$ . Majority (63.3%) of the patients were more than 60 years of age. Only 13.3% were less than 40 years of age. Out of 30 cases, 60% were male & 40% were female.

It was observed that the mean age in the ARMD group at Presentation was  $68 \pm 10.13$ , pathological myopia was  $48.57 \pm 10.28$ , Trauma was 57.00 and idiopathic CNVM was  $32 \pm 4.23$ . This shows that ARMD predominantly affects older  $68 \pm 10.13$  people whereas like pathological myopia, Idiopathic CNVM are seen in younger age groups.

Most common presenting complaints was gradual diminution of vision in all etiological groups followed by metamorphopsia. In participants with pathological myopia, 72% participants complained of gradual diminution of vision and metamorphopsia. Amongst participants with ARMD, 95% participants complained of gradual diminution of vision followed by metamorphopsia in 75% participants. Mode of presentation in patient with trauma was metamorphopsia and in idiopathic CNVM, it was gradual diminution of vision in 100% and metamorphopsia in 50% participants.

As the difference in visual acuity at pre and post treatment is  $p < 0.01$  it is highly significant ( $t = 5.65, p$  - value = 0.01). Pre treatment mean was  $1.29 \pm 0.488$  and post treatment mean was  $1.04 \pm 0.471$  with std. deviation  $0.26 \pm 0.28$  at CI 0.16-0.35, test of significance was found to be highly significant ( $p = 0.01$ ).

Improvement in visual acuity was seen in eyes of pathological myopia ( $p = 0.001$ ) and ARMD ( $p = 0.001$ ).

There was only one eye with trauma thus statistical test could not be applied. While the Idiopathic CNVM cases showed improvement which was statistically significant ( $p = 0.02$ ).

**Table 1:** Distribution according to sociodemographic variables

Sociodemographic variables		Frequency	Percent
Age group (years)	21-40	4	13.3%
	41-60	7	23.3%
	>60	19	63.3%
Gender	Male	18	60%
	Female	12	40%

**Table 2:** Etiology and the mean age of the patients

Etiological factors	No. (30)	Mean age	SD
Pathological Myopia	7	48.57	10.289
ARMD	20	68.00	10.137
Trauma	1	57.00	
Idiopathic CNVM	2	32.00	4.243

**Table 3:** Visual complaints in different etiological groups

Etiological factors	Gradual DOV	%	Sudden DOV	%	Metamorphopsia	%	Central scotoma	%	Paracentral scotoma	%
Pathological myopia	5	72%	2	28%	5	72%	2	28%	0	0%
ARMD	19	95%	1	5%	15	75%	3	15%	2	10%
Trauma	0	0	0	0	1	100%	0	0%	0	0%
Idiopathic CNVM	2	100%	0	0	1	50%	0	0%	0	0%

**Table 4:** Comparison of BCVA pre and Post treatment

Log MAR	Mean	SD	Standard error
Pre t/t	1.29	0.488	0.08
Post t/t	1.04	0.471	0.08
Paired t test			
test Mean	Std Deviation	SE	95% Confidence Interval
0.26	0.28	0.05	Lower limit 0.16 Upper limit 0.35
t	Df	P value	5.65 37 <0.01

**Table 5:** Distribution of Mean visual improvement in different etiological group

Etiological factors	Pre t/t mean logmar	Post t/t logmar final followup	t	P value
Pathological Myopia	1.5±0.5	1.12±0.45	4.3	0.001 HS
ARMD	1.3±0.5	1.08±0.5	4.8	<0.001HS
Trauma	0.30	0.30	NA	NA
Idiopathic CNVM	1.09±0.12	0.25±0.7	23.9	0.02 S

**Table 6:** Comparison of pre and post t/t CRT-OCT

OCT	Mean	SD				
Pre t/t	455.9	78.9				
Post t/ PRN	335.13	97.5				
Paired t test (OCT pre t/ t and final follow-up)						
Mean	Std Deviation	SE	95% Confidence Interval	t	df	P value
120.82	99.09	15.86	Lower limit 88.69 Upper limit 152.94	7.61	38	<0.01

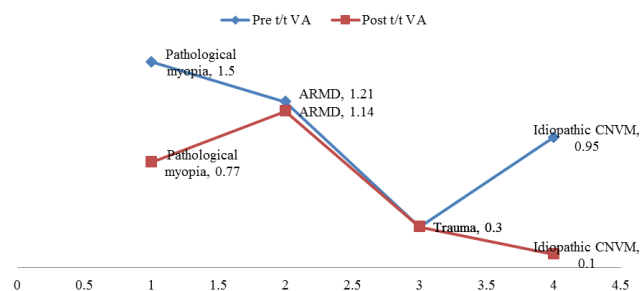


Fig. 1:

As the difference in OCT at pre and post treatment is  $p < 0.01$  it is highly significant ( $t = 7.66$ ,  $p$ -value = 0.01). Pre treatment mean was 455.9 and post treatment mean was 335.13. Paired t test was applied to compare the means of pre treatment and post treatment mean was 120.82 (88.69–152.94 CI), test of significance was found to be highly significant ( $p = 0.01$ ).

#### 4. Discussion

In present study, 30 patients of CNVM were included in the age range of 20 to 85 years. Mean age of study participants was  $62.2 \pm 15.9$  years. It was observed that the mean age in the ARMD group at presentation was  $68 \pm 10.13$  years, whereas the mean age in patients with pathological myopia, trauma and idiopathic CNVM was  $48.57 \pm 10.28$  years, 57.00 years and  $32 \pm 4.23$  years respectively. This shows that ARMD predominantly affects older  $68 \pm 10.13$  people where as other etiologies like pathological myopia, Idiopathic CNVM are seen in younger age groups.

It was estimated that 8 million people will be affected with AMD worldwide by the year 2020. Robinal, et al (2004) reported the prevalence of early and late AMD at 2.7% (95% CI, 2.2 – 3.2) and 0.6% (95% CI, 0.4 – 0.8), respectively from a population-based study from rural India.<sup>8</sup>

Majority (60%) of patients were male in the present study. With reference to etiological groups female patients were more than male in pathological myopia whereas in CNVM due to ARMD, Trauma and Idiopathic CNVM male patients were more than female. Vongphanit J et al (2002) estimated that the prevalence of CNVM among high myopic patients was 4%–11% and there was a 2-fold higher risk among women.<sup>9</sup>

The high proportion of CNVM due to pathological myopia in females can be explained on the basis of study by Kobayashi K et al (2002), which suggested that predominance of myopic CNV in females may be due to oestrogen receptor expression in CNV and the external influence of oestrogen. The male preponderance could be due to behavioural and social aspects in our society causing less reporting of cases of female as compare to male.

In present study 89.7% cases presented with gradual diminution of vision whereas sudden diminution of vision was seen only in 10.2% patients. Metamorphopsia was present in 61%, central scotoma in 53% and paracentral scotoma in 2.5% patients.

Aditya shudhalkar et al (2015) in their study stated that the most common complaint was decreased vision (94.5%), followed by inability to recognize faces (80.42%) and reading disability (78.4%). One-hundred seven patients (26.22%) had metamorphopsia. Only 17 patients (4%) of these were asymptomatic.<sup>10</sup>

In present study, the mean of log-MAR visual acuity at presentation and at final follow up of 6 month with a mean number of visit  $6.9 \pm 1.15$  was calculated and the test of significance (paired t test) showed highly statistical significant difference between the pre-treatment and post-treatment visual acuity ( $p < 0.01$ ). Mean number of injection in present study was  $2.97 \pm 0.59$ .

Similar to log-MAR, the mean of central retinal thickness at presentation and at final follow up was calculated. The difference in central retinal thickness at pre and post treatment was found to be highly significant statistically ( $p < 0.01$ ).

##### 4.1. Pathological myopia

The mean log-MAR in patients with pathological myopia at baseline and at final follow up with a mean of 6.4 visits in the 6-month period was  $1.5 \pm 0.5$  and  $1.12 \pm 0.45$  respectively. The observed difference between the baseline and final visual acuity was found to be highly significant ( $p < 0.01$ ). Similarly, the difference between mean of Central retinal thickness at baseline and final follow up was found to be significant ( $p < 0.01$ ) in present study.

Sindhu S et al (2017) in their study found mean BCVA at baseline was 0.64 log MAR and 0.48 log MAR at 1 year follow up. This difference was found to be statistically significant ( $P = 0.04$ ).<sup>11</sup>

##### 4.2. ARMD

The mean log-MAR in patients with ARMD at baseline and at final follow up with 7.3 mean number of visit in the 6 month period, was  $1.3 \pm 0.5$  and  $1.08 \pm 0.5$  respectively. The observed difference between the baseline and final visual acuity was found to be highly significant ( $p < 0.01$ ). The difference between mean of Central retinal thickness at baseline and final follow up was found to be significant ( $p < 0.01$ ) in this group in present study. The PrONTO (2009) (prospective optical coherence tomography imaging of patients with neovascular AMD treated with intraocular ranibizumab) trial also showed improvement in visual acuity following Ranibizumab injections ( $p = 0.001$ ). The mean number of injections was 9.9. The difference in pre-treatment and post-treatment OCT was also significant

( $p < 0.01$ ) in PrONTO study.<sup>12</sup>

## 5. Conclusion

1. ARMD and pathological myopia were the most commonly associated factors of CNVM in present study.
2. In present study, it was observed that the mean age at presentation of CNVM in patients of pathological myopia was lower as compared to ARMD group.
3. Gradual diminution of vision was the most common presenting complaint followed by metamorphopsia and occult CNVM was the most common type of CNVM in the present study.
4. Following Ranibizumab injections, the improvement in visual acuity at 6 month follow-up as elicited by log-MAR value was found to be statistically significant.
5. No serious drug related ocular or systemic adverse events were identified.

## 6. Source of Funding

None.

## 7. Conflict of Interest

None.

## References

1. Choroidal Neovascular Membranes: Background, Pathophysiology, Epidemiology [Internet]. Background, Pathophysiology, Etiology. ;.
2. Armbrecht, Aspinall, Dhillon. A prospective study of visual function and quality of life following PDT in patients with wet age related macular degeneration [Internet]. Br J Ophthalmol. BMJ Publishing Group Ltd; 2004 . 2004;Internet.
3. Choroidal Neovascular Membranes Clinical Presentation: History, Physical, Causes [Internet]. Background, Pathophysiology, Etiology.

4. Claudio, Costagliola, Ciro, Incorvaia, Carlo, Sheridan, et al. Inflammatory Mediators and Angiogenic Factors in Choroidal Neovascularization: Pathogenetic Interactions and Therapeutic Implications [Internet]. International Scholarly Research Notices. Hindawi; 2010 ;.
5. Potter MJ, Szabo SM. [Internet]. Advances in pediatrics. U.S. National Library of Medicine; 2007 [cited 2018Aug23] ;.
6. Investigative Ophthalmology & Visual Science. The Association for Research in Vision and Ophthalmology;.
7. Dias J, Andrade GCD, Amorimnvoais E, Farah ME, Rodrigues EB. Fusion proteins for treatment of retinal diseases: aflibercept, ziv-aflibercept, and conbercept. *Int J Retina Vitreous*. 2016;Internet.
8. Nirmalan PK, Katz J, Robin A. Prevalence of vitreoretinal disorders in a rural population of Southern India: The Aravind Comprehensive Eye Study. *Arch Ophthalmol*. 2004;122:581–586.
9. Vongphanit J, P M, J WJ. Prevalence and progression of myopic retinopathy in an older population. *Ophthalmol*. 2002;109:704–711.
10. Sudhalkar A, Sethi V, Gogte P, Bondalapati S, Khodani M, et al. Retrospective hospital-based analysis of age-related macular degeneration patterns in India: 5-year follow-up. *Indian J Ophthalmol*. 2015;63(12):899.
11. Sindhu S, Mahesh G, Rajesh B, Giridhar A. Myopic choroidal neovascular membrane: A retrospective study. *Kerala J Ophthalmol*. 2016;28(2):116.
12. Lalwani GA, Fung AE, Michels S, Dubovy SR, Feuer WJ Jr, Puliafito CA et al, An OCT-guided variable-dosing regimen with ranibizumab (Lucentis) in neovascular AMD: two year results of the PrONTO study. Poster presented at: Annual Meeting of the Association for Research in Vision and Ophthalmology; May 7;2009; Fort Lauderdale. ;.

## Author biography

**Richa Gour** Gost Graduate Resident

**Cite this article:** Gour R. Study of choroidal neovascularization and its outcome after anti-vegf treatment. *Indian J Clin Exp Ophthalmol* 2019;5(4):529-533.