



## Original Research Article

## Visual outcomes and complications after Neodymium-doped yttrium aluminium garnet laser capsulotomy in Posterior capsular opacification

Gona Soujanya<sup>1,\*</sup>, Kanthamani. K<sup>1</sup><sup>1</sup>Dept. of Ophthalmology, Sri Devaraj Urs Academy of Health Education and Research, Karnataka, India

## ARTICLE INFO

## Article history:

Received 26-03-2019

Accepted 30-07-2019

Available online 27-11-2019

## Keywords:

capsular opacification

cataract

NdYag laser capsulotomy

## ABSTRACT

**Introduction:** Posterior capsular opacification is the most common delayed complication following cataract surgery. Nd -YAG laser capsulotomy is the gold standard treatment for PCO which is both simple and effective. Though being a non-invasive and simple outpatient procedure, it is not without complications

**Materials and Methods:** 89 patients with PCO who met the inclusion/exclusion criteria were taken up for Nd-YAG laser and followed up on day 1, after 1 week, 1 month and 3 months for visual acuity, IOP and other complications.

**Results:** There is excellent and statistically significant ( $p < 0.001$ ) improvement in visual acuity immediately after the procedure with 90.9% getting a VA of  $\geq 6/18$ . Several complications like IOP rise, iritis are noted which are transient & self resolving. IOL pitting was seen in 5.6% patients. Certain complications like Corneal haze & burns, Retinal detachment, Endophthalmitis and Secondary closure of capsulotomy were not seen in our study.

**Conclusion:** Nd -YAG laser capsulotomy is a safe and effective method of treating PCO.

© 2019 Published by Innovative Publication. This is an open access article under the CC BY-NC-ND license (<https://creativecommons.org/licenses/by/4.0/>)

### 1. Introduction

Cataract dates back to ancient times being the leading cause of preventable blindness worldwide, contributing to 33.4% of all blindness.

The number of people in the age group of >60yrs is shown to increase from 901 million to 1.4 billion in 2030 in the world. Thus the increasing life expectancy will add up the current scenario.<sup>1</sup>

In the modern era of cataract surgery, the lens capsule is left intact to preserve a site for the implantation of the intraocular lens which is the most practised mode of visual rehabilitation, but this posterior capsule may lead to the significant secondary visual loss due to the development of PCO, acting as a substrate for the proliferating remnant epithelial cells.

Due to its multi-factorial causation and pathogenesis, it is difficult to target one specific pathway to alter

its development. Many techniques were advocated to reduce the incidence including surgical techniques, IOL biomaterial, IOL design and pharmacological methods.<sup>2-4</sup> with YAG- capsulotomy rates of upto 1.3%-14%,<sup>5</sup> although nearly 100% opacification occurs in cases of children. The interval between surgery and opacification time ranges from 3 months to 5 years with an average opacification duration being 26 months.<sup>6</sup>

PCO can be treated either with surgical (or) laser capsulotomy, either of them have their own pros & cons. Today Neodymium doped yttrium aluminium garnet (Nd -YAG) laser capsulotomy has become a gold standard approach for treating PCO, due to its ease and effectiveness to improve the dropped visual acuity.<sup>7</sup>

Though being a non-invasive and simple outpatient procedure, it is not without complications. Several complications have been listed in various studies, though majority of them are transient and treatable.<sup>8,9</sup> Hence I have undertaken this study to evaluate the visual outcomes and complications following Nd -YAG laser capsulotomy in

\* Corresponding author.

E-mail address: [gonasoujanya1990@gmail.com](mailto:gonasoujanya1990@gmail.com) (G. Soujanya).

patients with PCO.

## 2. Aims and objectives

To assess the visual acuity in patients undergoing Nd -YAG laser capsulotomy.

To document the complications following ND-YAG capsulotomy over a period of 3months.

## 3. Materials and Methods

On approval from ethical committee, in our Prospective interventional study, 89 cases presenting with posterior capsular opacification to the ophthalmology outpatient department of R.L.Jalappa hospital & research center, Tamaka, Kolar were included from the period of December 2016 to may 2018 . Patients with posterior capsular opacification following cataract extraction with IOL implantation with decreased best corrected visual acuity of two or more Snellens lines ( $\leq 6/12$ ). The patients with any corneal disorders, retinal disorders, trauma, glaucoma, intraocular lens decentration were excluded from the study.

### 3.1. Methodology

All the patients attending the ophthalmology department with PCO were evaluated for any co-existing ocular comorbidities. They were evaluated for visual acuity, IOP, slitlamp assessment, 90D examination, IDO examination.

The procedure was explained to the patient and informed consent was obtained before dilating the patient.

A topical preparation of tropicamide 0.8% with phenylephrine hydrochloride 5% (chlorbutol 0.5 as preservative) was used for achieving mydriasis. After adequate dilation, topical preparation of proparacaine 0.5% was instilled into the conjunctival sac. The patient was made to sit comfortably by adjusting the stool height and chin rest height. The head band was fastened to achieve stability to prevent gross head movements. The patient was explained that he hears a click sound and a bright flash with each shot of laser with which he/she might feel a slight stinging sensation. He/she was told not to move and to maintain the gaze towards the fixation target. An Abraham lens was placed gently for achieving better stability and focus. VISULAS YAG III laser machine manufactured by ZEISS was used for the procedure. Initially the laser beam was properly focussed onto the posterior capsule or slightly behind it and to start with, a minimal laser energy was used i.e 0.8mj- 1mj depending on the thickness of the PCO, increased up to a maximum of 2mj. The initial shots are made along the tension lines and a cruciate pattern of opening was preferred with shots starting in the peripheral part at 12'o clock position gradually moving towards 6'o clock position. Horizontally from 3 ' o clock towards 9'o clock. Any residual tags have to be shot to avoid freely floating fragments. After the procedure, visual acuity and

intraocular pressure is checked and noted after 1 hour.

The patient was advised to use: a) 0.5%Timolol eye drops twice daily for a week, and b) Topical antibiotic & steroid combination medication QID for a week c) Reviewed after 1 day, 1month and 3months to looked carefully for any signs of inflammation like Aqueous flare and cells, Hyphaema, Intraocular pressure rise, Cystoid macular oedema and Retinal detachment. They were evaluated for visual acuity, IOP and observed for complications after 1 hr, 1day, 1month and 3months.

### 3.2. Statistical analysis

Data was entered into Microsoft excel data sheet and was analyzed using SPSS 22 version software. Categorical data was represented in the form of Frequencies and proportions.

Continuous data was represented as mean and standard deviation. Paired t test is the test of significance for paired data such as before and after surgery for quantitative data.

Graphical representation of data : MS Excel and MS word was used to obtain various types of graphs such as bar diagram, Pie diagram.

p value (Probability that the result is true) of  $<0.05$  was considered as statistically significant after assuming all the rules of statistical tests. Statistical software : MS Excel, SPSS version 22 (IBM SPSS Statistics, Somers NY, USA) was used to analyze data.

## 4. Results

A total of 89 patients were included in our study, the majority of patients had Elschnig's pearl type of opacification, i.e, 59.6%. Fibrous type is noted in 28.1% and combined opacification with both the elements of fibrous as well as Elschnig type is noted in 12.4% patients.

Visual acuity improved to 6/6-6/9 in 84.2% patients by the end of three months, 11.2% patients had visual acuity in the range of 6/12-6/18, and 4.49% patients are in the range of 6/24-6/36.

Pre Laser VA in Log MAR was  $0.78 \pm 0.36$  which changed to  $0.14 \pm 0.24$  at Post Laser. There was significant improvement in visual acuity post laser in the study as shown in Table 3.

Rise in IOP is usually transient and subsided within a week in majority of the patients. Persistent elevation in IOP is noted only in 1 patient over a period of 3months as depicted in Graph 1.

In the study as in graph 2, 35.9% patients had IOP rise, 23.6% had iritis, 5.6% had CME, 5.6% had IOL Pitting and none of them had corneal complications, RD, RH, MH, Endophthalmitis and Secondary closure.

## 5. Discussion

In the modern era, with the advances in cataract surgery it has now become a refractive surgery. PCO is a major

**Table 1:** Type of pco among subjects

Type of PCO	Count	%
EP	53	59.6%
EP+FIB	11	12.4%
FIB	25	28.1%

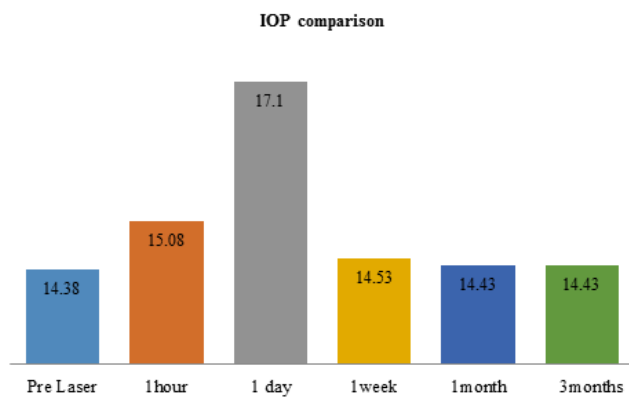
**Table 2:** Showing Visual acuity comparison between Pre Laser and Post Laser

Visual acuity	Visual acuity pre laser.n(%)	VA 1 day post-laser.n(%)	VA 1 week Post-laser.n(%)	VA 1month Post-laser.n(%)	VA 3months post-laser.n(%)
6/6-6/9	0	70(78.6)	72(80.8)	73(82)	75(84.2)
6/12-6/18	25(28)	11(12.3)	9(10.1)	9(10.1)	10(11.2)
6/24-6/36	36(40.4)	8(8.9)	8(8.9)	7(7.86)	4(4.49)
6/60	20(22.47)	0	0	0	0
<6/60	8(8.9)	0	0	0	0

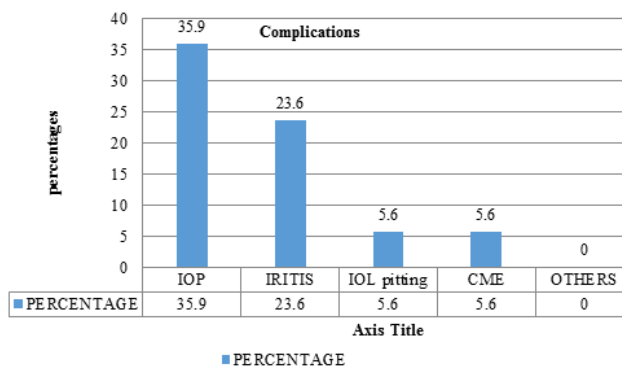
n = number of cases, %= percentage.

**Table 3:** Visual acuity comparison between Pre laser and Post Laser in logMAR.

	Mean	SD	P value
Pre Laser VA	0.78	0.36	
BCVA Post Laser	0.14	0.24	<0.001*



Graph 1: Bar diagram showing IOP comparison between Pre laser and Post Laser after 1 hour, 1 day, 1 Week, 1 Month and 3 months.



Graph 2: Bar diagram showing Complications among subjects

late post-operative complication of cataract surgery which impedes with the result of a successful surgery. With the advent of Nd YAG laser capsulotomy which is a simple, non-invasive outpatient procedure the treatment of PCO is simplified.

In our study, 89 subjects with PCO were included and were treated with Nd -YAG laser capsulotomy in our institute. Our main aim is to note the improvement in visual acuity and study the complications over a 3 month duration.

The average age group of the patients is 57yrs, because of more cataract surgeries being performed in that age group. This is in accordance with the study by Emery et al, in which the average age of the patients developing PCO was 55 years.<sup>10</sup>

In our study 59.5% patients had Elschnig pearl type of PCO, Fibrous type which was seen in 28.1% patients followed by combined type of PCO which accounted to 12.4%.

A major parameter evaluated in our study is visual outcome after capsulotomy. The visual acuity improved immediately to  $\geq 6/18$  in 90.9% of patients. Visual acuity of 6/24 – 6/36 is noted in 8.9 % of patients.

Pre Laser VA was  $0.78 \pm 0.36$  which changed to  $0.14 \pm 0.24$  after 1month of laser. There was a significant improvement in visual acuity post laser in the study. The best corrected visual acuity is better than 6/18 in 92.1% patients. This is in agreement with other studies.

Visual acuity of  $\leq 6/24$  and is seen in 7 patients i.e, 7.86%, but this has improved and visual acuity less than 6/24 is noted only in 4 patients(4.49%) by the end of 3months. This improvement is seen in patients with cystoid macular oedema due to the usage of topical non-steroidal

anti-inflammatory drugs in only 2 patients. By the end of 3 months there are 2 patients with unresolved CME and 2 patients with ARMD changes which were undetected pre-laser due to hazy media. Visual improvement achieved in our study is in agreement with other studies.<sup>11–16</sup>

Immediate rise in IOP following Nd-YAG capsulotomy is attributed to the clogging of the trabecular meshwork mechanically by the fragments formed due to laser photo-disruption of the posterior capsule.

In our study IOP elevation was seen in 19.1% patients 1 hr after the procedure, 35.9% had rise in the IOP after 1 day. These numbers gradually declined over the next visits to 6.75% at the end of 1 week & 1.1% at the end of 1 month and 3 months.

In the study Pre Laser IOP was  $14.38 \pm 2.31$  mmHg, IOP after 1 hour was  $15.08 \pm 2.91$ , 1 day IOP was  $17.10 \pm 4.70$  mmHg, after 1 week it was  $14.54 \pm 2.25$  mmHg, 1 month was  $14.43 \pm 2.32$  mmHg and 3 Months was  $14.43 \pm 2.32$  mmHg. With the usage of post laser topical beta blockers like Timolol 0.5% significantly brought down the IOP to the lower values within 1 week duration.

In our study, Cystoid macular oedema was noted in 5 patients (5.6%) during the 1 month follow up which was clearly appreciated with a 90D examination. Patients were then started on topical NSAID drops for 1 month.

Pitting of the IOL is noted in 5 patients (5.6%) which however did not lead to any significant visual deterioration in our study. IOL pitting is seen due to the uncooperativeness of the patient. Proper focussing onto the posterior capsule will prevent this complication. 23.6% had iritis after Nd:YAG laser capsulotomy which manifested as cells and flare in the anterior chamber on slit lamp examination. But the iritis subsided in majority of the cases within 1 week as our patients were routinely started on topical antibiotic & steroid medications QID for a week.

Other complications like Hyphaema, Corneal damage, Retinal hole, Retinal haemorrhage and Endophthalmitis are not detected in our study, but other studies have reported their incidence.<sup>17</sup>

## 6. Conclusion

Nd-YAG laser capsulotomy is the gold standard treatment for posterior capsular opacification.

There is excellent improvement in visual acuity in majority of the patients.

IOP monitoring is mandatory both before and after Nd-YAG laser capsulotomy. In majority of the patients, the IOP spikes are transient and can be treated with topical medication. A careful follow-up of the patients would give us an advantage of treating certain long-term complications like retinal detachment immediately. On the whole Nd-YAG is a safe and effective modality of treatment for posterior capsular opacification.

## 7. Source of Funding

None.

## 8. Source of Funding

None.

## References

1. United Nations, Department of Economic and Social Affairs, Population Division. World Population Ageing; 2015. .
2. Jaffe NS, Jaffe SM, Jaffe FG. Cataract surgery and its complications. company Missouri CVM, USA, editors ; 1997,. 6th edition.
3. Auffarth GU, Golescu A, Becker KA. Quantification of posterior capsule opacification with round and sharp edge intraocular lenses. *Ophthalmol.* 2003;110:772–780.
4. Auffarth GU, Peng Q. Posterior capsule opacification: Pathology, clinical evaluation and current means of prevention. *Ophthalmic Pract.* 2000;18(4):172–182.
5. Apple DJ, Peng Q, Visessook N. Eradication of posterior capsule opacification: documentation of a marked decrease in Nd:YAG laser posterior capsulotomy rates noted in an analysis of 5416 pseudophakic human eyes obtained postmortem. *Ophthalmol.* 2001;108:505–518.
6. Soni P, Srivastava A, Yadav D. Nd-YAG laser posterior capsulotomy and visual outcomes. *Indian J Clin Exp Ophthalmol.* 2016;2(3):271–277.
7. Hayashi K, Hayashi H, Nakado F, Hayashi F. Correlation between posterior capsule opacification and visual function before and after Nd: YAG laser posterior capsulotomy. *Am J Ophthalmol.* 2003;136(4):720–726.
8. Channell MM, Beckman H. Intraocular pressure changes after Nd: YAG laser posterior capsulotomy. *Arch Ophthalmol.* 1984;102:1024–1026.
9. Gopinath GS, Satish K, Srivastava N, Patil S, Afshan R. Visual Outcome and Complications of YAG Laser Therapy for Posterior Capsular Opacification Following Cataract Surgery. *Int J Sci Study.* 2015;3(3).
10. Emery JM, Wilhelmus KA, Rosenberg S. complications of phacoemulsification ; 1978,.
11. Georgalas I, Petrou P, Kalantzis G, Papaconstantinou D, Koutsandrea C, et al. Nd: YAG capsulotomy for posterior capsule opacification after combined clear corneal phacoemulsification and vitrectomy. *Ther Clin Risk Manag.* 2009;5(1):133–137.
12. Aslam TM, Hilaryd D, Baljean D. Use of Nd YAG laser capsulotomy. *Survey Ophthalmol.* 2003;48(6):594–612.
13. Durham DG, Gills JP. Three thousand YAG lasers in posterior capsulotomies: an analysis of complications and comparison to polishing and surgical discussions. *Trans Am Ophthalmol Soc.* 1985;83:218–235.
14. McGraw VP, Brosnahan D, Winn B, Whitaker D. Assessment of Retinal-Neural Function Before Neodymium:YAG Laser Capsulotomy. *Invest Ophthalmol Vis Sci.* 1995;36:1155–1151.
15. Hasan KS, Adhi MI, Aziz M. Nd: YAG Laser Posterior Capsulotomy. *Pak J Ophthalmol.* 1996;12:3–7.
16. Wasserman EL, Axt JC, Sheets JH. Neodymium: YAG laser posterior capsulotomy. *J Am Intraocul Implant Soc.* 1985;11(3):245–248.
17. Carlson AW, Koch DD. Endophthalmitis following Nd: YAG laser posterior capsulotomy. *Ophthalmic Surg.* 1988;19:168–170.

## Author biography

Gona Soujanya Resident

Kanthamani. K Professor

**Cite this article:** Soujanya G, Kanthamani. K . Visual outcomes and complications after Neodymium-doped yttrium aluminium garnet laser capsulotomy in Posterior capsular opacification. *Indian J Clin Exp Ophthalmol* 2019;5(4):491-495.