



## Original Research Article

## Anatomical and functional outcome of scleral buckling in primary rhegmatogenous retinal detachment

Biju John C<sup>1,\*</sup>, Rachana Chandran<sup>1</sup>

<sup>1</sup>Regional Institute of Ophthalmology, Govt Medical College, Thiruvananthapuram, Kerala, India



### ARTICLE INFO

#### Article history:

Received 23-04-2019

Accepted 23-08-2019

Available online 27-11-2019

#### Keywords:

Scleral buckling

Rhegmatogenous

Retinal detachment

Break

Macula on

Macula off

### ABSTRACT

**Purpose:** To study the anatomical and functional outcomes, complications and reasons for failure of scleral buckling in primary rhegmatogenous retinal detachment

**Design:** Prospective Observational Study

**Materials and Methods:** 17 eyes of 16 consecutive patients who had undergone scleral buckling for rhegmatogenous retinal detachment at a tertiary care teaching Ophthalmic Institute in South India from January 2015 were taken up for the study. Important points like history of trauma, spectacle use and cataract surgery were noted from the history. Detailed evaluation including snellen visual acuity converted to Logmar vision, Slit Lamp Evaluation, Fundus examination, Applanation tonometry etc were done and documented before surgery and the same parameters were again noted during the follow up examinations on the first post operative day and then at 2 weeks, 4 weeks, 3months and 6 months. Surgical parameters like number and location of breaks, macular status, type of buckling etc were also recorded diligently.

**Results:** 15 Out of the 17 eyes (88%) achieved anatomical success with the retina attached at 4 weeks of post operative follow up. The cause of failure in the remaining 2 cases was missed retinal breaks and were rescued by vitrectomy. The mean average pre operative vision was 2.23 which improved to a mean average vision of 1.49, 1.30, 1.15, 1.04, 1.01 at 1st post operative day, 2weeks, 4 weeks, 3months and 6 months respectively. The change was found to be significant. The macula on RRDs (4 eyes) had better visual improvement with mean pre op Logmar vision improving from 0.842 to a post op Logmar vision of 0.37 and 0.15 at 4 weeks and 6 months respectively.

**Conclusions:** Scleral buckling provides a reasonably good anatomical outcome in properly selected cases of primary rhegmatogenous retinal detachment. It also provides a moderate visual outcome. The post operative visual outcome depends mainly on the pre operative status of macula. The main cause for failure of scleral buckling was missed retinal breaks. There were no major complications in any of our cases.

© 2019 Published by Innovative Publication. This is an open access article under the CC BY-NC-ND license (<https://creativecommons.org/licenses/by/4.0/>)

### 1. Introduction

Rhegmatogenous Retinal detachment (RRD) is the separation of neurosensory retina from retinal pigment epithelial layer secondary to a break in the neurosensory retina which allows seepage of fluid from the vitreous cavity into the subretinal space. It is seen in about 6.3 -17.9 per 100000 population.<sup>1</sup> Scleral buckling is an ophthalmic surgical procedure that has been successfully employed to repair rhegmatogenous retinal detachment for the past 60

years and is still considered as the gold standard treatment for uncomplicated RRD. However recently with the rapid strides in Pars plana vitrectomy especially Minimally invasive suture/less vitrectomy there is a growing reluctance to do Scleral Buckling and Vitrectomy is gradually taking over as the most widely employed technique for the management of RRD.

But despite the shift in treatment options for rhegmatogenous retinal detachment scleral buckling still remains a valuable procedure in many instances. In this prospective study we report the anatomical and functional outcomes of Scleral Buckling in uncomplicated RRDs to reiterate the

\* Corresponding author.

E-mail address: [bijujc@gmail.com](mailto:bijujc@gmail.com) (B. John C).

role of this time tested treatment modality in such cases.

## 2. Aim of study

1. To study the anatomical outcome of scleral buckling in primary rhegmatogenous retinal detachment
2. To study the visual outcome, complications and reasons for failure of scleral buckling in primary rhegmatogenous retinal detachment.

## 3. Materials and Methods

The study was designed as a Prospective observational study and the sample size was calculated based on the proportion of good anatomical outcome (primary aim) taking a previous study as reference<sup>2</sup> as follows

### 3.1. Sample size

Proportion of anatomical outcome() = 85% ; Relative precision (d) =20%;

Confidence level – 95 %

Calculated sample size = 17.

Accordingly 17 eyes of 16 consecutive patients who had undergone scleral buckling for rhegmatogenous retinal detachment at a tertiary care teaching Ophthalmic Institute in South India from January 2015 was included in the study. One patient had bilateral RRD. The sample size was achieved by about 1 year. The following inclusion and exclusion criteria were applied for selecting patients for scleral buckling in this study

### 3.2. Inclusion criteria

Anterior breaks, Phakic eyes, Breaks in same quadrant.

### 3.3. Exclusion criteria

Patients with rhegmatogenous RD who had already undergone pars plana vitrectomy or pneumatic retinopexy, Proliferative vitreo retinopathy, Posterior breaks, Giant retinal tears, Previously failed scleral buckling procedure, Pseudophakic patients, Multiple breaks at different levels

A detailed history was undertaken in all the 16 patients with special attention to details like history of trauma, spectacle use and cataract surgery.

Snellen's vision chart was used for vision assessment and the visual acuity was then converted to Logmar vision for statistical analysis. Applanation tonometry, Fundus examination by 90 D and Indirect Ophthalmoscopy and Goldman 3 mirror was done for all patients. Detailed fundus drawings were made and Fundus findings such as extent of retinal detachment, macular status, presence of proliferative vitreo retinopathy, type and position of breaks were all noted diligently.

The type of scleral buckling and the type of buckle used for the surgery was also noted.

Post operative follow up examinations were done on the first post operative day and then at 2 weeks, 4 weeks, 3 months and 6 months. Details like visual acuity, intraocular pressure were assessed. Fundus examination was done with indirect ophthalmoscope in each visit to assess the fundus status and also for any complications. The causes for failure of scleral buckling were also taken into consideration. Any other procedure done in these cases were also noted. The main outcome measure was the anatomically re-attached retina at 4 weeks of post operative followup.

Procedure Following conjunctival peritomy, hooking the recti muscles, inserting the bridle sutures the break was first localized with Indirect Ophthalmoscopy. Cryotherapy was applied around the break visualizing through the Indirect Ophthalmoscope. In all cases aim was to place a segmental scleral buckle over the break under a 2.5 mm encircling silicone band. The segmental buckle was secured along with the encircling band over the break with the help of preplaced mattress sutures (5-0 polyester). The encircling band was passed through scleral tunnels fashioned in all the 4 quadrants and the ends being sutured together. SRF was drained once the mattress sutures were placed, but before passing the buckle. After the drainage the segmental buckle along with the encircling band was placed in position as described above and the mattress sutures tightened to produce the desired buckling effect. Intravitreal gas was used sometimes for superior breaks. The conjunctiva was apposed with sutures.

## 4. Observation and Results

### 4.1. Baseline characteristics of patients

The 16 patients included in the study had age ranging from 39 years to 63 years. 35% of the patients were below 45 years and 64% were above 45 years. Mean average age was 48.06. Out of this 52% were females and 47% were males.

3 eyes (17%) had history of trauma and 6 eyes (35 %) had history of spectacle use. All the eyes were phakic and did not have history of any ocular surgery. 3 eyes out of the 17 eyes were myopic (17%). The fellow eyes of the 4 patients (23%) had to undergo barrage laser due to presence of lattice with holes.

9 eyes (52.9%) had single break, 4 eyes (23.5%) had 2 breaks and 3 eyes (17.6%) had 3 breaks. 1 eye (5%) had a retinal dialysis. All the breaks were in the same quadrant. Out of the 17 eyes, 8 eyes (47 %) had breaks located in the superotemporal quadrant, 3 eyes (17.6%) had in the inferotemporal quadrant, 4 eyes (23.5%) in the superonasal quadrant and in 2 eyes (11.8%) in the inferonasal quadrant.

6 eyes (35.2%) had inferior RD, 5 eyes (29.4%) with superotemporal RD, 4 eyes (23.5%) with superior RD and 2 eyes (11.7%) had subtotal RD.

Out of the 17 eyes 13 eyes (76%) had retinal detachment with macula off status preoperatively. Out of these 13 eyes

2 eyes had macular hole.

#### 4.2. Surgical parameters and anatomical outcome

16 eyes out of the 17 eyes had undergone segmental scleral buckling and 1 eye undergone encirclage for retinal dialysis. Cryotherapy and SRF drainage was done in all 17 cases and C3F8 bubble was used in 6 eyes (35%) of cases.

Out of the 17 eyes in 15 eyes retina was attached at 4 weeks of post operative follow up. (Table 1) and (Figure 1)

2 eyes out of the 17 eyes had to undergo rescue vitrectomy surgery. The cause of failure of scleral buckling in these 2 cases was missed retinal tear. One eye had anterior ischemia and redetachment after 4 weeks of follow up.

One eye had an IOP of 26 mm of Hg with applanation tonometry on post op day 1 and at 2 weeks and was managed with topical anti glaucoma medications

#### 4.3. Visual parameters and its change with surgery

Vision was assessed with Snellen's vision chart and was converted to Logmar vision chart. The mean average pre operative vision was 2.23 and which improved to a mean average vision of 1.49, 1.30, 1.15, 1.04, 1.01 at 1st post operative day, 2 weeks, 4 weeks, 3 months and 6 months respectively. The change was found to be significant. (Table 2)

Repeated measure ANOVA was used for statistical analysis of vision and to correlate it with the effect. (Table 3).

With repeated ANOVA measure  $F(3,16)$  is 33.35. Partial eta square value show relatively high effect (0.676) and it is significant

The visual change was also analysed by grouping the eyes based on whether it was a Macula off or Macula On RRD.

4 eyes had Macula On RRD when taken up for surgery and in them the pre op mean Logmar vision improved from 0.842 to a post op Logmar vision of 0.37 and 0.15 at 4 weeks and 6 months respectively. The rest of the eyes (13) had Macula off RRD and in them the improvement in vision of eyes was considerably less than eyes with macula on status. (Figure 2)

### 5. Discussion

In our study Scleral Buckling was done as the primary procedure for 13 eyes (76.4%) with macula off RRD and 4 eyes (23.5%) with macula on RRD. After the surgery retina was attached in 88% at 4 weeks follow up and remained attached at 6 months. 17.6% (3 eyes) were myopic. The cause for failure of scleral buckling was missed breaks and these eyes were taken up for rescue vitrectomy surgery.

The single surgery anatomical success rates in our study was 88%, which was comparable with that of other studies showing primary success rate of scleral buckling in the

range of 80-90%<sup>2-4</sup>

The most common complication encountered in the post op period by us was rise in IOP in 2 eyes (11.7%) which was controlled with anti glaucoma medication.

In the study conducted by MT Khan et al<sup>2</sup> which reported anatomical success of 85.71 % at 2 weeks postop also the most common complication was raised IOP in 21.43% at 2 weeks follow up.

The pre op Logmar vision improved from 2.23 to post op Logmar vision of 1.15 and 1.01 at 4 weeks and 6 months ( $p < 0.001$ ) respectively. This was also comparable to the functional outcomes of other major studies<sup>5,6</sup>

It was observed that patients with poor preoperative vision due to macula off status and macular hole had only moderate improvement in vision. But patients with better pre op vision and macula on status had good post op vision.

The anatomical and visual outcomes of our study group is comparable with the other similar studies in the literature.

The limitation of the study was low sample size.

Scleral buckling has been the primary surgical modality in the treatment of uncomplicated RRD where the media are sufficiently clear,<sup>7</sup> breaks are anterior and in the same quadrant. However presently, the trend is shifting towards vitrectomy for most of the cases and the number of cases managed by scleral buckling is coming down. As far as Pseudophakic eyes are concerned primary vitrectomy is considered to be the procedure of choice.<sup>7,8</sup>

In suitable cases, even though there is not much difference as far as the single surgery outcome is concerned; scleral buckling definitely has some significant advantages over vitrectomy which are as follows

1. No tamponade used and so results in earlier visual recovery and also eliminates the need for a second surgery to remove the tamponade
2. Considerably lower risk of Cataract

Hence scleral buckling is not something to be shunned by the vitreoretinal surgeon and has a definite role in his armamentarium

### 6. Conclusions

1. Scleral buckling provide a reasonably good anatomical outcome in properly selected cases of primary rhegmatogenous retinal detachment.
2. It also provides a moderate visual outcome. The post operative visual outcome depends mainly on the pre operative status of macula.
3. There were no major complications
4. The main cause for failure of scleral buckling was missed retinal breaks.

### 7. Source of Funding

None.

**Table 1:** Post op Fundus Status: Retina was found to be attached in 15 eyes (88%) at 4 weeks post op and remained attached at 6 months

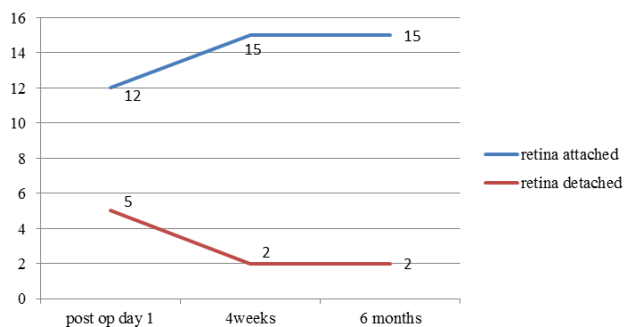
	Post op day 1	Post op 4 week	Post op 6 months
Retina attached	70.5%	88%	88%
Retina detached	29.4%	11%	11%

**Table 2:** Mean Logmar Vision: Shows the stead improvement in log mar vision from pre op to 6 months. Statistically significant as per P value

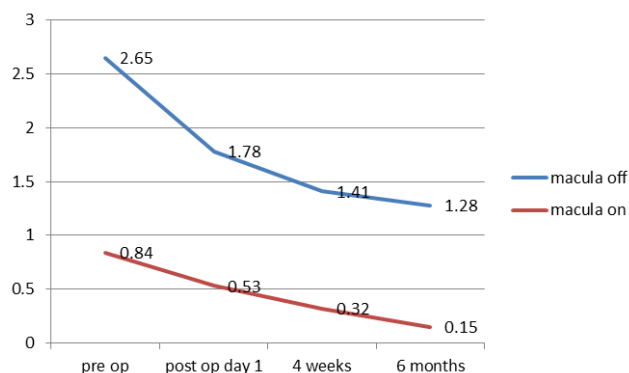
	Pre op	Post op day1	Post op 4 weeks	Post op 6 months
Mean Logmar vision	2.23	1.49	1.15	1.01
Standard deviation	0.98	1.77	0.55	0.75
P value	<0.001	<0.001	<0.001	<0.001

**Table 3:** Tests of Within-Subjects Effects: Repeated measure ANOVA was used for statistical analysis of vision and to correlate it with the effect. With repeated ANOVA measure F(3,16) is 33.35. Partial eta square value show relatively high effect (0.676) and it is significant

Measure: MEASURE_1		Type III Sum of Squares	df	Mean Square	F	Sig.	Partial Eta Squared
time	Sphericity Assumed	15.051	3	5.017	33.351	.000	.676
	Greenhouse-Geisser	15.051	2.052	7.335	33.351	.000	.676
	Huynh-Feldt	15.051	2.358	6.384	33.351	.000	.676
	Lower-bound	15.051	1.000	15.051	33.351	.000	.676
Error(time)	Sphericity Assumed	7.220	48	.150			
	Greenhouse-Geisser	7.220	32.832	.220			
	Huynh-Feldt	7.220	37.721	.191			
	Lower-bound	7.220	16.000	.451			



**Fig. 1:** Anatomical Outcome: Attached Vs Detached Retinas during Post Op follow up. 15 eyes shows attached retinas at 4 wks follow up and remains attached. 2 eyes shows anatomical failure with detached retinas at 4 wks



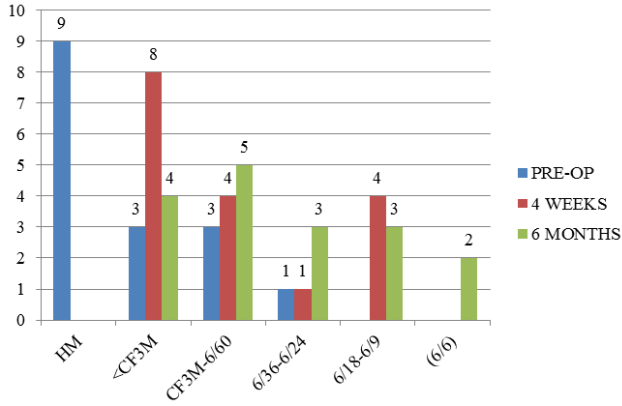
**Fig. 2:** Mean Logmar Vision of Macula off Vs Macula on RRD. Macula on RRDs showed better visual recovery than macula off RRDs

**8. Conflict of Interest**

None.

**References**

- Mitry D, Charteris DG, Fleck BW, Campbell H, Singh J. The epidemiology of rhegmatogenous retinal detachment: geographical variation and clinical association. *Br J Ophthalmol.* 2010;94(6):678-684.
- Khan MT, S J, Karim S, Iqbal S, Saed N. Outcome of Scleral Buckling procedures in primary Rhegmatogenous Retinal Detachment. *J Pak Med Assoc.* 2010;60(9):754-757.
- Yorstan D, Jalali S. Retinal detachment in developing countries Eye(Lond). 2002;16:353-358.
- Afrashi F, Akkin C, Egrilmez S. Anatomic outcome of scleral buckling surgery in primary rhegmatogenous retinal detachment. *Ophthalmic Vis Res.* 2005;26(7):90-96. *Int Ophthalmol.*
- Fang W, Li JK. Predictive factor for post op visual function of primary chronic rhegmatogenous retinal detachment. *Int Ophthalmol.*



**Fig. 3:** Graph showing Pre op Vision Vs Post op Vision in Snellen's chart

2016;9(7):994-998.

6. Falavarjani KG, Alemzahed SA. Scleral buckling for rhegmatogenous retinal detachment with subretinal proliferation. *Eye (Lond)*. 2015;29(4):509-514.
7. Azad RV, Sharma YR. Primary vitrectomy versus conventional retinal detachment surgery in phakic rhegmatogenous retinal detachment. *Acta Ophthalmol*. 2007;85(5):540-545.
8. Schneider EW, Geracts RL, Johnsons MV. Pars plana vitrectomy without adjuvant procedure for repair of primary rhegmatogenous retinal detachment. *Retina*;2012(2):213-219.

**Author biography**

**Biju John C** Additional Professor

**Rachana Chandran** Junior Resident

**Cite this article:** John C B, Chandran R. Anatomical and functional outcome of scleral buckling in primary rhegmatogenous retinal detachment. *Indian J Clin Exp Ophthalmol* 2019;5(4):437-441.