



Original Research Article

Study of retinal changes among patients presenting with pregnancy induced hypertension

Akansha^{1,*}, Arpita², Ram Kumar¹¹Dept. of Ophthalmology, BRD Medical College, Gorakhpur, Gorakhpur, Uttar Pradesh, India²Dept. of Obstetrics and Gynaecology, Teerthanker Mahaveer University, Moradabad, Uttar Pradesh, India

ARTICLE INFO

Article history:

Received 15-01-2019

Accepted 08-10-2019

Available online 27-11-2019

Keywords:

Retinal changes

Pregnancy induced hypertension

ABSTRACT

Aim: To study retinal changes among patients presenting with pregnancy induced hypertension**Material and Methods:** Patients who fulfilled diagnostic criteria of pregnancy induced hypertension were enrolled.**Results:** Total 100 patients were examined among which 21 patients had grade I hypertensive changes, 32 showed grade II changes, 8 and 3 patients had grade III and IV retinopathy respectively. Three patients developed serous retinal detachment.**Conclusion:** We conclude that sixty four percent of patients with pregnancy induced hypertension had related retinopathy. Focal spasms or generalized arteriolar attenuation were the most common vascular findings. Grade III and Grade IV retinopathy changes were more frequently noted in patients with severe preeclampsia and eclampsia.© 2019 Published by Innovative Publication. This is an open access article under the CC BY-NC-ND license (<https://creativecommons.org/licenses/by/4.0/>)

1. Introduction

Pregnancy induced hypertension (PIH) is considered when blood pressure rises more than 140/90 mmHg or a rise of 30 mmHg of systolic pressure, or a rise of 15 mm/Hg of diastolic pressure, taken twice after rest, in combination with generalized edema and/or proteinuria.¹ It occurs in 5-10% of all pregnancy.² Various retinal changes noted in these patients include spasm and focal/generalized narrowing of retinal arterioles, hemorrhages, exudates, peripapillary or focal retinal edema, serous retinal detachment, bilateral retinal detachment, acute ischemic optic neuropathy, retinal pigment epithelial lesions, temporary decrease in vision secondary to severe retinal arteriolar spasm and retinal edema, permanent blindness owing to central retinal artery occlusion and optic atrophy.³

The primary response of the retinal vasculature to systemic arterial hypertension is vascular narrowing which leads to focal or diffuse vasoconstriction and extravasation

of fluid.³

Changes in retinal vasculature may give a clue about placental circulation and fetal health. If PIH is detected early maternal and fetal complication can be managed well. Retinal changes are reversible and the retinal vessels normalize post delivery.⁴

2. Materials and Methods

This was a prospective observational study carried out in the Department of Ophthalmology, BRD medical college. 100 patients who fulfilled diagnostic criteria of PIH during a period of one year (Feb 2018- Dec 2018) were enrolled for the study. Informed consent was taken and baseline data was recorded.

2.1. Inclusion criteria

Diagnostic criteria of PIH:

1. Period of gestation >20 weeks
2. Blood pressure >140/90mm Hg

* Corresponding author.

E-mail address: gbakna@gmail.com (Akansha).

2.2. Exclusion criteria

1. Patients who had a prior history of hypertension, diabetes mellitus, cardiovascular disease, and renal disease before pregnancy.
2. Patients having ocular media opacity which interfered with examination of fundus.

All the enrolled patients were initially evaluated by an obstetrician. Pregnancy induced hypertension was graded as preeclampsia (non severe and severe) and eclampsia according to ACOG criteria.²

Detailed history and ocular evaluation was done including: Visual acuity assessment with Snellen's chart and best corrected visual acuity. Fundus examination under mydriasis (plain tropicamide) was performed. Findings were recorded on retinal chart using standard colour coding. Changes suggestive of hypertensive retinopathy were recorded and graded using Keith Wagner Barker classification⁵ into –

1. Grade I- Mild or moderate narrowing of smaller arterioles
2. Grade II - Moderate to marked narrowing of retinal arterioles, exaggeration of light reflex, changes at AV crossings.
3. Grade III - Prominent AV crossing changes, retinal edema, cotton wool spots, flame shaped haemorrhages.
4. Grade IV - Grade III changes with papilloedema.

2.3. Statistical analysis

The data was coded and compiled on Microsoft Excel spread sheet. The data was analysed by chi- square test and unpaired t-test using SPSS software. A probability value ('p' value) of <0.05 was considered as statistically significant.

3. Results

Total 100 patients were examined in the study. The present study had 64% prevalence of retinal changes among patients with pregnancy induced hypertension. The mean age of patients was 26.91 years (range 20-40 years). The gestation period ranged between 20 and 40 weeks. 65(65%) were primigravida, 25(25%) were multigravida (2-4 pregnancies), and 10(10%) were Grand Multi (5 or more deliveries). 38(38%) patients had mild preeclampsia, 50(50%) had moderate to severe preeclampsia and 12(12%) had Eclampsia.

Gravidity distribution: Among 53(53%) primigravida patients 28(52.8%) patients showed fundus changes while out of 44 patients who were multigravida 31(77.5%) patients had retinal changes. We found a significant correlation between gravidity and retinal changes ($p = 0.01$).

Severity of disease: In our study, retinal changes were observed in 11(31.4%) patients out of 35 patients with non severe preeclampsia, 42(91.3%) out of 46 patients

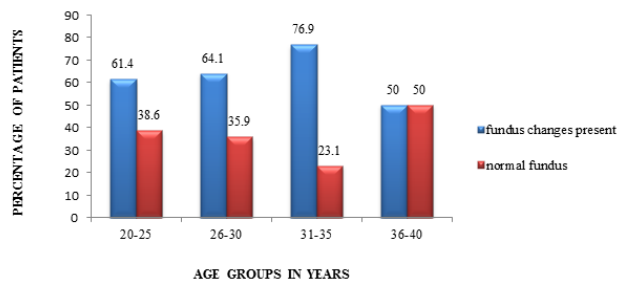


Fig. 1:

with severe preeclampsia and all eclampsia patients showed fundus changes.

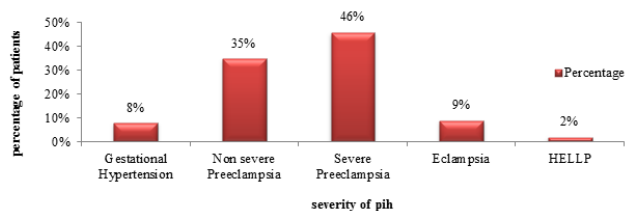


Fig. 2:

Symptoms: Most of the patients were asymptomatic. The most common complaint was headache in 46(46%) cases. Twenty (20%) patients complained of blurring of vision. Sudden diminution of vision was noted in 4 cases (4%).

Retinal change: 21 patients had grade I changes, 32 showed grade II changes, grade III and grade IV hypertensive changes was seen in 8 and 3 patients respectively. Three patients developed serous retinal detachment.

4. Discussion

In the present study, hypertensive retinopathy was seen in 64% of patients with pregnancy induced hypertension mean age of subjects was 26.91 ± 12.76 years. Reddy et al⁶ from Malaysia found a prevalence rate of 59% in their study of 78 cases with PIH. Greater incidence in younger age group could be because of non compensatory hypertension^{7,8}

The most common visual symptom in PIH is blurring of vision, but photopsias, scotomas, diplopia, and cortical blindness have also been reported. In the present study, visual acuity was 6/6-6/18 in majority 91(91%) of patients. Visual acuity was between 6/18-6/60 in 3(3%) patients, of these 1 patient had serous retinal detachment and 2 patients had bilateral macular edema. Two (2%) patients had visual acuity of 6/60-3/60, both had macular edema in both eyes as the cause. Four (4%) patients had vision of 1/60 to perception of light. 2 patients had serous Retinal detachment with vision hand movements in both eyes.

Table 1:

Age in years	Number of patients	Fundus changes		p-value ¹
		Present No. (%)	Absent No. (%)	
20-25	44	27(61.4%)	17(38.6%)	0.70
26-30	39	25(64.1%)	14(35.9%)	
31-35	13	10(76.9%)	3(23.1%)	
36-40	4	2(50.0%)	2(50.0%)	

¹ Chi-square test**Table 2:**

Gravidity	Number of patients	Fundus changes		p-value ¹
		Present No. (%)	Absent No. (%)	
Primigravida	53	28(52.8 %)	25(47.2%)	0.01*
Multigravida	44	35(79.5%)	9(20.5%)	
Grand multipara	3	1(33.3%)	2(66.7%)	

Table 3:

Visual acuity in better eye	Number of patients No. (%)	Fundus changes		p-value ¹
		Present No. (%)	Absent No. (%)	
6/6-6/18	91 (91.0%)	56(61.5%)	35(38.4%)	0.23
6/18- 6/60	3 (3.0%)	2(66.7%)	1(33.3%)	
6/60-3/60	2 (2.0%)	2(100.0%)	0.0	
1/60-PL +	4 (4.0%)	4(100.0%)	0.0	

Table 4:

Grade of hypertensive retinopathy	Number of patients	Percentage
No changes	36	36%
Grade I	21	21.0%
Grade II	32	32.0%
Grade III	8	8.0%
Grade IV	3	3.0%
Serous RD	3	3.0%

Table 5: Most common finding seen was generalized attenuation of vessels.

Fundus changes	Number of patients	Percentage
Generalised vascular spasm	36	36%
Macular edema	6	6%
Serous Retinal detachment	3	3%

Table 6: Distribution according to severity of disease

Hypertensive Retinopathy	Number of patients	Severity of PIH			Eclampsia No. (%)	HELLP No. (%)
		Gestational hypertension No. (%)	Non Severe Preeclampsia No. (%)	Severe Preeclampsia No. (%)		
Grade I	21	1(4.8%)	10 (47.6%)	10 (47.6%)	0.0	0.0
Grade II	32	0.0	1(3.1%)	24(75 %)	6(18.8%)	1(3.1%)
Grade III	8	0.0	0.0	6 (75.0%)	2 (25%)	0.0
Grade IV	3	0.0	0.0	2 (66.7%)	1 (33.3%)	0.0

p value =0.009*

Two (2%) patients had transient diminution of vision with improvement in 48 hours.

Karki et al⁹ didn't come across any patients complaining of significant visual disturbances. Most of the patients had visual acuity between 6/6 and 6/9. Bharathi et al¹⁰ in their study noted blurring of vision in 8(5.3%) cases and sudden loss of vision in 2 cases (1.3%).

In our study, 64(64%) patients with hypertensive retinopathy were further classified based on Keith-Wagner and Barker classification.⁵ Among these, grade I hypertensive changes was seen in 21(21.0%) patients, grade II changes was noted in 32(32.0%) patients, grade III grade IV hypertensive retinopathy was noted in 8(8.0%) and 3(3%) patients respectively.

Rasdi et al¹¹ in their study of 50 patients found had grade I hypertensive retinopathy in 24 patients (48.0%), grade II changes in 21 patients (42.0%), grade III retinopathy in 4 patients (8.0%) and grade IV hypertensive retinopathy in 1 patient. Sadowsky et al¹² observed retinal vascular changes in 121 cases and noted grade 0 in 7 cases, grade I in 58 cases, grade II changes in 44 cases and grade III-IV changes in 12 cases. The findings in our study were in consonance with other studies conducted.

In our study, among 32 patients with grade II hypertensive retinopathy severe preeclampsia was present in 24(75%) cases and 6(18.8%) were eclampsia patients. Out of 8 patients with grade III hypertensive retinopathy, severe preeclampsia was present in 6(75%) cases and 2(25%) were eclampsia patients. Out of 3 patients with grade IV retinopathy changes, 2(66.7%) cases had severe preeclampsia and 1(33.3%) patient had eclampsia. There was statistically significant ($p=0.009$) association between severity of pregnancy induced hypertension and hypertensive retinopathy.

Tadin et al¹³ in their study observed statistically significant association between the grades of hypertensive retinopathy and severity of pre- eclampsia ($p = 0.033$). Reddy et al⁶ found that degree of retinopathy was directly proportional to severity of preeclampsia. Sadowsky et al¹² stated that there exists a correlation between retinal vascular changes and severity of toxemic condition. The proportion of severe cases of toxemia becomes progressively larger as the retinal changes become more severe.

In the present study, generalised attenuation seen in 21(21%) cases and generalised attenuation with focal spasm noted in 20(20%) cases were the most common retinal vascular changes. Generalised attenuation with arterio-venous nicking were seen in 12(12%) patients and generalised attenuation along with focal spasm and AV nicking were present in 11(11%) patients. Bilateral macular edema was seen in 6(6%) cases and unilateral macular edema was present in 1 patient in right eye. Two (2%) patients showed choroidal changes (elschnigns spots).

In the present study, 3(3%) cases of bilateral serous retinal detachment were detected. Termination of pregnancy was advised in two of these cases. All 3 patients had eclampsia with no prenatal care.

We studied a 27 year old sixth gravida female with eclampsia who developed bilateral exudative retinal detachment along with grade IV hypertensive retinopathy in immediate postpartum period. Her presenting visual acuity was hand movements in both eyes. Her blood pressure was 170/120 mmHg. At six weeks evaluation, the serous retinal detachment resolved leaving behind patches of retinal pigment epithelial changes, and visual acuity was 6/18 in both eyes.

In our study papilloedema was seen in 3(3%) cases. The presence of papilloedema in the eyes may indicate raised intracranial tension and such patients may develop convulsions.

Jaffe and Schatz¹⁴ did not find any haemorrhages, exudates, cotton wool spots, or retinal detachment in their study of 17 mild preeclamptic and 14 severe preeclamptic patients. Fry et al¹⁵ showed that retinal detachment occurs in 1.2% cases of late toxemias and 10.4% cases of eclampsia. Bosco et al¹⁶ reported 10 cases of retinal detachment (RD) with 7 patients with no prenatal care. Maurya et al¹⁷ reported retinal detachment in 1.9% cases.

Bilateral exudative retinal detachment occurs along with hypertensive retinopathy. It occurs due to choroidal ischemia. The management of serous retinal detachment is termination of pregnancy after controlling blood pressure and vision can be saved in the affected eye.¹⁸

Retinal pigment epithelial lesions, called Elschnign spots, may also be found in preeclamptic patients with choroidal infarcts.¹⁹ Presence of macular edema or papilloedema or retinal detachment are the warning signs for termination of pregnancy.

5. Conclusion

We conclude that sixty four percent of patients with pregnancy induced hypertension had related retinopathy. Diminution of vision was the most common visual symptom. Focal spasms or generalized arteriolar attenuation were the most common vascular findings. Grade III and Grade IV retinopathy changes were more frequently noted in patients with severe preeclampsia and eclampsia. Few patients also presented with vision threatening complications such as serous retinal detachment, macular edema and cortical blindness. Presence of macular edema, papilloedema or retinal detachment are the warning signs for termination of pregnancy.

6. Source of Funding

None.

7. Conflict of Interest

None.

References

- Sheth BP, Mieler WF. Ocular complications of pregnancy. *Curr Opin Ophthalmol*. 2001;12:455–463.
- Cunningham FC, Leveno KJ, Bloom SL, Spong CY, Dashe JS, et al. New York:Mc Graw-Hill. *Williams Obstetrics*. 2014;p. 728–69. 24th ed.
- Ober RR. Preeclampsia-eclampsia syndrome. In: Ryan SJ, editor. *Retina*. 4th ed. . China:Elsevier Mosby; Elsevier Mosby ; 2006,.
- Richard RO. Pregnancy induced hypertension (preeclampsia-eclampsia). 2nd ed St Louis: Mosby R, editor ; 1994,.
- Keith NM, Wagener HP, Barker NW. Some different types of essential hypertension: their course and their prognosis. *Am J Med Sci*. 1939;197:332–343.
- Reddy SC, Nalliah S, George SR, Who TS. Fundus changes in pregnancy induced hypertension. *Int J Ophthalmol*. 2012;5:694–697.
- The pregnant womans eye. *Surv Ophthalmol*. 1988;32:219–238.
- Dekker G, Sibai B. Primary, secondary and tertiary prevention of pre-eclampsia. *Lancet*. 2001;357:209–215.
- Karki P, Malla P, Das H, Uprety DK. Association between pregnancy-induced hypertensive fundus changes and fetal outcomes. *Nep J Ophthalmol*. 2010;2:26–30.
- Bharathi NR, Raju RS, Prasad PK, Raju SN, Premalatha, et al. Fundus changes in pregnancy induced hypertension: a clinical study. *J Evol Med Den Sci*. 2015;4:1552–1562.
- Rasdi AR, Nik-Ahmad-Zuky NL, Bakiah S, Shatriah I. Hypertensive retinopathy and visual outcome in hypertensive disorders in pregnancy. *Med J Malaysia*. 2011;66:42–47.
- Sadowsky A, Serr DM, Landau J. Retinal changes and foetal prognosis in toxemia of pregnancy. *Obstet Gynecol*. 1956;8:426–431.
- Tadin I, Bojic L, Mimica M, Karelavic D, Dogas Z. Hypertensive retinopathy and pre-eclampsia. *Coll Antropol*. 2001;25:77–81.
- Jaffe G, Schatz H. Ocular manifestations of preeclampsia. *Am J Ophthalmol*. 1987;103;p. 309–315.
- Fry WE. Extensive bilateral retinal detachment in eclampsia, with complete reattachment: report of two cases. *Arch Ophthalmol*. 1929;1:609–614. Fry WE.
- Bosco JA. Spontaneous nontraumatic retinal detachment in pregnancy. *Am J Obstet Gynecol*. 1961;82:208–212.
- Maurya RP, Srivastav T, Chaudhary S, Awasthi P, Retinal RM. Retinal vascular disorders during pregnancy: An observational study. *I J Obst Gynecol Res*. 2018;5(2):282–286.
- Oliver M, Uchenik D. Bilateral exudative retinal detachment in eclampsia without hypertensive retinopathy. *Am J Ophthalmol*. 1980;90:792–796.
- Saito Y, Tano Y. Retinal pigment epithelial lesions associated with choroidal ischaemia in pre-eclampsia. *Retina*. 1998;18:103–108.

Author biography

Akansha Senior Resident

Arpita Assistant Professor

Ram Kumar Professor

Cite this article: Akansha , Arpita , Kumar R. Study of retinal changes among patients presenting with pregnancy induced hypertension. *Indian J Clin Exp Ophthalmol* 2019;5(4):417-421.