

Association of spheroidal degeneration in pseudoexfoliation cases

H Mohan Kumar¹, M Madhumita^{2,*}

¹Professor, ²Post Graduate, Dept. of Ophthalmology, Sri Devaraj Urs Medical College & Research Centre, Tamaka, Kolar, Karnataka, India

***Corresponding Author: M Madhumita**

Email: hmkdoc71@gmail.com

Abstract

Purpose: To correlate the association of pseudoexfoliation with spheroidal degeneration, and to identify the type and stage of spheroidal degeneration in pseudoexfoliation patients.

Material and Methods: Total of 64 patients between the age group of 40 to 70 years, attending Ophthalmology out-patient department were included in this study. After taking informed consent, demographic details and detailed history were taken from these patients. Comprehensive ophthalmic examination, which included visual assessment by Snellens chart and anterior segment evaluation by slit lamp examination was done.

Results: A total of 64 patients (41 male and 23 female), in the age group between 40 and 70 years, with pseudoexfoliation were included. Out of the 64 patients with pseudoexfoliation who were screened in our outpatient department, 44 (68.75%) patients were diagnosed to have spheroidal degeneration. Among these 28 (43.75%) patients were having stage 1, 7 (10.93%) patients were having stage 2, 5 (7.81%) patients had stage 3 and, 4 (6.25%) patients had stage 4 spheroidal degeneration.

Conclusion: Pseudoexfoliation cases have higher incidence of spheroidal degeneration association as compared to general population. It was also observed that droplet type (stage 1) of spheroidal degeneration was commonly seen in pseudoexfoliation cases, and the pupillary margin was the common site for pseudoexfoliation material deposition in most of the cases. This poses challenges to measure intraocular pressure effectively, as well as increase the chances of complications when intraocular procedures are done even with experienced hands.

Keywords: Cataract, Droplet type, Exfoliation material, Pseudoexfoliation, Phacodonesis, Spheroidal degeneration.

Introduction

Pseudoexfoliation (PEX) is a condition where there is a deposition of extracellular grey and white material over the various tissues in the eye. These deposits can be observed through slit lamp as a white greyish deposit in various structures of entire anterior segment of the eye, mainly on the edge of the pupil, the anterior surface of lens capsule, corneal endothelium, iris, trabecular meshwork, zonules, and ciliary body.¹ The deposit can also be seen in posterior segment structures especially near pars plana. Diagnostically the presence of pseudoexfoliation material (PEM) on the anterior capsule of lens is the most constant and important clinical feature of PEX.²

Clinical observations suggest that eyes with PEX syndrome, even without glaucoma or elevated intraocular pressure, have a tendency to develop corneal endothelial decompensation.³ There is a tendency for reduction in the quantity of endothelial cells with altered morphology.

Spheroidal degeneration, a common corneal degeneration and is usually bilateral and interpalpebral. Clinically one can observe amber-coloured oily spherule deposits at and around Bowman's membrane of the cornea. This relatively common condition is described by various authors under different names such as Bietti nodular hyaline band shaped keratopathy, Climatic droplet keratopathy, Spheroidal droplet degeneration, Fisherman's keratopathy, Labrador keratopathy, Nama keratopathy, Eskimo keratopathy, Fraunfelder and Hanna etc, based on the clinical appearance or the geographical location or population groups in which the cases were identified. However, spheroidal degeneration (Fraunfelder and Hanna)

is the most consistent term used to describe all the related lesions.⁴

Usually patients with spheroidal degeneration present with severe foreign body sensation, pain, redness, watering, photophobia, and deterioration of vision. These patients also have poor corneal wettability and irregular ocular surface and they are not suitable for most of the extra and intra-ocular procedures and surgeries. The intra ocular pressure measurement and retinoscopy will be difficult in the presence of irregular corneal surface. The above factors, in turn, result in a gross decreased quality of life of the individual.⁴

Pseudoexfoliation (PEX) is one of the frequently encountered clinical entity involving the anterior segment of the eye. Careful examination however, can reveal numerous clinical ocular complications ranging from secondary chronic open angle and closed angle glaucomas, an association of phacodonesis and lens subluxation, which has a bearing on increased incidence of vitreous loss during cataract surgery. The blood aqueous barrier breakdown, anterior chamber hypoxia, melanin dispersion, poor pupillary dilatation, and formation of posterior synechiae are other associated problems in PEX cases.⁵

Aims and Objectives

1. To correlate the association of pseudoexfoliation with spheroidal degeneration.
2. To identify the type and stage of spheroidal degeneration in pseudoexfoliation patients.

Materials and Methods

This prospective observational study was conducted from August 2018 to November 2018, involving a total of 64 patients between the age group of 40 to 70 years attending Ophthalmology out-patient department at R.L. Jalappa Hospital and Research Centre, Tamaka, Kolar attached to Sri Devaraj Urs Medical College, were included in this study. After taking written informed consent, demographic details and detailed history of all patients were taken. All patients underwent a complete ocular examination, which includes visual acuity assessment by Snellens chart including best corrected visual acuity (BCVA). The Anterior segment evaluation was done by slit lamp examination, including gonioscopic examination wherever possible. Intra ocular pressure was measured wherever possible. A detailed dilated fundus examination was done with both direct and indirect ophthalmoscopy. Corneal staining with fluorescein dye was done in all cases.

Patients with trauma to the eye, chemical injuries of the eye, congenital malformations of the eye, uveitis, total opacified cornea, and atrophic and phthisis bulbi were excluded from the study.

Based on the clinical appearance of the spheroids under slit lamp examination, they were classified under the following stages.^{4,6,7}

Stage 1: Tiny, microscopic oil droplet like lesions in the interpalpebral area, nasally and temporally near limbus, best seen by retroillumination.^{4,6,7}

Stage 2: Fine granular lesions in the interpalpebral area. Cornea appears ground glass. Lesions extend upto Bowman's membrane.^{4,6,7}

Stage 3: Amber coloured spherical nodules, raised above the surface of the cornea, occupying the peripheral or central cornea. Confluent lesions in the central part causes diminution of vision.^{4,6,7}

Stage 4: Spherules are associated with thinning and opacification of the superficial cornea. Gross visual deterioration occurs in this stage. Such patients are liable to get indolent corneal ulcers.^{4,6,7}

Sample Size Calculation

The sample size was based on the prevalence of corneal spheroidal degeneration of 10.7% in a study by Mohan A et al.⁸ in 2017 with 99% confidence level estimated with an absolute error of 10%. The required sample size for the study estimated is 64.

Results

Prospective observational study for about 4 months from August 2018 and November 2018 involving a total of

64 patients (male - 41 and female- 23 [Fig. 1]), with the age group between 40 and 70 years, with pseudoexfoliation were included. Out of the 64 patients with pseudoexfoliation, who were screened in our outpatient department, a total of 44(68.75%) patients were diagnosed to have spheroidal degeneration. In that, 28(43.75%) patients were having stage 1 [Fig. 2-A], 7(10.93%) patients were having stage 2 [Fig. 2-B,C], 5(7.81%) patient with stage 3 [Fig. 2-D,E,F] and 4(6.25%) patients with stage 4 [Fig. 2-G, H, I] spheroidal degeneration.

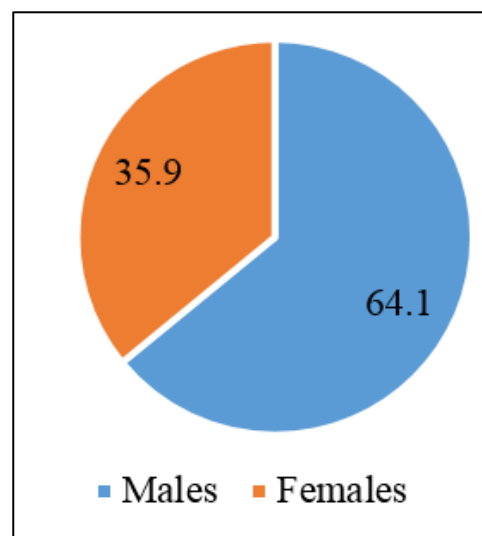


Fig. 1: Pie chart showing gender distribution

Discussion

In the year 1917, Lindberg, the Finnish Ophthalmologist was the first to describe PXS (Pseudoexfoliation syndrome).⁹ The chemical composition of exfoliation material (XFM) is not still clearly understood. An abnormal and altered metabolism of glycosaminoglycans leads to overproduction of the fibrillary material and this has been incriminated as one of the key changes in XFS. Both non-collagenous basement membrane components and epitopes of the elastic fibre system such as fibrillium are the proteins isolated from pseudoexfoliation syndrome patients.⁵

These patients present with small flakes on the pupillary margin [Fig. 3] or there may be fine pigments on the surface of iris, especially in the folds and crypts. Lens may show clinically three distinct zones, i.e. a translucent central disk; a granular girdle around periphery; and a clear zone separating these two areas.¹⁰

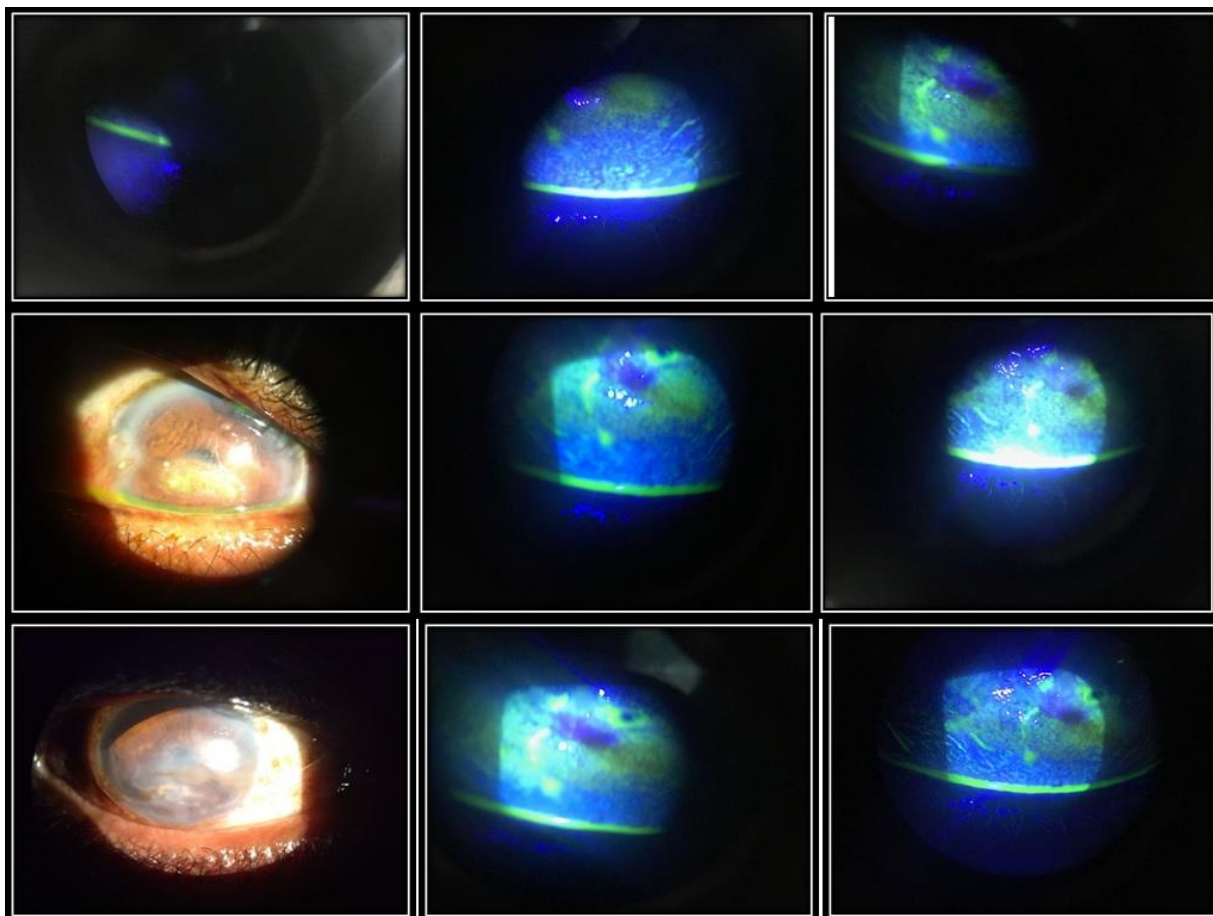


Fig. 2: Stages of spheroidal degeneration: Stage 1 (A); Stage 2 (B,C); Stage 3 (D,E,F); and Stage 4 (G,H,I)

In our study with 64 patients, a high proportion of 44 patients (68.75%) were diagnosed to have spheroidal degeneration, comprising all the four stages (Fig. 4).

Patients with stage 3 and stage 4 showed marked decrease in vision due to severe corneal involvement. Pseudoexfoliation patients showed powdery like fibrillar extracellular material deposition in the entire anterior segment area leading to deposits on the back surface of cornea, trabecular meshwork, anterior surface of iris, pupillary margin, posterior surface of iris, zonules and anterior surface of lens capsule. This poses greater risk for cataract surgery. The nucleus in PEX patients will be large with thin posterior capsule and sticky cortical matter. The dilation of pupil is restricted, due to the deposition of white fibrillary material in the stroma causing a mid-dilating pupil before cataract surgery. The zonules are weakened by the deposits, leading to phacodonesis or sometimes subluxated lens, which poses a challenging situation for the cataract surgeon. In patients with stage 3 and stage 4 spheroidal degeneration, the surface of cornea was irregular, which led to decrease in vision and also made intraocular surgeries difficult due to disturbance in the optical surface of the cornea. Symptoms due to spheroidal degenerations were high in patients with stage 3 and stage 4.

The prevalence of pseudoexfoliation, globally varies from 3.6% to 27%.⁵ The occurrence of spheroidal

degeneration in general population was 7.13% in a study done by Viswamithra et al.⁴ In our study, 68.75% showed spheroidal degeneration and we considered only those patients having pseudoexfoliation deposits. This observation showed us that there is a strong association for the occurrence of spheroidal degeneration, in patients with pseudoexfoliation syndrome. A study done by Sarowa et al,¹ the density of endothelial cell was significantly decreased, and there was morphological changes in endothelial cells causing pleomorphism and polymegathism of cells in PEX eyes, particularly when intraocular pressure was high, which we couldn't attain as we faced difficulty in measuring IOP using applanation tonometry in our patients with irregular surface of cornea with spheroidal degeneration. In another study by Sood et al, it was shown that spheroidal degeneration was very common in people exposed to excessive sunlight where ultra violet radiation is the causative agent.⁵ The present study was conducted in hot and dry climatic conditions, which is one of the factors for increased incidence of spheroidal degeneration and pseudoexfoliation in our cases.

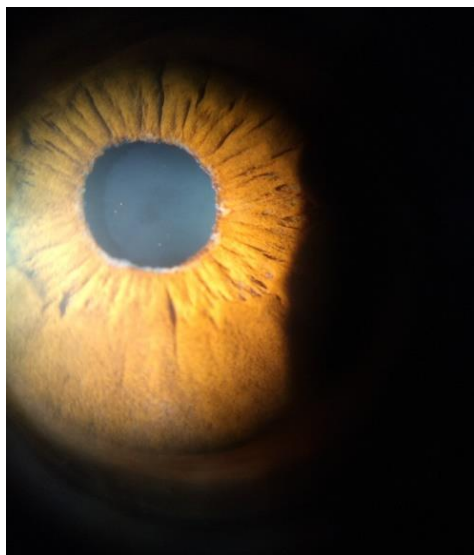

Fig. 3: Pseudoexfoliation material at pupil

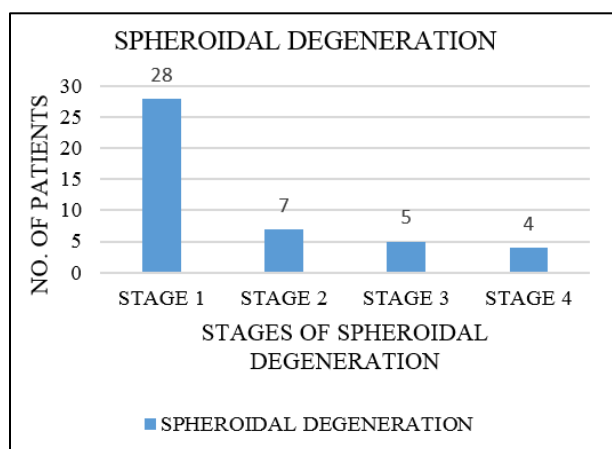


Fig. 4: Relative distribution of patients with four stages of spheroidal degeneration

Conclusion

Spheroidal degeneration is not a rare clinical condition. The present study shows that there is a strong association for the development of spheroidal degeneration in majority patients with pseudoexfoliation. It was also observed that the type 1 spheroidal degeneration was most common association and the pupillary margin was the common site for pseudoexfoliation material deposition in most of our

cases. Spheroidal degeneration, when present in association with pseudoexfoliation cases, causes significant ocular morbidity and reduces the quality of life of patients. The corneal involvement poses challenges to cataract surgeons and the chances of complications can be manifold, even with experienced hands.

Conflict of Interest: None.

References

1. Sarowa S, Manohar JM, Jain K, Singhal Y, Devathia D. Qualitative and quantitative changes of corneal endothelial cells and corneal thickness in pseudoexfoliation syndrome and pseudoexfoliation glaucoma. *Int J Med Sci Public Health* 2016;5(12):2526-30.
2. Oltulu R, Satirtav G, Kayitmazbatir ET, Bitirgen G, Ozkagnici A, Karaibrahimoglu A. Characteristics of the cornea in pseudoexfoliation syndrome. *Arq Bras Oftalmol* 2015;78(6):348-51.
3. Naumann GOH, Schrehardt US. Keratopathy in pseudoexfoliation syndrome as a cause of corneal endothelial decompensation. *Am J Ophthalmol* 2000;107(6):1111-24.
4. Vishwamithra P, Murthy SRC. Spheroidal degeneration – An Epidemiological study. *IOSR- JDMS* 2015;14(8):48-53.
5. Ritch R, Schrehardt US. Exfoliation Syndrome. *Surv Ophthalmol* 2001;45(4):265-315.
6. Sood T, Sharma RI, Mandeep T, Sood S, Sharma A. Climatic Keratopathy in Snow Laden Hilly Areas. *Int J Ophthalmol Eye Res* 2016;4(5):212-4.
7. Singh D, Singh M, Rudra SIS. Climatic Keratopathy. *IJO* 1979;27(4):180-4.
8. Mohan A, Jamil Z, Bhatanagar VC, Gajraj M. Prevalence of spheroidal degeneration of cornea and its association with other eye diseases in tribes of Western Rajasthan. *Ind J Ophthalmol* 2017;65(10):1010-4.
9. Lindberg JG. Kliniska undersökningar över depigmentering enav pupillarranden och genomlysbarheten av iris vid fall av avelersstarrsamt normala ögon hos gamla personer. In [Clinical studies of depigmentation of the pupillary margin and transillumination of the iris in cases of senile cataract and also in normal eyes in the aged]. Thesis. Helsinki, Finland: Helsinki University, 1917.
10. Datta LC(ed.). *Modern Ophthalmol* 3rd edition (Vol 1). New Delhi. Jaypee Brothers Medical Publishers (P) Ltd. 2005.

How to cite this article: Kumar HM, Madhumita M. Association of spheroidal degeneration in pseudoexfoliation cases. *Indian J Clin Exp Ophthalmol* 2019;5(2):186-9.