

## Laser peripheral iridotomy with and without laser iridoplasty in management of primary angle closure

Uma Sharan Tiwari<sup>1</sup>, Rashmi Kujur<sup>2,\*</sup>

<sup>1</sup>Professor and Head, <sup>2</sup>Assistant Professor, Dept. of Ophthalmology, G. R. Medical College, Gwalior, Madhya Pradesh, India

**\*Corresponding Author:**

Email: drrashtirkey@gmail.com

### Abstract

**Purpose:** To compare the efficacy and safety of laser peripheral iridotomy with or without laser peripheral iridoplasty in the treatment of eyes having primary angle closure.

**Materials and Methods:** Hundred eyes of 100 patients of primary angle closure were randomized to one of the two treatment options, iridotomy or iridotomy plus iridoplasty, and were followed up for at least 3 months. Main outcome measures were intraocular pressure, irido trabecular contact, peripheral anterior synechiae and complications.

**Result:** There was no significant difference between the two groups in the baseline data. The IOP was reduced from 24.74 $\pm$ 6.4 mm Hg to 19.32 $\pm$ 5.8 mm Hg in iridotomy group ( $p < 0.01$ ) and from 24.12 $\pm$ 6.4 mm Hg to 17.12 $\pm$ 8.4 mm Hg in iridotomy plus iridoplasty group ( $p < 0.01$ ) at the end of 3 month. Appositional closure was relieved in 75% eyes in iridotomy group and 88% eyes in iridotomy plus iridoplasty group. No change was observed in the extent of PAS after the laser treatment in any group. Increased pigmentation in angle was observed in 26% cases in iridotomy plus iridoplasty group as compared to only 5% cases in iridotomy group.

**Conclusion:** laser peripheral iridotomy plus iridoplasty leads to better control of intraocular pressure as compared to laser peripheral iridotomy alone in management of primary angle closure. Iridoplasty relieves irido trabecular contact but has no influences on the extent of peripheral anterior synechiae.

**Keywords:** ALPI, Laser iridoplasty, Laser peripheral iridotomy, Primary angle closure.

### Introduction

Primary angle closure (PAC) is characterized by apposition of the peripheral iris against the trabecular meshwork, resulting in obstruction of the aqueous outflow. The main mechanisms of PAC are pupillary block, plateau iris, lens-related and retrolenticular causes. The most common cause is pupillary block.<sup>1</sup> Recent advances in lasers have revolutionized the management of primary angle closure glaucoma.<sup>2,3</sup> Although Laser Peripheral Iridotomy (LPI) is mainstay of treatment of PAC, Argon laser peripheral iridoplasty (ALPI) which causes flattening of the peripheral iris and widening of the anterior chamber angle, has been tried as a mode of therapy in primary angle closure.<sup>4,5</sup> It is therefore hypothesized that LPI followed by ALPI may remove the pupillary block, address the plateau iris and may even break some peripheral anterior synechiae (PAS) to provide better control of the disease. Hence this prospective, randomized, interventional study was conducted to investigate if LPI followed by ALPI is better as compared to LPI alone in terms of control of intraocular pressure (IOP), relieving irido trabecular contact (ITC), breaking PAS and complications.

### Materials and Methods

This prospective, randomized, interventional study was conducted on 100 eyes of 100 cases of PAC attending glaucoma clinic. Diagnosis of PAC was established with the help of Goldmann applanation tonometry (GAT), gonioscopy including indentation gonioscopy, slit lamp examination including indirect

biomicroscopy and white on white 30-2 perimetry prior to commencement of treatment. Patients having history or signs of acute angle closure glaucoma viz. dilated and fixed pupil, sector atrophy of iris, pigmentary dusting of corneal endothelium or glaucomaflecken were excluded. Patients having any other ocular disorders that may have an effect on the structure or function of the drainage angle i.e. Uveitis, Lens dislocation were also excluded.

Eligible patients of PAC were randomized using a random number table created by SPSS statistical software as follows:

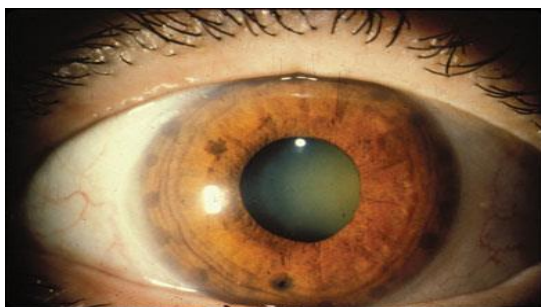
Group A: LPI group, 50 cases

Group B: LPI plus ALPI group, 50 cases

All laser procedures were performed by single ophthalmologist on an outpatient basis. Before LPI, in order to stretch the iris, 2% pilocarpine was instilled topically till the pupil showed no reaction to light. LPI was performed under topical anesthesia using Abraham iridotomy lens with Nd YAG laser. The preferred treatment site was superior nasal iris crypt. Treatment was initiated with a single 6 mJ pulse. The end point was liberation of iris pigments with a gush of aqueous. An opening of at least 0.2 mm was made.

In group B patients, 2 weeks after the LPI, ALPI was performed under topical anesthesia using Abraham iridotomy lens with a frequency double YAG Laser. The initial parameters for ALPI were 200 mw power, 0.2 seconds pulse duration and 200 micron spot size. The beam was focused at the most peripheral portion. The laser power was increased if there was no iris contraction visible. The power was reduced if pigment

release or bubble formation occurred. Treatment consisted of 24 spots over 360 degrees of iris, placed at least one burn width apart and avoiding large visible radial vessels. (Fig. 1)



**Fig. 1: ALPI marks placed one burn width apart**

IOP was checked 1 hour after laser treatment. Tab Acetazolamide 250 mg was given if IOP was more than 30 mm Hg. The laser treated eyes received topical anti-

glaucoma medication and steroid eye drops for seven days after laser treatment.

All the patients were followed every week for 4 weeks and then every month for at least 3 months. At each scheduled visit, visual acuity, GAT, gonioscopy and medical therapy and complications were recorded.

Statistical analysis system for windows was used. Data from three month follow up visit were used for statistical analysis. The mean and standard deviation were calculated for the variables: age and IOP. The median and 25% and 75% quartile range was calculated for data with non normal distribution i.e. PAS. Student t test was used to determine the statistical significance (normal distribution) or rank sum test (non normal distribution). The chi square test was used to test the categorical data. P value < 0.5 was considered to be statistically significant.

## Observations

**Table 1: Demographic and base line data**

Treatment Groups	No. of Eyes	Mean Age	Gender Ratio (M:F)	Refractive Error			Mean IOP +/-SD (mmHg)
				Hypermetropia	Myopia	Emmetropia	
Group A (LPI Alone)	50	56	12:38	47	2	1	24.74+/-7.2
Group B (LPI plus ALPI)	50	58	10:40	46	2	2	24.12+/-8.6

In the present study, a female preponderance was noted. Majority of patients were hypermetropic. The mean pre

treatment IOP was 24.74 and 24.12 mm Hg in group A and group B, respectively.

**Table 2: Distribution of cases as per gonioscopy findings.**

Treatment groups	Appositional Closure	Synechial Closure in degrees			Total	Median of PAS (quartile range) in clock hours
		<90	90-180	>180		
Group A	24	9	9	8	50	4.5 (2-9)
Group B	25	8	10	7	50	5.0 (3-9)

Approximately 50% cases were found to have synechial closure in present study. The extent of PAS was 4.5 and 5 clock hours in group A and group B, respectively.

Sub group analysis revealed nearly equal distribution of synechiae.

**Table 3: IOP lowering at 3 months**

Angle characteristics	Group A			Group B		
	Mean IOP Before T/t	Mean IOP After T/t	Mean IOP lowering%	Mean IOP Before T/t	Mean IOP After T/t	Mean IOP lowering%
Appositional Closure	24.00	15.76	28%	23.00	13.70	42%
Synechial Closure <90	24.50	18.80	25%	23.70	14.50	38%
Synechial Closure 90-180	25.00	23.00	14%	25.00	22.00	15%
Synechial Closure >180	27.00	24.60	13%	27.00	25.00	14%
Total mean	24.74+/-7.2	19.32+/-5.8	22%	24.12+/-8.6	17.12+/-8.4	31%

This table shows the mean IOP lowering in various sub groups following laser treatment. Eyes with appositional closure showed a better lowering of IOP in group B as compared to group A i.e. 42% vs. 28%. Likewise, eyes with PAS <90 degree, showed a better

lowering of IOP in group B as compared to group A i.e. 38% vs. 25%. However, in eyes having PAS > 90 degree, the IOP lowering was approximately 14% in both the groups. The overall lowering of IOP was found to be 22% in group A and 31% in group B.

**Table 4: Effect of Laser procedure on appositional Closure**

	No of cases of appositional closure	appositional closure relieved after laser procedure		Remarks
		Number	%	
Group A	24	18	75%	4 cases of plateau iris
Group B	25	22	88%	5 cases of plateau iris

In the present study, appositional closure was relieved in 75% eyes in group A and 88% eyes in group B.

**Table 5: Effect of Laser procedures on PAS**

Extent of PAS (in degrees)	Group A (n=26)		Group B (n=25)	
	Before T/t	After T/t	Before T/t	After T/t
Synechial Closure <90	9	9	8	8
Synechial Closure 90-180	9	9	10	10
Synechial Closure >180	8	8	7	7

In the present study, no change was recorded in the extent of PAS after the laser treatment.

**Table 6: Complications**

Complications	Group A		Group B	
	Number	%	Number	%
Post laser IOP spike	26	52	30	60
Corneal Endothelial burn	01	02	01	02
Increased Pigmentation in angle	03	06%	13	26%

Increased pigmentation in angle was observed in 26% cases in group B as compared to only 6% cases in group A.

## Discussion

On analysis of demographic and base line data in the present study it was observed that most of the patients of PAC are female hypermetropes with a mean age of 58 years. As with most chronic diseases, the prevalence of disease increases with increasing age due to the increase in the cumulative number of persons with disease.<sup>6</sup> Lenticular changes could be responsible for this finding.<sup>7</sup> An association of increasing hypermetropia with the angle closure disease would be expected taking into account that hyperopic eyes are likely to be shorter and therefore at greater risk of angle closure disease.<sup>6</sup> Due to the biometric differences between genders, women appear to have shorter eyes and a shallower anterior chamber depth than men.<sup>6</sup>

In present series, eye having appositional angle closure showed significant IOP lowering from base line i.e. 28% in group A and 42% in group B which is statistically significant ( $P < 0.01$ ). The difference in IOP lowering between two groups was also significant ( $P < 0.01$ ). The incidence of plateau iris configuration was 9% in present series. Plateau iris configuration can be recognized by an occluded angle despite a patent peripheral iridotomy where indentation gonioscopy reveals a characteristic double hump in iris contour. Thomas et al stated that although laser iridotomy is

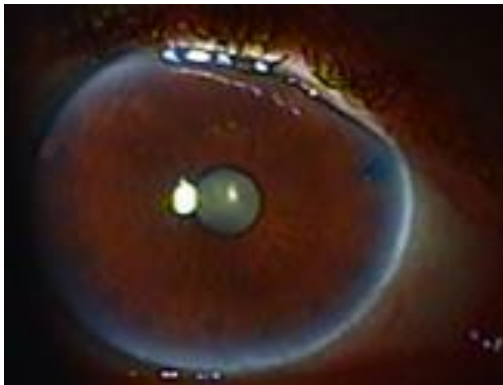currently the first line of treatment, many eyes will continue to have appositional angle closure and an additional treatment option might be necessary. Iridoplasty opens the drainage angles where peripheral anterior synechia are not present (or between them if they are) almost in all cases.<sup>8</sup> A 20% IOP reduction on average has been reported. Laser iridoplasty is a useful procedure independent of the underlying mechanism, leading to angle widening and moderate IOP reduction in most cases.<sup>9</sup> It is evident that addition of ALPI results in better IOP lowering because it corrects the plateau iris configuration.

In present series, eyes with synechiae <90 degree, LPI with ALPI showed better IOP lowering as compared to LPI alone ( $P < 0.01$ ). H C Agarwal states that the success of iridoplasty in the chronic stage depends upon the extent of PAS, the degree of optic disc cupping and visual field changes. The lesser these changes, the better the chances of success of iridoplasty. He also recommended that cases of sub acute angle closure and chronic angle closure with PAS <180 degree and normal fields may be safely subjected to Argon laser iridoplasty as an alternative to surgery. However, the procedure may be differed in eyes with PAS >180 degree, CD ratio 0.5 and in presence of advanced glaucomatous field defects.<sup>10</sup> LPI followed by ALPI should be considered as an alternative to surgery in subjects having PAS less than 90 degree.

None of the patients with extensive PAS i.e. synechiae 90-180 degree and > 180 degree, showed

significant IOP lowering in present series. This could be attributed to the fact that synechiae are permanent and prevent the pulling of the iris from chamber angle thus continue to obstruct the aqueous flow even after ALPI.

In present series, the ITC of appositional closure type was relieved in 75% cases in LPI group and 88% cases in LPI plus ALPI group. It was due to correction of the plateau iris after laser iridoplasty done in group B. As per Liwan eye study, residual iridotrabecular contact is present in as high as 59% cases even after a successful LPI. In such cases, argon laser peripheral iridoplasty has been found to be effective by tissue contraction resulting in pulling of the peripheral iris away from the trabecular meshwork, thereby opening the anterior chamber angle.<sup>11</sup> Ritch and associates have described the mechanism of relieve of crowding in laser iridoplasty. Laser iridoplasty thins out the peripheral iris stroma thereby creating space in angle recess<sup>12</sup>. It is evident from the present study and other studies<sup>12-15</sup> that nearly 60% of the cases of PAC have residual iridotrabecular contact after LPI which may be due to PAS, plateau iris configuration or other mechanisms such as antero placement of the lens or anterior rotation of ciliary process. Addition of iridoplasty to LPI can relieve plateau iris configuration and thereby increase the success in terms of relieving ITC and lowering IOP. (Fig. 2)



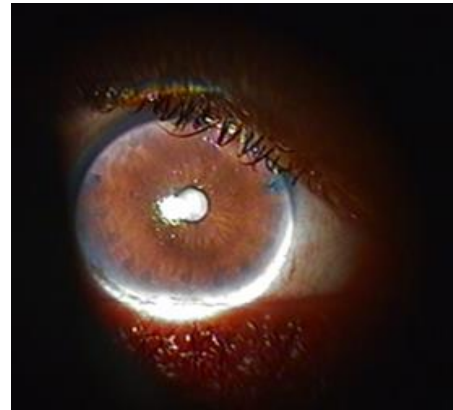
**Fig. 2: Irido trabecular contact relieved after LPI plus ALPI**

In present series, no change in extent of PAS was observed after laser procedure in both the groups.

No serious complication such as malignant glaucoma was encountered in present series. Increased pigmentation of the chamber angle was more common after iridoplasty as compared to LPI which may be due to more extensive treatment of iris in iridoplasty group. Post laser IOP rise was expected and was managed with topical anti glaucoma medication.

To summarize, addition of laser iridoplasty to laser iridotomy increases the success in terms of IOP lowering and relieving the underlying mechanisms of

PAC but presence of PAS >90 degree is a limiting factor.



**Fig. 3: LPI and ALPI**

**Source of Support:** Nil

**Conflict of Interest:** None

## References

1. Pan Y, Varma R. Natural history of glaucoma. *Indian J Ophthalmol.* 2011;59(Suppl S1):19-23.
2. Quigley H.A. Long term follow up of Laser iridotomy. *Ophthalmology.* 1981;88(3):218-224.
3. Tomey KF, Traverso CE, Shammas IV: Nd: YAG laser iridotomy in treatment and prevention of angle closure glaucoma. *Arch Ophthalmol.* 1987;105(4):476-481.
4. Ritch R. Argon laser treatment for medically irresponsive attacks of Angle Closure Glaucoma. *Am J Ophthalmol.* 1982;94(2):197-204.
5. Araia F, Balestrazzi E, Scordia G, Recupero SM: Argon laser techniques in narrow angle glaucoma. *Glaucoma.* 1987;9:53-55.
6. Ronnie G, Ve RS, Velumuri L, Asokan R, Vijaya L. Importance of population-based studies in clinical practice. *Indian J Ophthalmol.* 2011;59(Suppl S1):11-18.
7. George R, Ramesh S Ve, and Viajaya L. Glaucoma in India: Estimated burden of disease. *J Glaucoma.* 2010;19(6):391-397.
8. Thomas R, Arun T, Muliyl J, George R. Outcome of laser peripheral iridotomy in chronic primary angle closure glaucoma. *Ophthalmic Surg Lasers* 1999;30(7):547-553.
9. Prado VG, Dorairaj S, Biteli LG, Sousa AKS, Moreno PAM, Lopes FS, Prata TS. Role of Laser Iridoplasty in the Management of Angle Closure Mechanisms other than Pupillary Block. *J Curr Glaucoma Pract.* 2014;8(2):82-84.
10. Agarwal H C, Kumar R, Kalra V K, Sood N N. Argon laser iridoplasty: A primary mode of therapy in primary angle closure glaucoma. *Indian J Ophthalmol.* 1991;39(3):87-90
11. He M, Friedman DS, Ge J, Huang W, Jin C, Cai X, et al. Laser peripheral iridotomy in eyes with narrow drainage angles: Ultrasound biomicroscopy outcomes. The Liwan Eye Study. *Ophthalmology.* 2007;114(8):1513-1519.
12. Ritch R, Tham CC, Lam DS. Argon laser peripheral iridoplasty (ALPI): an update. *Surv Ophthalmol.* 2007;52(3):279-288.

13. See JL, Aquino MD, Aduan J, Chew PT. Management of angle closure glaucoma. *Indian J Ophthalmol*. 2011;59(Suppl S1):82-87.
14. Ritch R, Tham C, Lam D. Long-term success of argon laser peripheral iridoplasty in the management of PIS. *Ophthalmology*. 2004;111(1):104-108.
15. Ramakrishnan R, Mitra A, Abdul Kader M, Das S. To Study the Efficacy of Laser Peripheral Iridoplasty in the Treatment of Eyes With Primary Angle Closure and Plateau Iris Syndrome, Unresponsive to Laser Peripheral Iridotomy, Using Anterior-Segment OCT as a Tool. *J Glaucoma*. 2016;25(5):440-446.

**How to cite this article:** Tiwari US, Kujur R. Laser peripheral iridotomy with and without laser iridoplasty in management of primary angle closure. *Ind J Clin Exp Ophthalmol*. 2018;4(3):379-383.