

A study to evaluate safety and efficacy of corneal collagen cross-linking with riboflavin in keratoconus patients

Geetika Srivastava¹, Harsimran Kaur Bhatia^{2,*}, Uma Sridhar³

¹Senior Resident, Dept. of Ophthalmology, GMERS Medical College, Himmatnagar, Gujarat, ²Consultant, Sunetra Eye Centre, Ghaziabad, Uttar Pradesh, ³Senior Resident, ICARE Eye Hospital and Post Graduate Institute, Noida, Uttar Pradesh, India

***Corresponding Author:**

Email: geetshri556@gmail.com

Abstract

Introduction: Keratoconus is a disorder of progressive corneal steepening, resulting in cone shaped protrusion of cornea, corneal thinning, myopia and astigmatism.

Objectives: To assess the efficacy and safety of corneal collagen cross-linking with Riboflavin in the management of keratoconus.

Materials and Methods: The study was conducted at an eye hospital over a period of 22 months to evaluate utility of corneal collagen cross-linking in treatment of keratoconus. Study group included 10 eyes (6 right and 4 left) of 8 patients (6 males and 2 females) with one year follow-up.

Results: Mean age of study population was 24.25 years (SD=5.97; SE=2.11). The mean logMAR UCVA prior to CXL was 0.85 which improved to 0.57 at 12 months. Mean baseline BCVA was 0.464 logMAR, this improved to 0.170 logMAR at 12 months. At baseline a mean SimK astigmatism was 4.99 (SD= 2.56) and this decrease to 4.72 at 12 months.

Conclusion: Present study showed improved visual acuity (both UCVA and BSCVA), stable topographic parameters, stable visual acuity and stable endothelial cell counts over a period of 12 months follow up, indicating that corneal collagen cross-linking with riboflavin is a safe and effective treatment option for keratoconus.

Keywords: Corneal collagen cross-linking and visual acuity, Keratoconus.

Introduction

Keratoconus is a disorder characterized by changes in corneal collagen structure and organization resulting in corneal thinning, induced myopia and both regular and irregular astigmatism.¹⁻³ A reduced number of collagen cross-links and pepsin digestion higher than normal induce an overall structural weakness of the corneal tissue, resulting in a stiffness that is only 60% that of the normal cornea.⁴ Keratoconus affects both genders and gender distribution is variable, Some studies have not found any differences in the prevalence between genders^{5,6} while others have found either a greater prevalence in females^{7,8} or in males.⁹⁻¹² Various modalities like spectacles, contact lenses, specialized contact lenses like Rose K lens and collagen cross linking are available for treatment of keratoconus.

Corneal collagen cross-linking with ultraviolet-A is a latest modality which is being evaluated for the treatment of keratoconus. Other modalities did improve the visual outcome but could not curb the progression of the underlying disease process.¹³ Collagen cross linking increases the biomechanical strength of the human cornea by 300% by the combined action of a photosensitizing substance (riboflavin) and UV light, from a solid state UV-A source.¹⁴

In this study we have tried to evaluate the effect of corneal collagen cross-linking on keratoconus eyes in terms of various parameters like visual acuity (both uncorrected and best-corrected), corneal thickness and endothelial cell counts.

Materials and Methods

A prospective, clinical interventional study was done over a period of 22 months (January 2011 To October 2012) at ICARE eye hospital and post graduate institute NOIDA to evaluate corneal collagen cross-linking in keratoconus. Our final study group included 10 eyes (6 right and 4 left) of 8 patients (6 males and 2 females) who completed 1 year follow-up.

Inclusion Criteria: Cases of progressive keratoconus (increase in maximum keratometry of 1.00 diopter in one year along with deterioration of BCVA), Age group of 16-40 years and corneal thickness of at least 400µ.

Exclusion Criteria: Central corneal thickness < 400 µm. Maximal keratometry readings (K) > 60 D, apical corneal scarring, associated ocular surface disorders e.g., vernal keratoconjunctivitis, extremes of ages: < 16 years or > 40 years of age, pregnancy, diabetes mellitus, patients who lost follow-up.

Preoperative Assessment: Meticulous clinical history, systemic examination, visual acuity (Uncorrected and best spectacle corrected visual acuity) testing with Snellen's test types, evaluation of adenexa, anterior segment, fundus examination by indirect ophthalmoscopy, retinoscopy and keratometry was done.

Corneal topography was done with ORBScan. Parameters documented were- SimK astigmatism, Kmax (steepest meridian), Kmin (flattest meridian), Ultrasonic pachmetry was also done. Specular microscopy was done with specular microscope and

endothelial cell counts and central corneal thickness were documented.

Pre-anaesthetic check-up was done in all the patients. Informed consent was taken.

Surgical Procedure: Conjunctival-cul-de sac was cleaned with 5% povidone-iodine solution. Using self-retaining lid speculum, eye was exposed. Topical anaesthetic (Proparacaine 0.5%) was instilled. Using a blunt spatula (hockey stick), central 8 mm of the epithelium was peeled off. (Fig. 1) LASEK well was placed on cornea and filled with riboflavin [Riboflavin/Vitamin B2 > 0.1%, Dextran-500 20% available as 3ml single use isotonic solution (pH 7)] (Fig. 2). The well was replenished every 2 minutes for 20 minutes and then removed.

The UV device was used to irradiate the cornea, range of power 2.66-3.2mW/cm² and distance between the device and the cornea was set between 5-7 cm. Riboflavin drops were instilled on the cornea at intervals of 2 minutes and continued for 30 minutes from the start (Fig. 3). Exposure of the UV-A light stopped automatically at the end of 30 minutes. A bandage contact lens was placed to aid the epithelial healing and decrease discomfort.

Post-operative Management: Patients were prescribed topical steroids, topical antibiotic drops, oral antibiotics, lubricating eye drops, mydriatic eye drops, and oral analgesics.

Post-operative Evaluation: Post-operatively patients were seen at 1 week, 1 month, 3 months, 6 months and 12 months post-surgery. Following parameters were assessed at each visit

1. Visual acuity with Snellen's visual acuity chart, UCVA, BSCVA.
2. Corneal topography, pachymetry and specular microscopy.

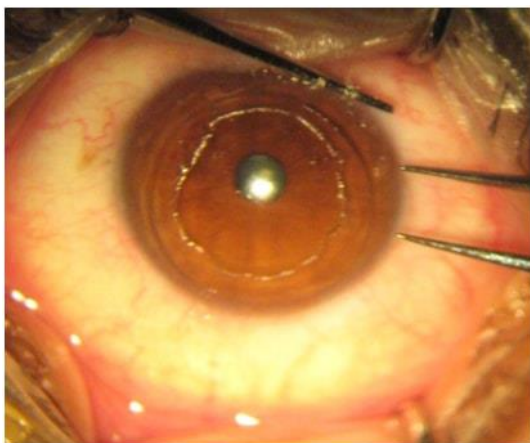


Fig. 1: Epithelial debridement of central cornea

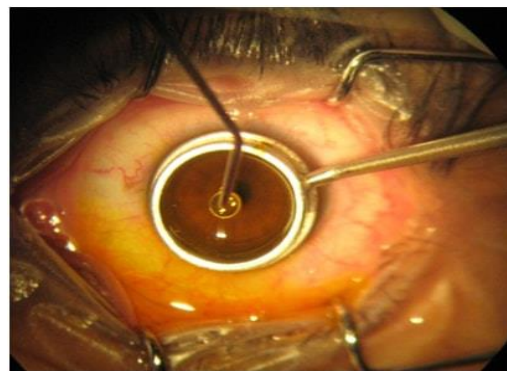


Fig. 2: Instillation of riboflavin drops

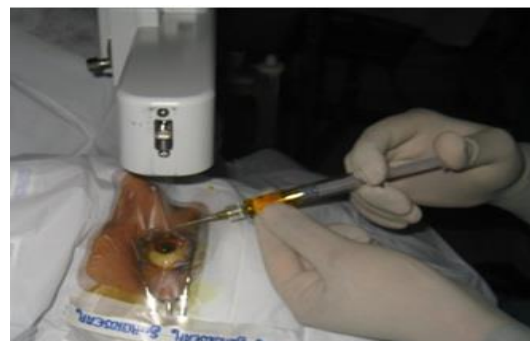

Fig. 3: Instillation of Riboflavin drops after focusing UV light

Result

In our study group of 10 eyes, 25% subjects were females and 75% subjects were males. In our group 2 patients (25%) were in the age group of 16-20 years, 4 patients (50%) were in the age group of 21-25 years and 2 patients were in the age group of 26-40 years (Table 1). Mean age of our study population was 24.25 years (SD=5.97; SE=2.11). In our study population, 4 left eyes (40%) and 6 right eyes (60%) were operated.

The mean logMAR UCVA prior to CXL was 0.85 which improved to 0.87 at 1 week, 0.81 at 1 month, 0.55 at 3 months, 0.50 at 6 months and 0.57 at 12 months. Changes compared to baseline were statistically significant at 3, 6 and 12 months ($p=0.16$, $p=0.05$ and $p=0.007$ respectively). At 1 week post-op visit UCVA in 8 eyes (80%) showed stability, 1 eye (10%) deteriorated and 1 eye (10%) improved as compared to baseline. Trend shifted towards improvement of UCVA and by the end of 12 months all 10 eyes (100%) showed improvement from baseline (Fig. 4).

Mean baseline BCVA was 0.464 logMAR, this improved to 0.377 at 1 week, 0.389 logMAR at 1 month, 0.230 logMAR at 3 months, 0.290 logMAR at 6 months and 0.170 logMAR at 12 months. Changes with respect to baseline were significant at 3 months ($p=0.35$), 6 months ($p=0.11$) and 12 months ($p=0.12$). At 1 week, 4 eyes (40%) showed stability, 4 eyes (40%) improved and 2 eyes (20%) deteriorated with respect to baseline. At the end of 12 months, 8 eyes (80%)

showed improvement of BCVA and 2 eyes (20%) showed stability with respect to baseline (Fig. 5).

At baseline a mean SimK astigmatism was 4.99 (SD= 2.56) and this increased to 5.56 at 1 week post-op ($p=0.386$), 5.17 at 1 month ($p=0.358$), 4.86 at 3 months ($p=0.953$), 4.82 at 6 months ($p=0.284$) and 4.72 at 12 months ($p=0.028$). These changes from baseline to 12 months was statistically significant. A change of <0.5 was considered stable and an increase of $>$ or <0.5 was taken as deterioration or improvement respectively. Based on this, compared to baseline 5 eyes (50%) showed stability and 5 eyes (50%) showed improvement as compared to baseline (Fig. 6).

A change of <0.5 was considered stable and an increase of $>$ or <0.5 was taken as deterioration or improvement respectively. Based on this, compared to baseline 5 eyes (50%) showed stability and 5 eyes (50%) showed improvement as compared to baseline.

In our study mean Kmax dropped from 51.11 (SD= 3.88) at baseline to 50.58 (SD=0.41) at final outcome visit at 12 months. Throughout this period, the value of Kmax was lesser as compared to baseline at every visit but the change was statistically insignificant ($p>0.05$).

In our study population Kmin decreased from a mean value of 46.1 (SD=2.00) at baseline to 46.05 (SD=1.98) at 12 months. At every visit, the change from baseline was statistically insignificant ($p>0.05$) till 1 month post-op. At 3 months and 6 months mean Kmin was 45.72 (SD=2.03, $P=0.40$) and 45.08 (SD=3.07, $p=0.03$) respectively. At 12 months, Kmin was 46.05 (SD=1.98, $p=1.00$) which was statistically insignificant as compared to baseline.

CCT values dropped from mean baseline ultrasonic pachymetry of 463.4 (SD=25.90) to 439.9 (SD=28.44) at 1 week, 446.8 (SD=20.90) at 1 month and these changes were statistically significant compared to baseline ($p=0.025$, $p=0.022$ respectively). At 3 months, 6 months and 12 months, these changes were statistically insignificant as compared to baseline ($p=0.721$, $p=0.259$ and $p=0.507$ respectively).

Endothelial cell count changed from a baseline value of 2730.9 (SD=386.86) to 2711.8 (SD=394.47) at 12 months and this change was statistically insignificant ($p=0.44$) (Table 2).

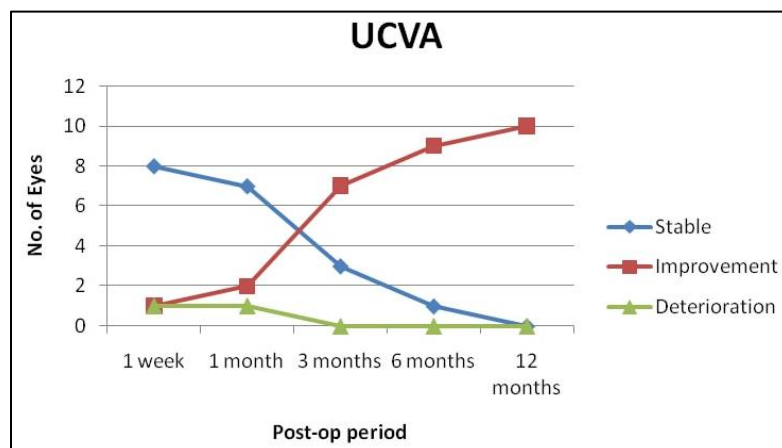


Fig. 4: Distribution of eyes based on improvement / deterioration/ stability as compared to baseline at every visit

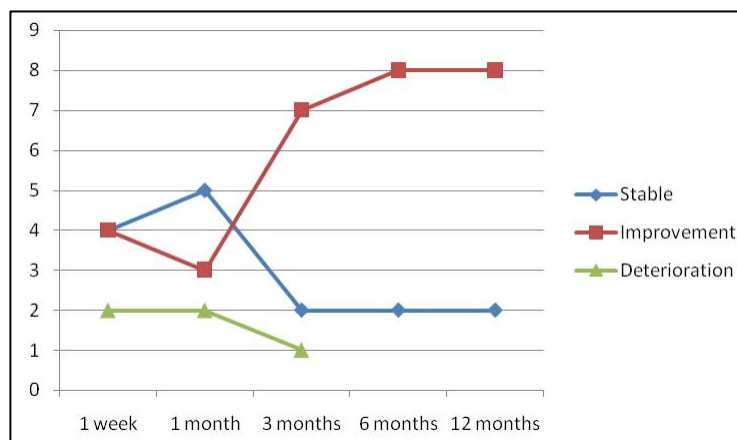


Fig. 5: Distribution of eyes according to the change in BCVA from baseline at every visit

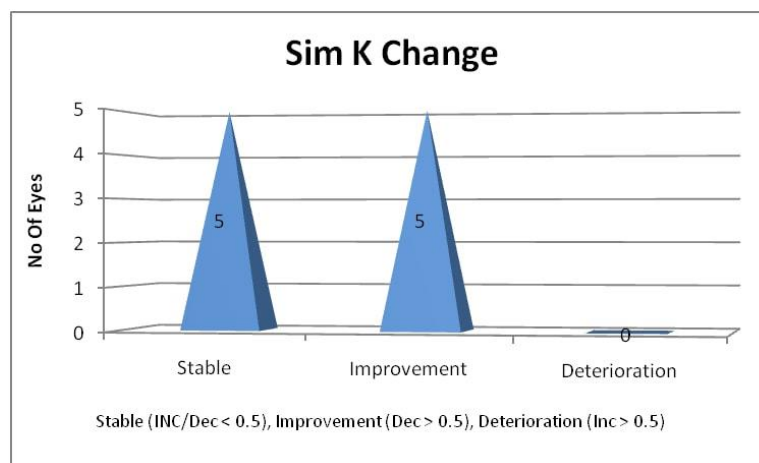


Fig. 6: Trends of Sim K astigmatism over a period of 12 months

Table 1: Gender and age distribution (n=8)

Age group in years	No. of cases	Percentage	Male	Female
16-20	2	25	2	0
21-25	4	50	3	1
26-40	2	25	1	1
Total	8	100	6	2

Table 2: Trends of endothelial cell count change from baseline to 12 months (n=10)

	Endothelial Cell Counts (Pre-Op)	Endothelial Cell Counts (12 months)
Range	2206 - 3380	2234 - 3383
Mean	2730.9	2711.8
Standard Deviation	386.86	394.47

Discussion

Our study group comprised of 10 eyes of 8 patients. Two patients were taken up for the procedure for both their eyes at different point of time.

The mean pre-operative UCVA was 0.85 logMAR (6/36 Snellen's acuity). At 1 week follow-up, UCVA remained unchanged in 8 (80%) eyes, improved in 1 (10%) eye. In 1 (10%) eye UCVA decreased and this could possibly be explained by the superficial punctate keratitis in this patient, which is a part of healing process of the epithelium following debridement. By 6 months, all 10 (100%) eyes showed improvement from baseline. At final outcome visit at 12 months, 9 (90%) eyes showed improvement from baseline. By the end of 12 months, a mean improvement of 2 Snellen's lines from baseline was seen and this change was statistically significant ($P=0.007$).

Best Spectacle Corrected Visual Acuity (BSCVA):

The mean BSCVA at baseline was 0.5 logMAR (Snellen visual acuity-6/18). At 1 week, BSCVA showed improvement from baseline in 4 eyes (40%), remained unchanged in 4 eyes (40%) and worsened in 2 eyes (20%). The worsening in one of these eyes could be explained by the presence of superficial punctate keratitis at 1 week post-operatively. The vision drop in the other eye could be explained by the high

astigmatism in this patient. At 12 months, mean BSCVA was logMAR 0.17 ± 0.13 . 8 eyes (80%) showed improvement in BSCVA as compared to baseline. 2 eyes (20%) showed no change from baseline. So, a mean improvement of 2 Snellen's lines from baseline was seen and this change was statistically significant ($P=0.012$).

For both UCVA and BSCVA, significant changes were seen at 3, 6 and 12 months, this could be attributed to restoration of epithelial thickness, disappearance of corneal edema and collagen compaction which occurs around 3 months after the procedure.¹⁵

According to Hoyer et al,¹⁶ in their results from Dresden study, BCVA improved significantly in at least one line or remained stable (i.e., no line loss) in the 1st year in 48.9% and 23.8%, respectively. Compared to the results of this study, our results showed at least one line improvement in 8 (80%) eyes and stability in 2 eyes (20%) eyes.

Wollensak et al¹⁷ also demonstrated 1.26 ± 1.5 lines mean improvement in visual acuity at the final outcome visit (mean follow-up 23.2 ± 12.9 months). In our study a 2 line improvement was seen in both UCVA and BSCVA in a period of 12 month follow-up.

Vinciguerra et al¹⁸ showed UCVA change from 0.77 ± 0.18 logMAR at baseline to 0.57 ± 0.16 logMAR at 12 months which corresponded to an improvement by approximately one Snellen line. Mean baseline BSCVA was 0.28 ± 0.09 logMAR which improved to 0.14 ± 0.08 at 12 months, which also corresponded to an improvement by approximately one Snellen line. In our study baseline UCVA improved from 0.85 ± 0.28 to comparable 0.55 ± 0.18 ($p=0.007$) and baseline BSCVA improved from 0.46 ± 0.31 to 0.17 ± 0.13 , giving us a mean improvement of 2 lines of UCVA and BSCVA. The results shown by this study are comparable to our results.

Greenstein et al¹⁹ showed an improvement in UCVA by ≥ 2 Snellen lines in 25.4% eyes and worsening by ≥ 2 Snellen lines in 8.5% whereas our results showed an improvement of ≥ 2 snellen lines in 5 eyes (50%). BSCVA improvement by ≥ 2 Snellen lines was seen in 21.1% eyes (85). However, in our study similar results ie ≥ 2 snellen's lines are seen in 5 eyes (50%) which points towards better results in our study.

Topographic analysis revealed that mean Sim K astigmatism showed no significant change upto 6 months but at 12 months it showed a significant decrease as compared to baseline (4.99 ± 2.56 to 4.72 ± 2.49 ; $p=0.028$).

In our study mean Kmax decreased from 51.11 ± 3.87 D at baseline to 50.58 ± 4.01 D at 12 months. At 12 months, 3 eyes (30%) had decreased, 6 eyes (60%) showed no change and 1 eye (10%) showed worsening of Kmax when compared to baseline. In the eye that showed the increase in Kmax, the change didn't exceed 0.8 D. Overall, the change in Kmax values from baseline to 12 months was not statistically significant ($P=0.31$) indicating a stabilization of topographic parameters and hence the control of keratoconus progression.

Kmin (minimum K) values also followed the same trend as Kmax. Though the mean Kmin decreased from 46.10 ± 2.00 at baseline to 46.05 ± 1.98 at 12 months but this change was not statistically significant ($p=1.00$). Average K values also showed stability from baseline to 12 months ($p=0.79$).

Wollensak et al¹⁷ (2003) in their treatment of advanced keratoconic eyes (maximum K value, 48–72 dioptres) observed that in all treated eyes, the progression of keratoconus was at least stopped. In 16 eyes (70%) regression was seen with a reduction of the maximal keratometry readings by 2.01 dioptres. Our results, showed a regression of keratoconus in 3 eyes (30%) and stability in 6 eyes (60%). Comparing these two studies it has been seen that the percentage of eyes showing stability was more as profound in our study (60%) as compared to regression which was seen in only (20%).

In our study, we have measured central corneal thickness using ultrasonic pachymetry. Using ultrasonic pachymetry, a statistically significant decrease in CCT

was found at 1 week post-op ($P=0.025$) as values decreased from 463.40 ± 25.90 to 463.10 ± 27.12 ($p=0.51$) and this could be attributed to the keratocyte apoptosis occurring in the procedure. From 1 month onwards, the CCT starts improving and by 3 months there is complete recovery of corneal thickness. At and beyond 3 months, all the changes from baseline were statistically insignificant ($P=0.51$ at 12 months) indicating that the recovery of corneal thickness was complete by 3 months and beyond that no changes in corneal thickness took place. So, the values at 6 and 12 months showed a stabilization of CCT as compared to baseline. Greenstein et al²⁰ (2011) also demonstrated a significant drop in CCT from baseline to 1 week followed by gradual recovery upto 12 months but the change from baseline to 12 months was not statistically significant. Endothelial cell counts changed from baseline value of 2730.90 ± 386.857 to 2711.80 ± 394.46 at 12 months and this drop was statistically insignificant ($P=0.444$). Our results are comparable to most other studies that validate the safety of endothelium in CXL.^{21,22} Wollensak et al¹⁷ (2003) found no effect of CXL on endothelial cell counts. Caporossi et al²¹ (2006) also showed no significant change in endothelial counts at 6 months followup. Wittig Silva et al²³ (2008) also found no significant change in endothelial counts. So all these studies point towards the safety of CXL on endothelium.

Conclusion

The conservative treatment options do not prevent progression of keratoconus. Surgical options like keratoplasty and Intracorneal ring segments are effective in reducing astigmatism but carry the disadvantages of the complications associated with these surgical procedures. Present study showed favorable outcomes in terms of improved visual acuity (both UCVA and BSCVA), stable topographic parameters, stable visual acuity and stable endothelial cell counts at 12 months hence indicating efficacy and safety of CXL. Further trials are needed with larger number of subjects and longer follow up time to prove the efficacy and safety of the procedure in Indian population.

References

1. Tuori AJ, Virtanen I, Aine E, et al. The immunohistochemical composition of corneal basement membrane in keratoconus; *Curr Eye Res.* 1997;16(8):792–801.
2. Cheng EL, Maruyama I, SundarRaj N, et al. Expression of type XII collagen and hemidesmosome-associated proteins in keratoconus corneas. *Curr Eye Res.* 2001;22(5):333–40.
3. Radner W, Zehetmayer M, Skorpik Ch, Mallinger R. Altered organization of collagen in apex of keratoconus corneas. *Ophthalmic Res.* 1998;30(5):327–32.
4. Andreassen TT, Simonsen AH, Oxlund H. Biomechanical properties of keratoconus and normal corneas. *Exp Eye Res.* 1980;31(4):435–41.

5. Kennedy RH, Bourne WM, Dyer JA. A 48-year clinical and epidemiologic study of keratoconus. *Am J Ophthalmol.* 1986;101(3):267–73.
6. Li X, Rabinowitz YS, Rasheed K, Yang H. Longitudinal study of the normal eyes in unilateral keratoconus patients. *Ophthalmology.* 2004;111(3):440–446.
7. Krachmer JH, Feder RS, Belin MW. Keratoconus and related non-inflammatory corneal thinning disorders. *Surv Ophthalmol.* 1984;28(4):293–322.
8. Stein HA, Stein RM, Freeman MI. The ophthalmic assistant: a text for allied and associated ophthalmic personnel. Canada: Elsevier Mosby;2006. p.396.
9. Owens H, Gamble G. A profile of keratoconus in New Zealand. *Cornea.* 2003;22(2):122–125.
10. Weed KH, Mc Ghee CN. Referral patterns, treatment management and visual outcome in keratoconus. *Eye.* 1998;12(4):663–668.
11. Pearson AR, Soneji B, Sarvananthan N, Sandford-Smith JH. Does ethnic origin influence the incidence or severity of keratoconus? *Eye.* 2000;14(4):625–628.
12. Wagner H, Barr JT, Zadnik K. Collaborative longitudinal evaluation of keratoconus (CLEK) study: methods and findings to date. *Contact Lens Anterior Eye.* 2007;30(4):223–232.
13. Rabinowitz YS. Videokeratographic indices to aid in screening for keratoconus. *J Refractive Surg.* 1995;11(5):371–379.
14. Wollensak G, Spoerl E, Seiler T. Riboflavin/ ultraviolet A induced collagen cross linking for the treatment of keratoconus. *Am J Ophthalmol.* 2003;135(5):620–627.
15. Mazzota C, Balestrazzi A, Traversi C, et al. Treatment of progressive keratoconus by riboflavin- UVA – induced crosslinking of corneal collagen ultrastructural analysis by Heidelberg, retinal tomography II in vivo confocal microscopy in humans. *Cornea.* 2007;26(4):390–397.
16. Hoyer A, Raiskup-Wolf F, Spoerl E, Pillunat LE. Collagen cross-linking with riboflavin and UVA light in keratoconus. Results from Dresden. *Ophthalmologe.* 2009;106(2):133–140.
17. Wollensak G, Spoerl E, Seiler T. Riboflavin/ ultraviolet A induced collagen cross linking for treatment of keratoconus. *Am J Ophthalmol.* 2003;135(5):620–627.
18. Vinciguerra P, Albè E, Trazza S, Rosetta P, Vinciguerra R, Seiler T, Epstein D. Refractive, topographic, tomographic, and aberrometric analysis of keratoconic eyes undergoing corneal cross-linking. *Ophthalmology.* 2009;116(3):369–378.
19. Greenstein SA, Fry KL, Hersh PS Corneal topography indices after corneal collagen cross-linking for keratoconus and corneal ectasia: one-year results. *J Cataract Refract Surg.* 2011;37(7):1282–90.
20. Greenstein SA, Shah VP, Fry KL, Hersh PS. Corneal thickness changes after corneal collagen cross-linking for keratoconus and corneal ectasia: one-year results. *J Cataract Refract Surg.* 2011;37(4):691–700.
21. Caporossi A, Biaocchi S, Mazzota C, Traversi C, Caporossi T. Parasurgical therapy for keratoconus by riboflavin-ultraviolet type A rays induced cross-linking of corneal collagen: Preliminary refractive results in an Italian Study. *J Cataract Refract Surg.* 2006;32(5):837–45.
22. Henriquez MA, Izquierdo L Jr, Bernilla C, Zakrzewski PA, Mannis M. Riboflavin/Ultraviolet A corneal collagen cross-linking for the treatment of keratoconus: visual outcomes and Scheimpflug analysis. *Cornea.* 2011;30(3):281–6.
23. Wittig-Silva C, Whiting M, Lamoureux E, Lindsay RG, Sullivan LJ, Snibson GR. A randomized controlled trial of corneal collagen cross-linking in progressive keratoconus: preliminary results. *J Refract Surg.* 2008;24(7):S720–5.

How to cite this article: Srivastava G, Bhatia HK, Sridhar U. A study to evaluate safety and efficacy of corneal collagen cross-linking with riboflavin in keratoconus patients. *Ind J Clin Exp Ophthalmol.* 2018;4(3):333–338.