

CLINICO PATHOLOGICAL STUDY OF XERODERMA PIGMENTOSA WITH OCULAR INVOLVEMENT

Shreya Thatte^{1,*}, Anirudha D Gulanikar¹, Purvi Garg²

¹Professor, Department of ophthalmology, Sri Aurobindo Medical College and PG Institute Indore (MP),

¹Associate Professor Department of Dermatology MGM Medical College Aurangabad Maharashtra

²Senior Resident Department of Ophthalmology, Sri Aurobindo Medical College and PG Institute Indore (MP)

***Corresponding Author:**

E-mail: shreyathatte@gmail.com

ABSTRACT

Xeroderma Pigmentosa(XP) is an autosomal recessive disorder caused by defect in DNA repair mechanism which is induced by ultra violet rays . These patients have multisystem involvement (skin, eye, neurological and oral lesions with recurrent malignancy.

Material and Method: *It is a retrospective, observational study of 9 cases of xeroderma pigmentosa (XP) with ocular involvement. Presence of skin and ocular malignancy was the main feature. Skin malignancy diagnosed by histopathology showed squamous cell carcinoma of face, basal cell carcinoma of scalp and nose. Ocular malignancy diagnosed as squamous cell carcinoma and malignant melanoma. Cases with ocular malignancy presented with limbal nodule which was excised surgically along with application of intraoperative cyro and mitomycin C. Apart from ocular malignancy other ocular involvement was conjunctival melanosis and corneal scar. Impression cytology was done in all patients with ocular involvement.*

Observation: *XP was seen more commonly in boys with age group of 5-25 years. Incidence of malignancy was the main feature in these patients. 5 patients had skin and ocular malignancies. Skin malignancy was observed in 2 patients in form of squamous cell carcinoma and basal cell carcinoma while ocular malignancy was seen in 3 patients in the form of squamous cell carcinoma in 2 patients and malignant melanoma in 1 patient. Other ocular feature like conjunctival melanosis was present in 2 cases and corneal scar was seen in 2 patients. Follow up was done up to 6 months to note recurrence of ocular malignancy.*

Conclusion: *Early diagnosis of ocular malignancies is essential to plan treatment modality, which was done by impression cytology, accordingly mitomycin C and cryo was used to prevent recurrence.*

Keywords: *Cryo application, Hyperpigmentation of skin, Impression cytology, Ocular malignancy, Xeroderma pigmentosa*

INTRODUCTION

Xeroderma Pigmentosa(XP) is an autosomal recessive disorder, caused by defect in nucleotide excision repair (NER) mechanism is exposure to ultra violet ray is the suggested etiology.¹ It was first described by Herba and Kaposi in 1974¹. Diagnostic clinical features are photosensitivity leading to abnormal pigmentation and carcinoma of skin or eye in the form of basal cell carcinoma (BCC), squamous cell carcinoma (SCC) and melanoma². There are 8 types of xeroderma described on the basis of chromosomal defects. Classical xeroderma type A have defects in chromosomes 9q22 and 19q13¹.

Xeroderma pigmentosa can present as multisystem involvement (skin, eyes, nervous system and mouth). Skin manifestations ranged from freckles to numerous varieties of malignancies^{1,40}– 80% people have ocular abnormalities like conjunctival pigmentation, corneal infiltrates with ulceration, corneal opacities^{3,4},limbal malignancies, ectropion, symblepharon, and eyelid malignancies¹. About 20 - 30% patients have neurological involvement as loss of fine motor control, ataxia, spasticity and rigidity, loss of hearing and progressive mental retardation¹. Some patients also presents with precancerous oral lesions like leukoplakia, erythroplakia and actinic cheilitis¹.

Xeroderma pigmentosa is a rare entity and difficult to manage and often associated with high morbidity and mortality. Therefore this study was undertaken to observe the course of the disease, early detection of ocular malignancy and its effective management. This case series included 9 cases with xeroderma pigmentosa with skin and ocular surface abnormalities.

MATERIAL METHOD

Total 9 cases with XP were included in the study. 3 patients presented to Ophthalmology OPD while 4 patients were referred from Dermatology Department for evaluation and management of ocular manifestation. Age at the presentation was between 5-25 years, out of which 5 were males and 4 were females. They presented with chief complaints of hyper pigmented skin lesions on all over the body (specially exposed parts) in association of recurrent malignancy of nose, face and scalp in some patients (figure.1). On ocular examination vision ranged from 6/18 to 6/6. They presented with limbal growth, foreign body sensation, redness, photophobia and watering (figure 2). Slit lamp examination showed growth at limbus with 3mmx5mm size, melanosis, conjunctival congestion and corneal scar. Impression cytology was done in 3 cases with limbal growth and 2 patients with conjunctival melanosis (figure3).

Limbal growth was managed by surgical excision by non-touch technique, which was supported with sub conjunctival cryo beneath conjunctiva at edges with double thaw technique. Mitomycin C 0.02% was applied at the site after excision. Excised tissue was sent for histopathological study. Histopathological report showed squamous cell carcinoma in two patients and malignant melanoma in one patient. Post operatively mitomycin c drops; antibiotic steroid combination was given in tapering dose along with lubricating drops. Other patients were prescribed antibiotic and lubricating drops (Table 4). No recurrence was noted in follow up of more than 6 months.

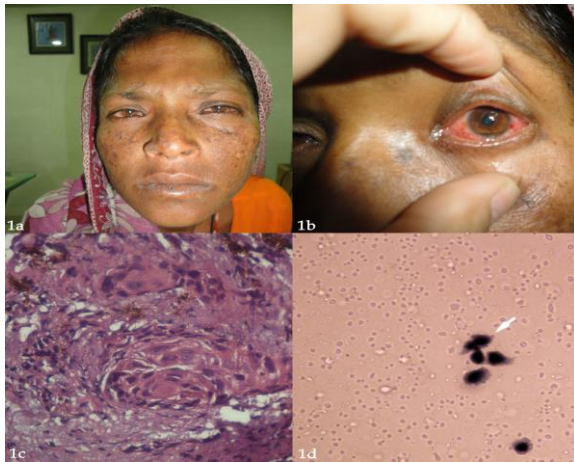


Fig.1: (a) Pin point hyperpigmentation of skin of face in 25 year old female, (b) Conjunctival congestion and raised area on temporal side in left eye, (c) Histopathology shows epidermal alteration atypia of the keratinocytes across the full thickness of the epidermis. There is loss of the granular layer and overlying zones of parakeratosis. The keratinocytes show cytologic atypia with disorderly maturation, (d) Impression cytology shows large polygonal cells with a decrease in nucleus: cytoplasm ratio. Reduced number of goblet cells, with reduced staining. This is seen in grade 3 impression cytology.

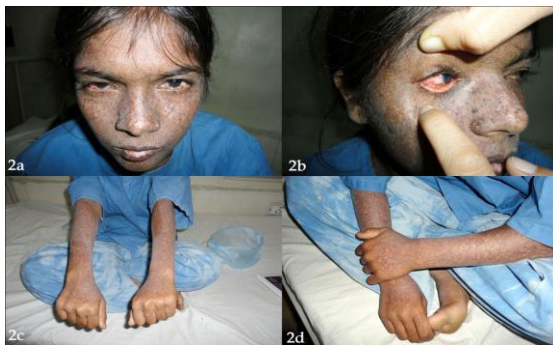

Fig. 2: (a) Pin point hyper pigmentation of skin of face in a young girl, (b) Nodular lesion in right eye with conjunctival congestion, (c) Clinically pin point lesion on exposed parts, (d) Pin point lesion on ulnar aspect of forearm.

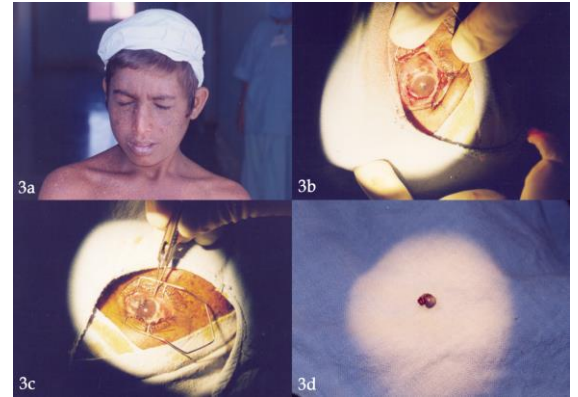


Fig. 3: (a) Pin point hyperpigmentation of skin of face in a 13 year old boy, (b) Melanoma in left eye at 9 'o' clock limbus, (3) During surgical excision, (d) Gross pathology of melanoma.

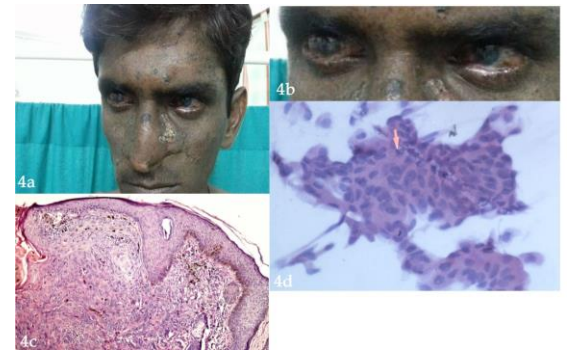


Fig. 4: (a) Pin point hyper pigmentation of skin of face with raised nodule at ala of nose, (b) Melanosis of conjunctiva in both eyes (c) Histopathology of nodule at nose tip, spreading and budding pattern of cancer cells with extensive infiltrating islands and cords of cancer cells. Along with prominent clumps of melanin pigmentation, (d) Impression cytology of conjunctiva of left eye. Good cell sheet consisting of larger polygonal epithelial cells with decreased nucleocytoplasmic ratio of 1:3. Goblet cells were reduced in number but still deeply PAS positive. This is seen in grade 2 impression cytology

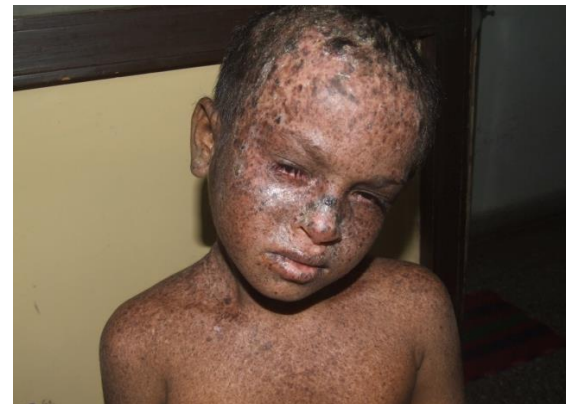

Figure 5: Pin point hyper pigmentation of skin of face and upper body with extreme photophobia

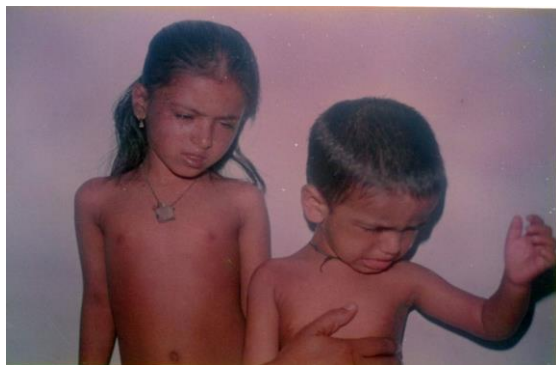

Fig. 6: Pin point hyper pigmentation of skin of face in sister and brother

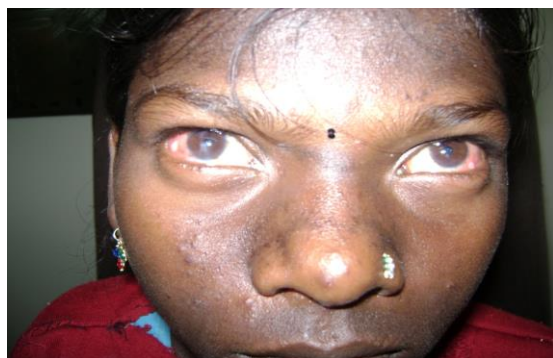

Fig.7: Pin point hyper pigmentation of skin of face with corneal scar along with congestion in both eyes

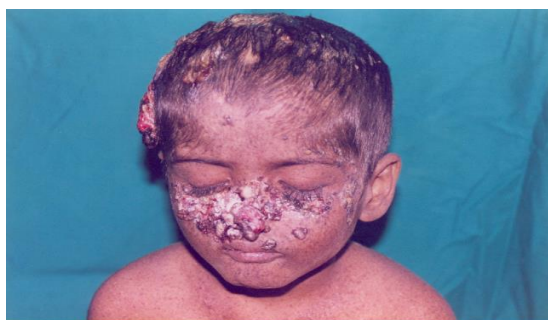

Fig. 8: Multiple nodules of face and scalp along pin point hyper pigmentation of skin of face

OBSERVATION

In our case series there were 5(54.4%) males out of 9 cases with age group between 5 years to 25 years (Table 1). All the 9 cases included had classical skin manifestation in the form hyperpigmentation of skin on exposed parts of body and ocular clinical features as redness, watering, photophobia and foreign body sensation (Table 2). Malignancy was seen in 5 cases, 3 cases had ocular malignancy and 2 had skin malignancy .In 3 cases of ocular malignancy 2 patients had squamous cell carcinoma and 1 had malignant melanoma. Skin malignancy reported was basal cell carcinoma of nose in 19 year old male and squamous cell carcinoma of face and basal cell carcinoma of scalp in 5 year old boy. 2 cases had only melanosis of conjunctiva. Inferior corneal scar was seen in 2 cases (Table 3). Impression cytology was done in 5 cases which diagnosed grade 3 changes in ocular malignancy and grade 2changes with conjunctival melanosis. All the three cases with ocular malignancy underwent with wide excision with intraoperative cryo and mitomycin C application Case were followed up every week for a month then monthly for 6 months .During follow up no recurrence was observed .

Table 1: Demographic data

Case No	Age	Sex
1	25	Female
2	14	Female
3	13	Male
4	19	Male
5	8	Male
6	8	Female
7	5	Male
8	18	Female
9	5	Male

Table 2: Skin and ocular clinical symptoms

Case No	skin	Ocular Clinical Features
1	Hyper pigmented pin point lesion	Redness, Photophobia, Watering and Limbal Growth
2	Hyper pigmented pin point lesion	Redness, Photophobia, Watering and Limbal Growth
3	Hyper pigmented pin point lesion	Redness, Photophobia, Watering and Limbal Growth
4	Hyper pigmented pin point lesion	Congestion, Redness and Watering
5	Hyper pigmented pin point lesion	Redness and Watering
6	Hyper pigmented pin point lesion	Redness and Watering
7	Hyper pigmented pin point lesion	Redness and Watering
8	Hyper pigmented pin point lesion	Redness and Watering

Table 3: Skin and ocular signs in the study

Case No	Skin Malignancy	Ocular Malignancy	Conjunctival Congestion	Conjunctival melanosis	Corneal scar
1		Squamous cell carcinoma			
2		Squamous cell carcinoma			
3		Malignant melanoma			
4	Basal cell carcinoma of nose			Present	
5				Present	
6			Present		
7			Present		
8					Present
9	Squamous cell carcinoma face , Basal cell carcinoma of scalp				Present

Table 4: Impression cytology and Management in each case

Case No	Impression Cytology	Management
1	Grade 3	Surgical excision
2	Grade 3	Surgical excision
3	Grade 3	Surgical excision
4	Grade 2	Lubricating and antibiotic drops
5	Grade 2	Lubricating and antibiotic drops
6	-	Lubricating and antibiotic drops
7	-	Lubricating and antibiotic drops
8	-	Lubricating and antibiotic drops
9	-	Lubricating and antibiotic drops

DISCUSSION

Xeroderma pigmentosa is an, autosomal recessive disease caused by defects in the normal repair of DNA leading to various cutaneous and ocular pathology¹.

This is a retrospective observational study of 9 patients, 5 male (55.5%) and 4 females (44.4%). Age ranged between 5 to 25 years, which correlates with literature that shows incidence of XP is more common in boys in age group between in 5 years – 24 years^{1, 2, 6, 7}.

Arun Kumar S. Bilodi et al reported three stages of skin disease 1.freckles, 2.poikiloderma and solar keratoses and 3.carcinomas². Mozhgan Rezaei Kanavi et al described progressively increasing nature of skin pigmentation and atrophy, followed by development of dermal tumors⁵. In our study, all patients had skin lesion in form freckles in exposed part of skin with basal cell carcinoma of nose and squamous cell carcinoma of face and basal cell carcinoma of scalp in 2 cases.

Rajesh R Nayak, Chaudhary et al reported cases of 6 and 5 year old child with growing mass of conjunctiva and histopathology report showed squamous cell carcinoma⁶. Similarly Achyut N. Pandey et al described basal cell carcinoma of both lids and conjunctiva in a 6 year old boy⁷. Sankha

Koley et al reported a case with squamous cell carcinoma of right eye involving right cheek in a 24 year old male¹.

A J Vivian et al described hyperpigmentation of limbal conjunctiva in 20 and 22 years old female with histopathological report of malignant melanoma⁴.In our case series 3 out of 9 patients presented with nodule at limbus .Histopathological report in 2 patients was squamous cell carcinoma and one patient was malignant melanoma.

Hyper pigmented patches on conjunctiva as stated by Arun Kumar S. Bilodi et al ². In our study 5 patients presented with hyper pigmented conjunctiva out of which two patients had limbal squamous cell carcinoma.

Another significant finding was bilateral inferotemporal corneal scar in our study in a 18 year old female and 5 years old male .In both cases corneal scar was not involving visual axis ,so patients were prescribed local lubricating drops . Mozhgan Rezaei Kanavi et al had a case of 19-year-old man with bilateral corneal leukoma which was treated with penetrating keratoplasty, histopathologic evaluation showed interstitial lipogranulomatous keratitis⁵.

Jefery Freedman et al reported cases with band shaped keratopathy in 13, 30 year old brothers. All of them underwent keratoplasty³.

In literature there are very few studies reporting, importance of early diagnosis and management in cases of xeroderma pigmentosa. In our study impression cytology helped us in early diagnosis of ocular malignancies and to take decision of management accordingly with intraoperative cyro and mitomycin C application and post operative mitomycin C drops. This strategy helped us to prevent recurrence.

CONCLUSION

XP patients have shorter life span due to recurrent malignancy. To prevent spread of malignancy it is important to diagnose them early and manage in a proper way. They require regular follow ups to note any recurrence. In our series early diagnosis was made by impression cytology and during surgical excision mitomycin C and cryo application was done to prevent recurrence.

REFERENCES

1. Sankha Koley, Sanjiv V. Choudhary, Soumen Choudhury, Shilpi Sharma, Tanmoy Mukherjee, Kalyan Khan (2012). Xeroderma pigmentosum: report of two cases and review of the literature. *Journal of Pakistan Association of Dermatologists* 2012;22(3):279-282.
2. Arun Kumar S. Bilodi and M. R. Gangadhar (2013). Xeroderma Pigmentosa-a rare clinical entity. *Indian Journal of Medical Case Reports* 2013 2 (1) January-March, pp.21-24.
3. JEFFREY FREEDMAN (1977). Xeroderma pigmentosum and band-shaped nodular corneal dystrophy. *British Journal of Ophthalmology*, 1977, 61, 96-100.
4. A J Vivian, D W Ellison, J I McGill (1993). Ocular melanomas in xeroderma pigmentosum. *British Journal of Ophthalmology* 1993; 77: 597-598.
5. Mozghan Rezaei Kanavi, Mohammad-Ali Javadi, Hamid-Reza Zabihi Yeganeh (2008). Corneal Involvement in Xeroderma Pigmentosum; a Histopathologic Report. *J Ophthalmic Vis Res* 2008; 3 (1): 66-69.
6. Rajesh R Nayak, Gurudutt M Kamath, Manjunath M Kamath, Ajay R Kamath, Susan D'Souza, Roopashree (2013). Ocular Surface Squamous Neoplasia in Xeroderma Pigmentosum. *Online Journal of Health and Allied Sciences* Volume 12, Issue 3; Jul-Sep 2013.
7. Achyut N. Pandey, Krishna Kuldeep, Ameeta Koul, Manoj Tyagi, Parul Singh, Parmeshwari Das Sharma, Deepak Dimri (2013) Xeroderma pigmentosa with ocular association: Case report. *Case Reports in Clinical Medicine* 2013 2 (8); 466-469 (2013).