

CUBE AVERAGE THICKNESS PROVIDES A GLOBAL PERSPECTIVE OF DIABETIC MACULAR EDEMA

Sandeep Saxena^{1,*}, Khushboo Srivastav², Surabhi Ruia³,
Vinod Kumar BM⁴, Nibha Mishra⁵

^{1,2,3,4,5}Retina Service, Department of Ophthalmology
King George's Medical University, Lucknow, India.

***Corresponding Author:**

E-mail: sandeepsaxena2020@yahoo.com

ABSTRACT

Objective: To provide a descriptive analysis of spectral domain optical coherence tomography (SD-OCT) based morphologic patterns of diabetic macular edema (DME) and to study the association of alteration in macular thickness parameters with severity of diabetic retinopathy.

Method: Twenty consecutive cases each of diabetes mellitus without retinopathy, non-proliferative diabetic retinopathy, proliferative diabetic retinopathy (based on ETDRS classification) and 20 healthy controls were recruited. Best corrected visual acuity (BCVA) was assessed using logMAR scale. All the study subjects were subjected to SD-OCT imaging using macular cube 512x128 protocol. Central subfield thickness (CST) (μm) and cube average thickness (CAT) (μm) were documented. Cases with CAT more than 250 μm were sub classified based on morphology. Statistical analysis was done.

Results: Significant increase in CST and CAT and decrease in BCVA was found between the study groups ($p < 0.001$, $p < 0.001$, $p < 0.0001$, respectively). Significant negative correlation of BCVA was found with CST ($r=0.4$, $p < 0.05$) and CAT ($r=0.2$, $p < 0.001$). Forty cases with CAT above 250 μm were further classified: diffuse retinal thickening ($n=60\%$, 24/40); cystoid macular edema ($n=25\%$, 10/40); serous retinal detachment ($n=15\%$, 6/40).

Conclusion: Significant increase in CST and CAT on SD-OCT is associated with increase in severity of diabetic retinopathy and decrease in BCVA. Cube average thickness provides a global perspective of defining DME within the macular cube.

Keywords: diabetic retinopathy; spectral domain optical coherence tomography; central subfield thickness; cube average thickness; macular edema, serous retinal detachment.

INTRODUCTION

Diabetes mellitus is a disease of considerable morbidity and mortality. It is estimated that 382 million people had diabetes mellitus in 2013. This number is expected to rise to 592 million by 2035.¹

Diabetic macular edema (DME) is the major cause of vision loss associated with diabetic retinopathy. Correlation of macular thickness parameters on spectral domain optical coherence tomography (SD-OCT) i.e mean macular thickness, retinal thickness, foveal thickness and central macular thickness have been shown to correlate with severity of diabetic retinopathy and visual acuity.²⁻⁷

Diabetic retinopathy results in microangiopathy due to prolonged hyperglycemia.⁸⁻¹⁰ A number of interconnecting biochemical pathways have

been proposed to explain the cause-effect relationship. Our earlier studies have demonstrated that serum levels of vascular endothelial growth factor, intracellular cell adhesion molecule-1 and N-Carboxy methyl lysine increase significantly with severity of diabetic retinopathy.^{11, 12.}

Spectral Domain Optical Coherence Tomography has been recognized as a reliable investigative tool for quantifying and classifying macular edema with excellent reproducibility.¹³⁻¹⁶ In our previous studies, we have studied the association of several SD-OCT based parameters like macular thickness, inner segment ellipsoid band and external limiting membrane disruption with the severity of diabetic retinopathy.^{17, 18}

Based on a systematic review analysis for detection of clinically significant macular edema (CSME) on SD-

OCT, median central retinal thickness reference limit was taken as 250 μm .¹⁹ In the present study, we provide a descriptive analysis of SD-OCT based morphologic patterns of DME and study the association of alteration in macular thickness parameters with severity of diabetic retinopathy.

MATERIALS AND METHOD

Our study had institutional review board clearance and was performed in accordance to the tenets of the Helsinki declaration. In this tertiary care center based prospective cross sectional study, 20 consecutive cases each of diabetes mellitus without retinopathy (No DR), non-proliferative diabetic retinopathy (NPDR), proliferative diabetic retinopathy (PDR) (based on ETDRS classification)²⁰ and 20 healthy controls were recruited. Cases with systemic or ocular diseases affecting retinal vascular pathology, any previous ophthalmic surgical or laser interventions, signal strength 5 or below on OCT examination were excluded from the study. The best-corrected visual acuity (BCVA) was recorded on logMAR scale. Information regarding subject's age, gender, disease duration, status of retinopathy was recorded. Slit lamp biomicroscopic and dilated ophthalmoscopic examination were performed. Subsequently, all the study subjects underwent macular thickness analysis using SD-OCT [Cirrus High Definition OCT (Carl Zeiss Meditec Inc., Dublin, CA, U.S.A)]. Macular cube 512x128 feature was used and central subfield thickness (CST) (μm) and cube average thickness (CAT) (μm) were documented. CST was defined as thickness of the central circle in the circular map known as the ETDRS Grid. CAT was defined as an overall average thickness for the internal limiting membrane-retinal pigment epithelium tissue layer over the entire 6 x 6 mm square scanned area. DME was defined as cases with CAT above the reference limit of 250 μm .¹⁹ The ETDRS definition of CSME includes: central and noncentral types. Central diabetic macular edema (CDME)

accounts for retinal thickening within 500 μm of the center of the macula or, hard exudates within 500 μm from the center of the macula with thickening of the adjacent retina. The noncentral type of CSME is defined as a zone of retinal thickening, 1 disc area or larger, any portion of which is located within 1 disc diameter from the center of the macula.²¹

Data is presented as mean \pm standard error. The continuous variables (age, CST, CAT and BCVA on logMAR scale) of the study groups were compared by one factor analysis of variance (ANOVA). Chi-square (χ^2) test was used to compare the discrete variable. Pearson correlation analysis was used to assess association between the study variables. $P < 0.05$ was considered statistically significant. All analyses were performed on STATISTICA (window version 6.0) software.

RESULTS

Out of eighty study subjects, 50 were males and 30 females. The mean age in years was 49.45 ± 10.61 , 55.35 ± 7.65 , 52.45 ± 6.73 and 50.15 ± 9.15 in healthy controls, No DR, NPDR and PDR groups respectively. No statistical difference was found among the age ($F=1.9$, $p > 0.05$) and sex of the study groups ($\chi^2=2.8$, $p > 0.05$). Mean duration (years) of diabetes mellitus in each group was Control: 0.0 ± 0.0 ; NODR: 6.15 ± 4.87 ; NPDR: 10.43 ± 6.14 ; PDR: 10.25 ± 5.17 . On comparing the duration of diabetes, ANOVA revealed significant difference among the study groups ($F=21.846$, $p < 0.0001$). Summary of BCVA (logMAR), CST and CAT in the study groups has been shown in Table 1. Significant increase in CST and CAT and decrease in BCVA was found between the study groups ($p < 0.001$, $p < 0.001$, $p < 0.0001$, respectively). Pearson correlation analysis revealed a negative correlation of BCVA with CST ($r=0.4$, $p < 0.05$) and CAT ($r=0.2$, $p < 0.001$). CAT was found to be more sensitive predictor of BCVA.

Table 1: Summary of visual acuity (logMAR), central subfield thickness, cube average thickness in the study groups.

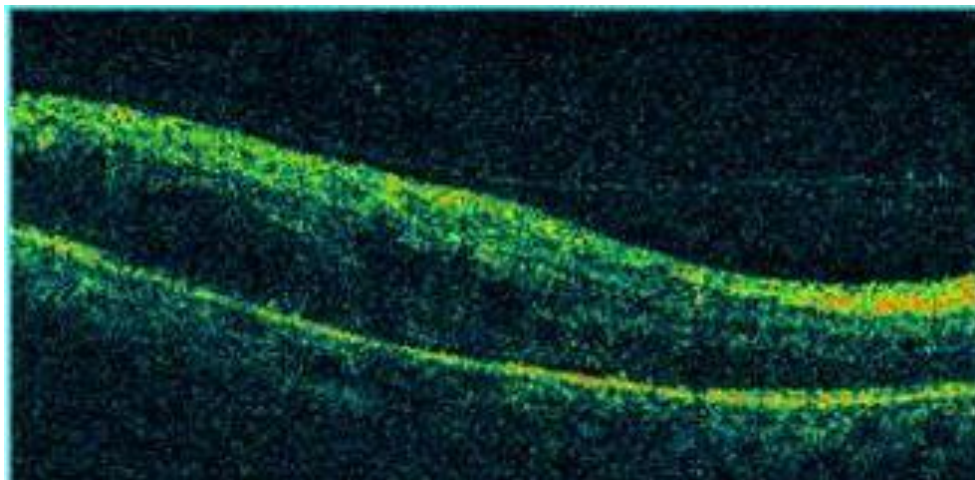
Variable (Mean ± SE)	Group				
	Controls	No DR	NPDR	PDR	p value
logMAR visual acuity	0.15 ± 0.22	0.33 ± 0.18	0.52 ± 0.39	1.12 ± 0.61	p<0.0001
Mean of central subfield thickness (µm)	241.65 ± 35.96	248.25 ± 50.05	265.70 ± 65.78	374.60 ± 150.22	p<0.001
Mean of cube average thickness (µm)	245.35 ± 12.63	266.20 ± 42.75	275.15 ± 74.64	315.60 ± 58.2	P<0.001

Table 2 summarizes macular edema in study subjects assessed by CAT more than the reference limit of 250 µm. Maximum number of cases with macular edema was found in PDR group followed by

NPDR and No DR. Forty cases with CAT above 250 µm were further classified as: diffuse retinal thickening (n=60%, 24/40); cystoid macular edema (n=25%, 10/40); serous retinal detachment (n=15%, 6/40).

Table 2: Summary of morphological patterns of macular edema in study subjects assessed by cube average thickness above 250 µm.

Group	Below cut-off value	Above cut-off value
Control	20	0
No DR	10	10
NPDR	8	12
PDR	2	18

**Figure 1: Diffuse macular thickening on spectral domain optical coherence tomography.**

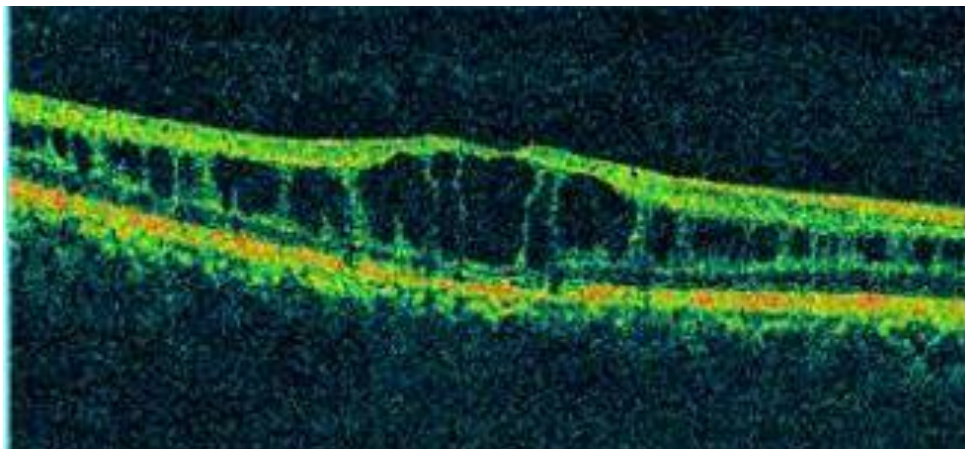


Figure 2: Cystoid macular edema on spectral domain optical coherence tomography.

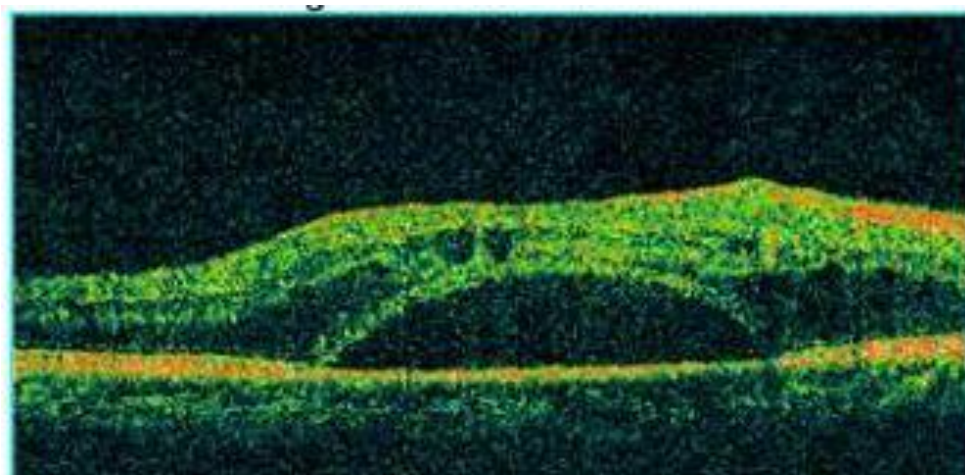


Figure 3: Serous detachment on spectral domain optical coherence tomography.

DISCUSSION

In the present study, we provide a descriptive analysis of SD-OCT based morphologic patterns of DME and study the association of alteration in macular thickness parameters with severity of diabetic retinopathy. Significant association of increase in CST and CAT was observed with the increase in severity of retinopathy and decrease in BCVA. The findings of the present study are in accordance with several other studies.²⁻⁷

Menchini et al, in a systematic review analysis for detection of macular edema on SD-OCT in patients with diabetic retinopathy, observed the median central retinal thickness reference limit for data extraction as 250 μm .¹⁹ This criteria was also used by the DRCR.net.²² Central

retinal thickness does not result in a poor performance due to inability to detect the noncentral CSME. This has been demonstrated by studies which found a strong correlation between extrafoveal and foveal thickness measurements, suggesting similar reference limits.^{23, 24} Sadda et al.²⁵ used the Macular Grid 5 scanning protocol and a complex diagnostic algorithm that accounted for a separate recognition of CDME. Our novel approach of taking a 250 micron reference limit of cube average thickness provides a global perspective of diabetic macular edema. In our present study, 40 patients have CAT more than the reference limit.

Among the many classifications of DME based on OCT, Kim et al classified macular edema into diffuse retinal thickening, cystoids macular edema, serous retinal detachment.²⁶ Forty cases with CAT

above 250 μm were further classified: diffuse retinal thickening (n=60%, 24/40); cystoid macular edema (n=25%, 10/40); serous retinal detachment (n=15%, 6/40).

CONCLUSION

Current study presents a novel approach of defining diabetic macular edema by cube average thickness which provides a global perspective. It also demonstrates a significant association between SD-OCT based macular thickness

parameters with severity of diabetic retinopathy.

ACKNOWLEDGEMENT: none

ETHICAL STATEMENT: Our study had institutional review board clearance and was performed in accordance to the tenets of the Helsinki declaration.

FINANCIAL SUPPORT: None

CONFLICT OF INTEREST: No conflicting relationship exists for authors

REFERENCES:

1. Guariguata L, Whiting DR, Hambleton I, Beagley J, Linnenkamp U, Shaw JE. Global estimates of diabetes prevalence for 2013 and projections for 2035. *Diabetes research and clinical practice* 2014; 103: 137-149.
2. Hee M, Carmen A, Jay S. Topography of diabetic macular edema with OCT. *Ophthalmol* 1998; 105: 360-70.
3. Oshima Y, Emi K, Yamanishi S, Motokura M. Quantitative assessment of macular thickness in normal subjects and patients with diabetic retinopathy by scanning retinal thickness analyser. *British journal of ophthalmology* 1999; 83: 54-61.
4. Goebel W, Kretzchmar-Gross T. Retinal thickness in diabetic retinopathy: a study using optical coherence tomography (OCT). *Retina* 2002; 22: 759-767.
5. Sanchez-Tocino H, Alvarez-Vidal A, Maldonado MJ, Moreno-Montanes J, Garcia-Layana A. Retinal thickness study with optical coherence tomography in patients with diabetes. *Invest Ophthalmol Vis Sci* 2002; 43:1588-94.
6. Alkuraya H, Kangave D, El-Asrar AMA. The correlation between optical coherence tomographic features and severity of retinopathy, macular thickness and visual acuity in diabetic macular edema. *International ophthalmology* 2005; 26: 93-99.
7. Browning D, Glassman A, Aiello L. Relationship between optical coherence tomography-measured central retinal thickness and visual acuity in diabetic macular edema. *Ophthalmology* 2007; 114:525-36.
8. Rema M, Pradeep R. Diabetic retinopathy: an Indian perspective. *Ind J Med Res* 2007, 125: 297-310.
9. Furtado JM, Lansingh VC, Carter MJ, Milanese MF, Pena BN, Ghersi HA. Causes of blindness and visual impairment in Latin America. *Surv Ophthalmol* 2012,57(2):149-77.
10. Tyagi M, Narayanan R. Diabetic retinopathy and cardiovascular disease. *Ophthalmology*, 2011; 118: 2529-30.
11. Jain A, Saxena S, Khanna VK, Shukla RK, Meyer CH. Status of serum VEGF and ICAM-1 and its association with external limiting membrane and inner segment-outer segment junction disruption in type 2 diabetes mellitus. *Molecular Vision* 2013.19; 1760-68.
12. Saxena S, Mishra N, Khanna V, Jain A, Shukla R, et al. Increased Serum N-CML, VEGF and ICAM-1 is Associated with Photoreceptor Inner Segment Ellipsoid Disruption in Diabetic Retinopathy. *JSM Biotechnol Bioeng* 2014; 2(2): 1039.
13. Diabetic Retinopathy study. Report number 7. A modification of the Airline House Classification of diabetic retinopathy. *Invest Ophthalmol Vis Sci* 1981; 21: 210-26.
14. Otani T, Kishi S. Patterns of diabetic macular edema with OCT. *Am J Ophthalmol* 1999; 27: 674-88.
15. Gupta V, Gupta A, Dogra M. Introduction to OCT, Atlas- OCT of macular diseases and glaucoma 2010; 3-46.
16. Goebel W, Kretzchmar-Gross T. Retinal thickness in diabetic retinopathy: a study using optical coherence tomography (OCT). *Retina* 2002; 22: 759-67.
17. Sharma SR, Saxena S, Mishra N, Akduman L, Meyer CH. The Association of Grades of Photoreceptor Inner Segment-Ellipsoid Band Disruption with Severity of Retinopathy in Type 2 Diabetes Mellitus. *Journal of Case Reports and Studies* 2014.
18. Saxena S, Srivastav K, Akduman L. Spectral domain optical coherence tomography based alterations in macular thickness and inner segment ellipsoid are associated with severity of diabetic retinopathy. *Int J Ophthalmol Clin Res* 2015; 2007.
19. Virgili G, Menchini F, Murro V, Peluso E, Rosa F, Casazza G. Optical coherence tomography (OCT) for detection of macular oedema in patients with diabetic retinopathy. *Cochrane Database Syst Rev* 2011. 6; (7):CD008081.

20. ETDRS Research Group: Grading Diabetic Retinopathy from Stereoscopic Color Fundus photograph: ETDRS report number 10. *Ophthalmology* 1984; 91: 1464-1474.
21. Early Treatment Diabetic Retinopathy Study Research Group. Photocoagulation treatment for Diabetic Macular Edema. ETDRS ReportNumber 1. *Arch Ophthalmology* 1985; 103: 1796–1806.
22. Diabetic Retinopathy Clinical Research Network Web site. <http://public.drcre.net/> Accessed on February 20, 2007.
23. Hee MR, Puliafito CA, Wong C, et al. Quantitative assessment of macular edema with optical coherence tomography. *Arch Ophthalmol* 1995; 113: 1019–1029.
24. Goebel W, Kretzchmar-Gross T. Retinal thickness in diabetic retinopathy: a study using optical coherence tomography (OCT). *Retina* 2002; 22: 759–767.