

Posteriorly dislocated /subluxated cataractous lens: A surgical dilemma and management

Shashidhar S¹, Apoorva Mithrananda^{2,*}, Rita Mary Tomy³

¹Associate Professor, ^{2,3}PG Student, Mind Ophthalmic Hospital, Bangalore Medical College & Research Institute, Bangalore

***Corresponding Author:**

Email: apurvmitra@gmail.com

Abstract

Aim: To assess and compare the visual outcome of the different approaches in the management of dislocated/subluxated cataractous lens.

Methods: This is a retrospective study of 32 eyes of 32 patients who were managed for dislocation/subluxation of cataractous lenses from 2012 to 2015.

All patients underwent 3PPPV/ anterior vitrectomy with PFCL assisted extraction of the dislocated cataractous lens. 2 point ab-externo scleral fixated IOLs were implanted in 15 patients, ACIOL implantation was done in 2 patients and the remaining 15 patients who underwent Vitrectomy and lens removal were left aphakic due to various reasons (a)lost to follow up (b)fellow eye aphakic(c)had preoperative complications like Vitreous haemorrhage, Retinal break etc. The visual outcome of these various procedures were compared and analysed.

Results: Our study included 32 eyes of 32 patients with a median follow up period ranging from 3-36 months. SFIOLs were implanted in 15 patients, ACIOL implantation was done in 2 patients and 15 patients were left aphakic. Post-operative best corrected visual acuity of 6/18 or better was achieved in 73.33% of patients treated with SFIOL implantation. BCVA of 6/18 or better was achieved in 40% of patients who were left aphakic and given aphakic spectacle correction. The remaining 60% had a visual acuity of <6/36. Post-operative BCVA was ranging between 6/60-6/18 in patients with ACIOL implantation. Intraoperative complications were seen maximum in patients who were left aphakic, with 60% patients(9/15) having retinal breaks/RD. In the SFIOL group 6 eyes(40%) had early post-op complications as compared to 14 eyes (93.33%) in the aphakic group and 1 eye(50%) in the ACIOL group. Late post-op complications were noted similarly in both SFIOL and aphakic groups with 4 eyes(26.67%) affected in each group. One out of two patients(50%) in ACIOL group developed persistent uveitis as a late complication.

Conclusion: The post-operative visual outcome was good following both SFIOL and ACIOL implantation. However SFIOL implantation seems to have a lower post-op complication rate than ACIOL implantation. Patients who were left aphakic had numerous intra-operative and post-operative complications with dismal outcome. Hence, SFIOL implantation can be proposed as a novel approach towards the management of dislocated cataractous lenses.

Keywords: BCVA: Best Corrected Visual Acuity, Dislocated Cataractous Lens, PFCL: PER Fluoro Carbon Liquid, 3 PPPV: 3 Port Pars Plana Vitrectomy, SFIOL: Scleral Fixated Intra-Ocular Lens,

Access this article online

Website:

www.innovativepublication.com

DOI:

10.5958/2395-1451.2016.00045.7

Introduction

Dislocation of lens encompasses any displacement or malposition of the crystalline lens irrespective of the cause or association. Lens dislocations can be classified as congenital or acquired. Congenital dislocations can occur in Homocystinuria, Marfan's syndrome and Weil-Marchesani syndromes. Acquired crystalline lens dislocations can be the result of trauma, surgical complications and other ocular pathologies. Postsurgical luxations are due to rupture of the posterior capsule.¹

Spontaneous lens subluxation can occur due to rupture of the zonular fibers as a consequence of degeneration and inflammation in long-standing

glaucoma, high myopia, uveitis, retinal detachment, and pseudoexfoliation syndrome. Retinitis pigmentosa can result in a similar progressive zonulopathy.⁷ Posterior dislocation of lens fragments can result in complications such as chronic uveitis, elevated IOP, CME, corneal edema, retinal detachment, retinal depigmentation by dislocated lens, and induced mechanical and chemical reactions.¹

Thus, the surgical objective is to remove the lens without any collateral damage to the other intraocular structures, especially the retina and the cornea. There are several options for secondary IOL implantation: sulcus-fixated IOLs, iris-fixated IOLs, anterior chamber IOLs (AC IOL) and transscleral suture-fixated IOLs.¹ The decision for the management should be individualized based on the risks and benefits to the patient and surgeon preference. There is no single study outlining the visual outcome of these various procedures. Hence the need for this comparative study on management of aphakia with SFIOL implantation, ACIOL implantation and the consequences of leaving

the patient aphakic so as to help the surgeon with appropriate decision making.

Materials and Methodology

This is a retrospective study of consecutive patients treated from 2012-2015. A total of 32 eyes of 32 patients were included in the study all of whom underwent 3Port Pars Plana Vitrectomy/Anterior Vitrectomy with removal of lens. Of these, 15 patients underwent SFIOL implantation, 2 patients underwent ACIOL implantation and the remaining 15 patients who underwent Vitrectomy and lens removal were planned for a second procedure to manage the aphakia but were left aphakic due to various reasons (a)lost to follow up (b)fellow eye aphakic (c)had preoperative complications like Vitreous haemorrhage, Retinal break etc. All patients were followed up for a minimum period of 3 months.

Inclusion Criteria

1. Traumatic subluxation/dislocation of crystalline /cataractous lens.
2. Congenital conditions with subluxated/dislocated crystalline/cataractous lens.

Exclusion Criteria

Corneal opacity, chronic uveitis, optic nerve pathology and macular pathology interfering with final visual outcome.

Patient Evaluation

Patient demographics, pre-operative and post-operative Snellen's best corrected visual acuity (BCVA), nature and complications of surgery and post-operative complications were noted. The BCVA was converted into logarithm of minimum angle of resolution(log MAR) units for statistical analysis. Visual acuity of hand movements and light perception is assigned equivalent of 1.7and 1.8 logMAR units, respectively

Procedure

- 15 cases underwent anterior vitrectomy/3 port pars plana vitrectomy + removal of lens using PFCL and abexterno 2 point scleral fixation.
- 2 cases underwent anterior vitrectomy with lensectomy + ACIOL implantation.
- 15 cases underwent anterior vitrectomy/ 3PPV +lens removal +/- Cryotherapy/ Endolaser.

In 31 cases with posteriorly dislocated/subluxated lens, vitrectomy was done and the lens was removed using PFCL. In one patient with anteriorly dislocated cataractous lens, the lens was removed via sandwich technique through the SICS tunnel incision.

Post-operative Evaluation

Patients were evaluated on first post-operative day then subsequently at 1 week, 1 month and 3 months

post-surgery. At each subsequent visit all patients were submitted to detailed evaluation including visual acuity, anterior and posterior segment examination and refraction.

Results

Majority of the patients (84%) were above 40 years of age with male pre-ponderance(75%)(Table 1). The etiology of aphakia was predominantly traumatic (84%, n=27), while surgical cause formed 6%(n=2). Others(3 patients) included a patient with Marfans syndrome and 2 other non-traumatic spontaneous dislocation of lens. (Table 2).

In 10 patients(31%) the lens was subluxated, of which 1 patient had anteriorly subluxated cataractous lens. In the rest of the patients, the lens was posteriorly dislocated. (Table 3).

The pre-operative BCVA for subluxated and dislocated lenses was <2/60 (logMAR 1.778-1.47) (Table 4).

15 patients (47%) underwent SFIOL implantation, 2 patients underwent ACIOL implantation and 15 patients(47%)who were lost to follow up were left aphakic. (Table 5).

The post-operative BCVA varied depending on the surgical management. At the end of 3 months, 11 out of the 15 patients of the SFIOL group had a BCVA of 6/24-6/9 (logMAR 0.602-0.176). (Table 6) Out of remaining 4 patients, 2 had BCVA of 6/60-6/36. 1 patient with SFIOL implantation, whose lens was dislocated into anterior chamber, progressed to secondary glaucoma. The other patient developed retinal detachment in post-operative phase.

The 2 ACIOL implantation cases had good visual outcome with BCVA of 6/36-6/24(logMAR 0.778-0.602).

Post –operative BCVA was worst in those left aphakic with 40% having BCVA of < 1/60. 53.33% had BCVA of 6/60-6/18 with spectacle correction. (Table 5).

All patients treated with SFIOL and ACIOL procedures had a minimum of 3 lines improvement in final visual acuity recorded on Snellens chart compared to pre-operative BCVA, except 2 SFIOL case which had post-operative secondary glaucoma and retinal detachment respectively.

The various complications encountered were grouped as intraoperative, early post-operative and late complications. (Table 7, 8, 9).

2 patients with SFIOL had hyphaema due to passage of needles. Hypotony was noted in 1 case with SFIOL implantation which was managed with intracameral viscoelastic agent per-operatively. Retinal breaks were noted in 3 patients with SFIOL implantation and 9 patients who were left aphakic. Of the 3 cases with SFIOL implantation, 2 cases were managed with endolaser. In the third case, 240BB was

applied. All SFIOL cases had good post-operative visual outcome.

Of the patients who were left aphakic, one patient SF6 tamponade was done with good post-operative visual outcome. Another patient was treated with silicon oil injection and cryotherapy, who progressed to secondary glaucoma and optic atrophy. The other 7 patients were managed with cryotherapy +/- endolaser, with good post-operative visual outcome. The late post-operative complications were observed in 2 patients of SFIOL group with 1 progressing to secondary glaucoma and 1 progressing to retinal detachment.

In the aphakic group, 2 went on to develop secondary glaucoma and 1 patient developed retinal detachment.

Table 1: Patient demographics

Age group	Males	Females	Total	Percentage
<10 years	0	0	0	0%
11-20 years	2	0	2	6%
21-30 years	1	0	1	3%
31-40 years	1	1	2	6%
41-50 years	6	3	9	28%
51-60 years	6	2	8	25%
>60 years	8	2	10	31%
	24	8	32	100%

Table 2: Etiology of aphakia

Aetiology	No of eyes	Percentage
Traumatic	27	84%
Surgical	2	6%
Others	3	9%

Table 3: Indications for surgery

	No of eyes	Percentage
Subluxated	10	31%
Dislocated	22	69%

Table 4

Pre-Op Visual Acuity	logMAR	SFIOL	ACIOL	APHAKIA
<1/60	>1.778	5	1	11
1/60-2/60	1.778-1.477	10	1	3
3/60-4/60	1.301-1.176	0	0	1
5/60-6/60	1.079-1	0	0	0
6/36-6/24	0.778-0.602	0	0	0

Table 5

Procedure	No of eyes	Percentage
SFIOL	15	47%
ACIOL	2	6%
APHAKIA	15	47%

Table 6

Pre-Op Visual Acuity	logMAR	SFIOL	ACIOL	Aphakia with Correction
<6/60	>1	2		6
6/60-6/36	1-.778	2	1	3
6/24-6/18	0.602-0.477	6	1	5
6/12-6/9	0.301-0.176	5		1
6/6.	0			

Table 7

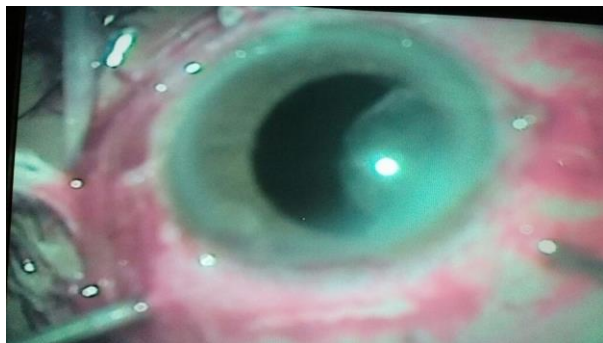
intra-op complications	SFIOL	ACIOL	APHAKIA
Hyphaema	2	0	
Hypotony	1	0	
Retinal break	3		9
Total	6	0	9

Table 8

Early post-op complications	SFIOL	ACIOL	APHAKIA
Fibrin	2	1	5
Corneal oedema	2	0	2
Hyphaema	1	0	3
Vitreous haemorrhage	0	0	1
Choroidal detachment	0	0	1
Macular oedema	0	0	1
Hypotony	1	0	1
Total	6	1	14

Table 9

Late post-op complications	SFIOL	ACIOL	APHAKIA
Secondary glaucoma	2	0	2
Pupil deformation	0	0	
Persistent uveitis	1	1	
CME	0	0	1
IOL decentration	0	0	
Retinal detachment	1	0	1
Endophthalmitis	0	0	
Total	4	1	4



Subluxated cataractous lens



Dislocated cataractous lens



Discussion

Patients with retained lens material can develop pain, corneal edema, exaggerated or prolonged intraocular inflammation, secondary glaucoma, CME and retinal detachment. Thus, the management of retained intraocular lens fragments plays a great role in determining the final visual acuity.^{3,4} The surgical objective is to remove the lens without any collateral damage to the other intraocular structures, especially the retina and the cornea, and any thermal injury to the sclera.⁶

In the past, dislocated lens complications were managed by markedly dilating the pupil and then attempting to move the lens into the anterior chamber using the prone position, air, or an ophthalmic viscosurgical device and then removing the lens through a large incision in the anterior segment. However, that procedure carries a risk for vitreoretinal traction and retinal break formation.² The scenario has

changed with improvements in vitrectomy devices and use of Perfluorocarbon liquid (PFCL) which is a colorless and odorless fluid of high density and low viscosity. These characteristics allow PFCL aspiration and injection in 23-gauge vitrectomy, and the lens floats off the retina into the anterior vitreous to the iris plane and then removed by standard sics scleral tunnel incision providing excellent outcomes.

In the absence of capsule support, the problem of optical aphakia can be surgically managed by implanting an anterior chamber intraocular lens (IOL), attaching the IOL to the iris, or fixing the IOL into the posterior chamber by a transscleral suture. Scleral fixated IOL (SFIOL) is a safe and effective option for the visual rehabilitation of an aphakic eye with inadequate posterior capsule support.⁵ Recently, the Gabor et al. technique⁸, the glued IOL technique¹¹, and sutureless intrascleral PC IOL fixation¹² have been introduced.

Anterior chamber intraocular lenses can also safely be used in eyes with retained lens material. Kwong et al.¹⁴ report satisfactory results using primary implantation of open-loop AC IOLs compared with primary scleral suture-fixated IOLs. There are also reports of endothelial cell loss and glaucoma after AC IOL implantation.¹⁵ If a lens cannot be safely inserted, the patient may be left aphakic.³ A recent study found that there was no significant difference in final visual acuity, retinal detachment rate or increased IOP in patients who were pseudophakic compared to aphakic at the time of retained lens material removal, while another study suggested that placement of a posterior chamber IOL at the time of cataract surgery was associated with a better visual outcome.^{9,10}

Therefore a patient with posteriorly dislocated/subluxated cataractous lens poses a surgical dilemma to the treating surgeon who has to analyze the various approaches and choose the best possible management for this particular patient. Our study is a retrospective review of 32 eyes of 32 patients who underwent scleral fixated intraocular lens implantation, ACIOL implantation and those left aphakic and comparing and analyzing the management approach and complications associated with each procedure.

The pre-operative BCVA for subluxated and dislocated lenses was <2/60 (logMAR 1.778-1.47). In 31 cases, 3PPPV/ anterior vitrectomy was done and the lens was removed using PFCL. 15 patients (47%) underwent SFIOL implantation (14 as primary procedure and 1 as secondary procedure), 2 patients underwent ACIOL implantation and 15 patients (47%) who were lost to follow up were left aphakic.

The post-operative BCVA varied depending on the surgical management. At the end of 3 months, 11 out of the 15 patients of the SFIOL group had a BCVA of 6/24-6/9 (logMAR 0.602-0.176). Out of remaining 4 patients 2 had BCVA of 6/60-6/36. 1 patient with SFIOL implantation, whose lens was dislocated into

anterior chamber progressed to secondary glaucoma. The other patient developed retinal detachment in post-operative phase.

The 2 ACIOL implantation cases had good visual outcome with BCVA of 6/36-6/24(logMAR 0.778-0.602).

Post-operative BCVA was worst in those left aphakic with 40% having BCVA of < 1/60. 53.33% had BCVA of 6/60-6/18 with spectacle correction.

The various complications encountered were grouped as intraoperative, early post-operative and late complications.

The intraoperative complications were seen in 5 patients with SFIOL, 9 patients left aphakic.

2 patients with SFIOL had hyphaema due to passage of needles. The cause of the bleeding is due to damage to long posterior ciliary arteries, iris circle artery and hyper vascular tissue of ciliary body.

Hypotony was noted in 1 case with SFIOL implantation which was managed with intracameral viscoelastic agent per-operative post-operatively, air was injected into anterior chamber after washing the viscoelastic with IOP fairly maintained.

Retinal breaks were noted in 3 patients with SFIOL implantation and 9 patients who were left aphakic.(20% to 60%) In one large series reported by Moore et al, the incidence of rhegmatogenous retinal detachment after vitrectomy for retained lens fragments was 4.0% to 10.3%. Nearly half the detachments occurred later than 3 months postoperatively and 50% were macula-off detachments.¹³ The increased rate of retinal breaks maybe attributed to the etiology of mechanism of dislocation in our study which is mainly traumatic(84.38%).

In our study, of the 3 cases in the SFIOL group, 2 cases were managed with endolaser and one case with 240BB All SFIOL cases had good post-operative visual outcome.

Of the patients who were left aphakic, one patient SF6 tamponade was done with good post-operative visual outcome. Another patient was treated with silicon oil injection and cryotherapy, who progressed to secondary glaucoma and optic atrophy. The other 7 patients were managed with cryotherapy +/- endolaser, with good post-operative visual outcome.

The early post-operative complications were seen in 6 patients with SFIOL(40%), 1 patients with ACIOL implantation(50%) and 14 patients (93.33%)who were left aphakic.

Fibrin reaction was seen in 2 cases with primary SFIOL, 1 case of ACIOL implantation 5 cases left aphakic.(25%) Fibrin reaction is a result of extensive intraoperative uveal tissue manipulation. Extensive fibrin reaction is seen in patients when eye is already inflamed due to previous trauma/surgery or diabetes.¹⁴ Kwong and kanigowska K in their study documented anterior uveitis in 5 eyes(16.7%)which was mainly due to iris manipulation. This lower incidence maybe due to

increased interval between the initial and secondary procedure which helped the inflammation to come down.

In our study, 27 out of 32 patients(84%) had a traumatic aetiology which explains the fibrin reaction post-operatively.

Corneal oedema was seen in 2 patients with SFIOL implantation, one in whom the cataractous lens was dislocated into anterior chamber. The endothelial-lenticular touch would have led to endothelial cell loss contributing to corneal oedema. The second SFIOL implantation case with post-operative corneal oedema later progressed to develop retinal detachment.

2 patients left aphakic had corneal oedema. They progressed to develop aphakic bullous keratopathy and secondary glaucoma.

The late post-operative complications were observed in 4 patients(26.67%) of SFIOL group and 4 patients(26.67%) in the aphakic group. Secondary glaucoma developed in 4 patients(12.5%), two each from SFIOL and Aphakic groups. In a study conducted by¹⁶ Kakarla et al secondary glaucoma was the most common complication described after vitrectomy for retained lens fragment(7.8%). Similar observation was made in our study also with secondary glaucoma being the most common late post-op complication although with slightly higher rate of incidence (12.5%). Underlying mechanisms can be lens particle glaucoma, retained viscoelastic material and steroid induced raised IOP.

Retinal detachment was noted in 2 patients, one each from SFIOL and Aphakia group.

CME was noted in one patient who was left aphakic.

In 1 patient whom ACIOL was implanted, persistence of post-operative uveitis was noted, and the best corrected visual outcome for this patient was 6/36.

On comparing the incidence of complications, SFIOL group and those left aphakic had more complications in early post-operative period, but they gradually subsided in the SFIOL group with progressive improvement in BCVA. The patients left aphakic had more severe and sight threatening complications which progressively led to diminution in final visual outcome.

Conclusion

The surgical correction for patients with dislocated cataractous lens begins with a thorough clinical history, extensive clinical examination, and appropriate referral to medical specialists to evaluate potential metabolic and systemic abnormalities. With the advent and development of current adjunctive surgical devices, most of these cases can now be treated with excellent visual and anatomic results.

Excellent outcomes are possible for patients undergoing vitrectomy for retained lens fragments.

Most of the complications are correlated with vitreous manipulation by the cataract surgeon in attempts to retrieve dislocated lens material and in part due to traumatic etiology. A good visual prognosis is expected if both the anterior segment and vitreoretinal surgeons rigorously avoid vitreous traction in these cases. An AC IOL may pose a risk to the corneal endothelium if not properly sized, resulting in long-term corneal decompensation. Therefore, it may be desirable to avoid AC IOLs in patients whose life expectancy is greater than 20 years. In our study, the best visual outcome was obtained with the use of 3PPPV with PFCL assisted lensectomy/ lens removal and implantation of SFIOL.

References

1. Soo Jung Lee, In Geun Kim, Jung Min Park. Management of posteriorly dislocated crystalline lens with perfluorocarbon liquid and fibrin glue-assisted scleral-fixated intraocular lens implantation. *J Cataract Refract Surg.* 2013 Mar;39(3):334-8.
2. Kim IK, Miller JW. Management of dislocated lens material. *Semin Ophthalmology.* 2002 Sep-Dec;17(3-4):162-6.
3. Raza M. Shah, Sunir J. Garg. Management of retained intraocular lens fragments plays a great role in determining the final visual acuity. Review of *Ophthalmology.*
4. Stewart M. Managing retained lens fragments: Raising the bar. *Am J Ophthalmol* 2009;569-570.
5. Naresh K Yadav, Vasudha Kemmanu, Mayuri Bhargava, and Bhujanga Shetty. A truly knotless technique for scleral fixation of intraocular lenses: Two-year results. *Indian J Ophthalmol.* 2012 Mar-Apr;60(2):147-148.
6. Masaki Sato. Visco-perfluorocarbon sandwich technique useful for luxated hard cataractous lenses. *Ocular Surgery News U.S. Edition,* June 10, 2012.
7. Richard S. Hoffman, Michael E. Snyder, Uday Devgan, Quentin B. Allen, Ronald Yeoh, Rosa Braga-Mele. Management of the subluxated crystalline lens. *J Cataract Refract Surg* 2013;39:1904-1915.
8. Gabor, S.G.B., Pavlidis, M.M. Sutureless intrascleral posterior chamber intraocular lens fixation. *J Cataract Refract Surg.* 2007;33:1851-1854.
9. Merani R, Hunyor AP, Playfair TJ, et al. Pars plana vitrectomy for the management of retained lens material after cataract surgery. *Am J Ophthalmol* 2007;144:364-370.
10. Ho LY, Doft BH, Wang L, Bunker C. Clinical predictors and outcomes of pars plana vitrectomy for retained lens material after cataract extraction. *Am J Ophthalmol* 2009;587-594.
11. Agarwal, A., Kumar, D.A., Jacob, S., Baid, C., Agarwal, A., Srinivasan, S. Fibrin glue-assisted sutureless posterior chamber intraocular lens implantation in eyes with deficient posterior capsules. *J Cataract Refract Surg.* 2008;34:1433-1438.
12. Scharioth, G.B., Prasad, S., Georgalas, I., Tataru, C., Pavlidis, M. Intermediate results of sutureless intrascleral posterior chamber intraocular lens fixation. *J Cataract Refract Surg.* 2010;36:254-259.
13. Moore, J.K., Scott, I.U., Flynn, H.W. Jr., Smiddy, W.E., Murray, T.G., Kim, J.E., Vilar, N.F., Pereira, M.B., Jorge, R. Retinal detachment in eyes undergoing pars plana vitrectomy for removal of retained lens fragments. *Ophthalmology.* 2003;110:709-13 (discussion by TM Aaberg Jr, 713-714).
14. Kwong, Y.Y.Y., Yuen, H.K.L., Lam, R.F., Lee, V.Y.W., Rao, S.K., and Lam, D.S.C. Comparison of outcomes of primary scleral-fixated versus primary anterior chamber intraocular lens implantation in complicated cataract surgeries. *Ophthalmology.* 2007;114:80-85.
15. Numa, A., Nakamura, J., Takashima, M., and Kani, K. Long-term corneal endothelial changes after intraocular lens implantation; anterior vs posterior chamber lenses. *Jpn J Ophthalmol.* 1993;37:78-87.
16. Kakarla V Chalam, Ravi K Murthy, Joshua C Priluck, Vijay Khetpal, and Shailesh K Gupta. Concurrent removal of intravitreal lens fragments after phacoemulsification with pars plana vitrectomy prevents development of retinal detachment. *Int J ophthalmol* 2015;8(1):89-93.