

Content available at: <https://www.ipinnovative.com/open-access-journals>

Indian Journal of Clinical and Experimental Ophthalmology

Journal homepage: www.ijceo.org

Original Research Article

Visual evoked potential as an early assessment tool in ethambutol-induced toxic optic neuropathy during treatment of tuberculosis

Anita Misra^{1*}, Santosh Kumar Sethi¹, Partha Singh¹¹Dept. of Ophthalmology, R.I.O, SCB Medical College and Hospital, Cuttack, Odisha, India

ARTICLE INFO

Article history:

Received 07-02-2024

Accepted 23-03-2024

Available online 04-07-2024

Keywords:

Visual evoked potential

Ethambutol in TB

Ethambutolinduced toxic optic neuropathy

Psycho physical abnormalities

ABSTRACT

Aim: The objective of this study was to determine whether visual evoked potential (VEP) may be utilized as a screening tool for Ethambutol-induced toxic optic neuropathy (EITON) and whether discontinuing the use of Ethambutol will reverse the signs and symptoms of EITON in patients who are suffering from tuberculosis.

Materials and Methods: Following receipt of authorization from the Institutional Ethics Committee to proceed with the present study, the study officially got underway. The World Health Organization recommended that forty people who had been diagnosed with tuberculosis get ethambutol medication for a period of six months at a dosage of 15-19 milligrams per kilogram of body weight. These patients were inspected both before and after receiving the treatment. Visual function tests and visual evoked potential (VEP) tests were administered to each patient to assess the visual pathway's condition.

Results: An irregular VEP pattern was seen in seven patients out of forty individuals, which accounts for 17.5% of the total. Among these seven patients, delayed P100 latency was observed in all seven patients (17.5%), and an aberrant amplitude difference was documented in one patient (2.5%). There were four patients (10%) who were found to have suboptimal visual acuity, and there were three patients (7.5%) who were found to have problems with their colour vision. An association between low visual acuity and increased P100 delay values was discovered in three out of seven cases. This was the case that was investigated. One patient's visual acuity and colour vision had decreased after two months of Ethambutol therapy, while three patients' visual acuity and colour vision had decreased within four to six months of medication. Due to the absence of abnormalities in the fundus, a diagnosis of retrobulbar optic neuritis was made in these four cases, constituting 10% of the total. There was a full reversal of P100 delay in three patients (43%) out of seven and a partial reversal in four (57%) out of seven.

Conclusion: Our study demonstrates that even at the recommended doses of ethambutol, a timely and routinely performed pattern VEP can detect a significant proportion of cases of subclinical optic neuritis. Furthermore, it demonstrates that the signs and symptoms of ocular toxicity can be reversed in a significant number of these patients after the cessation of Ethambutol treatment.

This is an Open Access (OA) journal, and articles are distributed under the terms of the [Creative Commons Attribution-NonCommercial-ShareAlike 4.0 License](https://creativecommons.org/licenses/by-nc-sa/4.0/), which allows others to remix, tweak, and build upon the work non-commercially, as long as appropriate credit is given and the new creations are licensed under the identical terms.

For reprints contact: reprint@ipinnovative.com

1. Introduction

Despite several research efforts and Indian National Programs such as DOTS, tuberculosis (T.B.), which is caused by the slow-growing acid-fast bacilli

Mycobacterium tuberculosis, continues to be a severe infectious public health concern that is endemic to impoverished nations. Ethambutol Hydrochloride, which is a bacteriostatic drug (F.D.A. Category C) and is a blessing in the battle against tuberculosis,^{1,2} is used in the first line of treatment against tuberculosis (T.B.). One to five per cent of people who use Ethambutol may experience visual

* Corresponding author.

E-mail address: anitmisra@gmail.com (A. Misra).

abnormalities as a side effect.^{3,4} Ocular toxicity caused by Ethambutol is mostly caused by Ethambutol-induced Toxic Optic Neuropathy (EITON), which can be speculated to be caused by mitochondrial disruption or zinc-chelating metabolites in the axons of the optic nerve.¹ Both axonal swelling and demyelination of the optic nerve, chiasma, and optic tract^{5–9} can cause a delay in axonal transport, which can then lead to axonal loss.^{10–12} Both factors can cause this delay in axonal transport. In patients with optic neuritis, the most common symptoms are decreased visual acuity and colour vision, a loss of contrast sensitivity, and abnormalities in the visual field, such as central scotoma.^{2,13} One of the most significant obstacles to patient compliance and the continuation of therapy is the lengthy course of tuberculosis (T.B.), as well as the substantial side effects of anti-TB medications, particularly those that affect the retina and the optic nerve. According to some recent studies, those affected by EITON frequently experience significant and long-lasting visual impairments.^{12,14,15} The early discovery of Ethambutol's adverse effects and the subsequent discontinuation of the medication may, however, result in the reversibility of symptoms.¹⁶ To diagnose clinical EITON, it has been determined that the Visual Field Test, the RNFL OCT, the Contrast Sensitivity Test, the VEP, the Electro-retinogram, and the Electro-oculogram have proven to be useful diagnostic techniques.¹⁷ Early identification of the neurotoxic effects of aminoglycosides and phenytoin has been accomplished by using somatosensory and auditory evoked potentials. In a similar vein, the VEP study can be applied to discover EITON that is not clinically present.^{15–18} The delay in the latency of the VEP has been demonstrated to be an early indicator of the toxicity of Ethambutol.^{19,20} Although both the amplitude and the latency of P100 fluctuate under these circumstances, the latency of P100 values is a more accurate indication since the amplitude of P100 demonstrates subjective variance.²¹

2. Aim

When it comes to Ethambutol-induced toxic optic neuropathy (EITON), the primary objective of this research was to determine whether a VEP study that is performed on time and a routine basis can be utilized as a screening tool to detect subclinical changes in the optic nerve. Additionally, the secondary objective was to determine whether discontinuing the use of Ethambutol can reverse the signs and symptoms of EITON in tuberculosis patients.

3. Materials and Methods

There were forty patients, nine of whom were female and thirty-one of whom were male, who fulfilled the inclusion criteria. Additionally, forty healthy controls were matched for gender and age. Over the course of one year, beginning

in December 2022 and ending in November 2023, the research was a prospective observational study that was conducted on patients who were being treated in the outpatient or inpatient department of Pulmonary Medicine and were referred to the department of ophthalmology at R.I.O, S.C.B Medical college and hospital in Cuttack. Participants were required to meet the following inclusion criteria: they were between the ages of 18 and 50, had a clinical diagnosis of pulmonary or extrapulmonary tuberculosis, and were scheduled to begin anti-tubercular therapy with Ethambutol at a dosage of 15–19 mg/kg. Additionally, they were required to join the study after providing their permission in their native language. Patients who had a previous history of visual abnormalities, patients who were lost to follow-up, patients who had the renal illness, patients who had cerebral or meningeal tuberculosis, and patients who were using any other neurotoxic medicines or intoxicants were not allowed to participate in this study. This is because these various disorders interfere with the P100 latency of VEP.

3.1. Examination in ophthalmology Opd

Visual field test with goldmann perimetry, visual acuity test with Snellen's chart, and visual depth test with Goldmann. In addition to the fundus examination using an indirect ophthalmoscope and an optical coherence tomography RNFL, the colour vision test using the Ishihara chart, the contrast sensitivity test using the Pelli Robson chart, and the Amsler grid, Layout of an electroencephalogram was used to perform a visual evoked potential. A comprehensive neuro-ophthalmological evaluation was performed on the participants and the controls at the study's beginning.

Once the treatment had been completed for three months, all the visual tests described before were performed monthly until the conclusion of the treatment at six months, and then again after six months following the cessation of Ethambutol.

After explaining, at one meter from the VEP monitor, after patching one eye and concentrating the other eye on a tiny square in the middle of the room, each of the eyes was treated to mono-ocular visual evoked potentials (VEPs) using an established protocol. An impedance of less than 5000 ohms was provided for the connected scalp electrodes. For either O1-Fz or O2-Fz montages, O1-Fz served as a reference point for the final product. An electronic pattern generator that was implemented within the RMS EMG EP MARK-II was responsible for the production of a checkerboard pattern that was black and white in colour. At one meter, the subject's eye was tilted at a vertical angle of 32 degrees and a horizontal angle of 14 degrees, and the check was eight squares by eight squares. It was determined that there was a 67% difference in contrast between the black checks, 6.31 feet-L brilliant, and the white checks, 31.6 feet-L brilliant. An evoked potential recorder was

utilized to collect an average of 256 answers. This recorder was equipped with line filters and low and high-frequency filters ranging from 2 to 100 Hz. While the checks were being flipped, line filters were being utilized at a frequency of one hertz. It was necessary to take at least two distinct measurements to guarantee repeatability. In addition, the amplitude and latency of the P100 signal compared to the N70 were assessed, focusing on the association between the P100 amplitude and the P100 latency. The procedure for testing on humans was carried out per the ethical principles described in the Helsinki Declaration of 1964.

3.2. Statistical analysis

First, the mean, standard deviation, and P value at the beginning of anti-tubercular therapy; next, at monthly intervals of treatment up to six months; and lastly, at six months after the end of Ethambutol therapy or the withdrawal of treatment.

4. Results

Table 1 is a summary of the results that were discovered throughout the study. Shahrokhi²² defined "abnormality" as anything that exceeded 116 milliseconds in P100 latency, exceeded eight milliseconds in latency difference between the two eyes, exceeded 6 volts in amplitude difference between the two eyes, or prevented recording of a measurable response. This definition was included in his groundbreaking paper on VEP.

Forty people participated in the study, and seven patients, or 17.5%, exhibited aberrant VEP. All seven patients, which account for 17.5% of the total, were found to have a prolonged P100 delay of more than 116 milliseconds in both eyes. Even while amplitude changes were given less weight, we discovered a link between a drop in P100-N70 amplitude and increased P100 latency. This led us to conclude that there is a connection between the two. This relationship became readily visible after a reduction in the strength of the P100-N70 signal. Patient A was diagnosed with a serious anomaly since their P100 latency range was between 140 and 148 milliseconds, and there was an 8-millisecond differential in the P100 latency between their two eyes. Even though the P100 delay was just 118 milliseconds and 119 milliseconds, we discovered an abnormal amplitude difference of 7 volts between two eyes in only one patient, approximately 2.5 per cent of the total. The clinical evaluation revealed that three of the seven people did not demonstrate any objective changes in their fundi, colour vision, or visual acuity. An association between low visual acuity and increased P100 delay values was discovered in three out of seven cases. This was the case that was investigated. There were four patients (10%) who were found to have suboptimal visual acuity, and there were three patients (7.5%) who were found to have problems with

their colour vision. Patients B, A, and F also reported feeling hazy vision after 4-6 months of medication. Colour vision was determined to be deficient in all of them except for patient F. Patient D's visual acuity and colour vision were decreased after two months of treatment. Due to the absence of abnormalities in the fundus, a diagnosis of retrobulbar optic neuritis was made in these four cases, constituting 10% of the total.

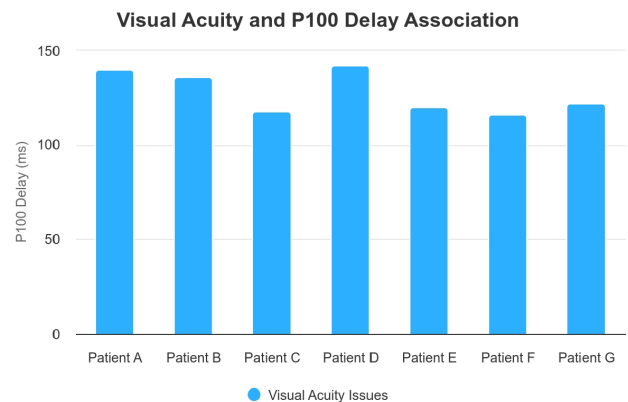


Figure 1: 1. The x-axis represents the patients (A to G). 2. The y-axis represents the P100 Delay values in milliseconds. 3. Each column represents the P100 Delay value for a specific patient, indicating the association between visual acuity issues and increased P100 delay values.

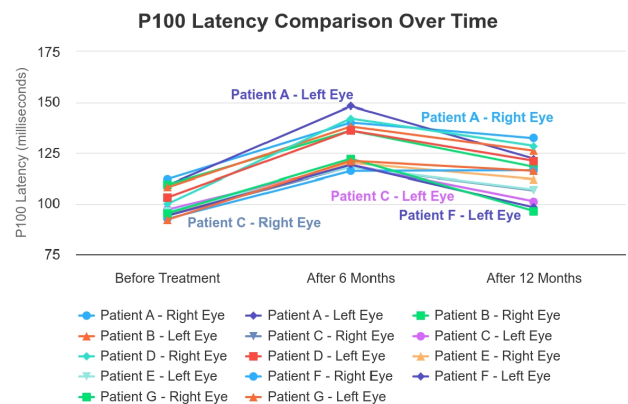


Figure 2:

Table 2 demonstrates a comparison of the P100 latency in seven patients who were receiving Ethambutol medication and had aberrant visual evoked potential at three different time intervals: before treatment (one month), after treatment (six months), and after treatment (twelve months). Before the beginning of therapy with an anti-tubercular regimen that included Ethambutol. Table 1 contains a comprehensive discussion of the data obtained at the end of the sixth month after the conclusion of therapy. The table reveals that all seven (17.5%) patients had a prolonged P100 delay of

Table 1: Results in the study population of 7 patients with visually evoked potential (VEP) abnormalities out of 40 patients

Patient	Age	Sex	P ₁₀₀ Latency (ms)		Latency. Difference (ms)	Amplitude. Difference (μV)	Binocular Best Corrected Vision	Binocular Color Vision
			Right	Left				
A	38	M	140	148	8	1.6	6/12	Abnormal
B	43	F	136	138	2	1.4	6/18	Abnormal
C	25	F	118	119	1	7	6/6	N
D	22	M	142	136	6	2	6/24	Abnormal
E	31	M	120	118	2	5	6/6	N
F	22	M	116	119	3	5.2	6/9	N
G	44	F	122	121	1	3.1	6/6	N

Table 2: Comparison of P100 latency in 7 patients with abnormal visual evoked potential on ethambutol at pre-treatment (1st month), end of treatment (6th month) and post-treatment (12th month) intervals

Case	P ₁₀₀ Latency (ms)					
	Pre-treatment(1 st month)		End of Treatment(6 th month)		Post-treatment(12 th month)	
	Right eye	Left eye	Right eye	Left eye	Right eye	Left eye
A	112	109	140	148	132.2	122
B	109.2	108	136	138	118	126
C	94	97	118	119	106.4	101
D	99.8	103	142	136	128.4	121
E	94.3	96	120	118	112	106.8
F	92.4	94	116	119	116.3	98
G	95.2	92	122	121	96.2	116

more than 116 milliseconds in both eyes. Four out of seven patients remained to have a prolonged P100 delay of more than 116 milliseconds at the end of the 12th month, precisely six months after the medication had been discontinued. These patients had no obvious defects in their vision or optic nerve. There was a full reversal of P100 delay in three patients, C, E, and G, which accounts for 43 percent of the total cases, and a partial reversal in four patients, A, B, D, and F, which accounts for 57 percases.

5. Discussion

A significant amount of research has focused on EITON, and these studies have employed a wide variety of visual function factors so that they may conduct their investigation. Studies have been carried out, and according to that research, the rate of Ethambutol toxicity might range anywhere from 0.62% to 63%, depending on the degree of sensitivity of the test.^{23,24} Certain factors include visually evoked potentials, critical flicker frequency, visual acuity, ophthalmoscopy, colour vision testing, contrast sensitivity, pupillary responses, and pupil cycle time. Other parameters include ophthalmoscopy and colour vision testing. By utilizing the visual pathway that originates from the retina, the visual evoked potential (VEP) is utilized to assess the functioning of the occipital cortex. VEP provides medical personnel with the capacity to diagnose EITON at an earlier stage, allowing them to change treatment techniques as required for successful treatment of tuberculosis (TB) without putting patients' vision in danger. Despite the fact

that the physical indicators of visual function are often normal, abnormalities in visual evoked potentials (VEP) indicate that there are subtle physiological alterations. There is a possibility that the initial indicator of the development of EITON is a loss in visual acuity. Among the patients who participated in our study, only four individuals, or ten per cent, exhibited any indications of a deterioration in their best-corrected visual acuity. An association between low visual acuity and increased P100 delay values was discovered in three out of seven cases. This was the case that was investigated.

Those given Ethambutol have been shown to have impaired vision in the red and green hues.^{23–26} This has been proved through research. An improvement in the detection of toxicity can be attributed to the employment of tests with a higher level of sensitivity, such as the Farnsworth-Munsell 100 hue.²⁴ During our examination, which was conducted using Ishihara charts, we found that just three of our patients (7.5%) had an aberrant colour perception. According to Bruegger et al.,²⁷ the sensitivity of the Ishihara charts is not enough to identify less severe forms of colour vision issues. According to Smith et al.,²⁸ observations have been made on the findings of disc oedema, hyperemia, and uneven disc boundaries. During our investigation, we did not come across any patients who exhibited an aberrant fundus image; nonetheless, retrobulbar neuritis was present in most people diagnosed with EITON. Garg et al.²⁹ revealed no association between the total amount of Ethambutol eaten and the severity of the

EITON. According to their findings, there is no correlation. The findings of Fledelius and colleagues³⁰ indicated that chronic P100 component delay was observed in VEP, even when the harm induced by Ethambutol had recovered to a satisfactory level. Because of the remarkable capacity of the visual system to adjust for axonal loss, Heidari et al. concluded that clinical criteria might not effectively depict an underlying disease process that poses a danger to the integrity of axons.³¹ Because of this, VEP has the potential to be exploited objectively to diagnose and track early axonal damage in cases of Ethambutol poisoning that affects the optic nerve.

6. Conclusion

In prospective research that we conducted on patients who were beginning treatment with anti-tubercular therapy (ATT), we identified individuals who had ocular defects during the intense or continuation phase of the treatment with the VEP study and followed up with them following the completion of the study. According to the findings of our study, VEP testing has the potential to detect a surprisingly high number of instances of subclinical ocular neuritis that occur after treatment with Ethambutol. This is the case even when the drug is administered in safe doses. Considering the findings of this study, we would like to underline the significance of doing pattern-VEP studies on time and on a routine basis to identify subclinical changes in the optic nerve that occur after Ethambutol medication and the termination of Ethambutol to reverse the signs and symptoms of ocular toxicity associated with these individuals.

7. Implication of Study

We believe that, among the Visual Function Tests utilized, Pattern VEP is the most ideal for early diagnosis and prognosis follow-up in cases of Ethambutol-induced ocular toxicity. This is because it has been evaluated over time, is widely available, cost-effective, non-invasive, and is a straightforward process for patients, technicians, and interpreters. It is also worth noting that most patients who experience ocular toxicity as a result of Ethambutol medication return to normal test functions six months after they stop taking Ethambutol. This prevents an iatrogenic problem that might result in blindness.

8. Limitations of Study

This study was conducted in the outpatient department of a hospital and may not reflect the population. Additionally, the trial period and sample size were shorter, and no follow-up analysis was performed to evaluate the long-term results of the two groups.

9. Source of Funding

None.

10. Conflict of Interest

There is no conflict of interest among the present study authors.


References

1. Sarmah DT, Parveen R, Kundu J, Chatterjee S. Latent tuberculosis and computational biology: A less-talked affair. *Prog Biophys Mol Biol*. 2023;178:17–31.
2. Liebenberg D, Gordhan BG, Kana BD. Drug-resistant tuberculosis: Implications for transmission, diagnosis, and disease management. *Front Cell Infect Microbiol*. 2022;12:943545.
3. Zoumalan CI, Agarwal M, Sadun AA. Optical coherence tomography can measure axonal loss in patients with ethambutol-induced optic neuropathy. *Graefes Arch Clin Exp Ophthalmol*. 2005;243(5):410–6.
4. Chan RY, Kwok AK. Ocular toxicity of Ethambutol. *Hong Kong Med J*. 2006;12:56–60.
5. Kyncl M, Fus M, Lestak J. Ethambutol-induced optic neuropathy. *Biomed Pap Med Fac Univ Palacky Olomouc Czech Repub*. 2022;167(3):288–93.
6. Sen S, Mandal S, Banerjee M, Gk R, Saxena A, Aalok SP, et al. Ethambutol-induced optic neuropathy: Functional and structural changes in the retina and optic nerve. *Semin Ophthalmol*. 2022;37(6):730–9.
7. Schmidt IG. Central nervous system effects of Ethambutol in monkeys. *Ann N Y Acad Sci*. 1966;135(2):759–74.
8. Lessell S. Histopathology of experimental ethambutol intoxication. *Invest Ophthalmol Vis Sci*. 1976;15(9):765–9.
9. King AB, Schwartz R. Effects of the antituberculous drug ethambutol on zinc absorption, turnover and distribution in rats fed diets marginal and adequate in zinc. *The Journal of Nutrition*. 1987;117(4):704–8.
10. Makunyane P, Mathebula S. Update on ocular toxicity of ethambutol. *Afr Vis Eye Health*. 2016;75(1):353.
11. Matsuoka Y, Takayanagi T, Sobue I. Experimental ethambutol neuropathy in rats. Morphometric and teased-fibre studies. *J Neurol Sci*. 1981;51(1):89–99.
12. Dubey A, Ghosh N, Saxena GK, Purohit D, Patel S, Singh S. Management implications for neurotoxic effects associated with antibiotic use. *Neuro-Quantol*. 2022;20:304–28.
13. Oken BS, Chiappa KH, Gill E. Normal temporal variability of the P100. *Electroencephalogr Clin Neurophysiol*. 1987;68(2):153–6.
14. Rezaei NJ, Bazzazi AM, Alavi SA. Neurotoxicity of the antibiotics: A comprehensive study. *Neurol India*. 2018;66(6):1732–40.
15. Bangert MK, Hasbun R. Neurological and psychiatric adverse effects of antimicrobials. *CNS Drugs*. 2019;33(8):727–53.
16. Menon V, Jain D, Saxena R, Sood R. Prospective evaluation of visual function for early detection of ethambutol toxicity. *Br J Ophthalmol*. 2009;93(9):1251–4.
17. Kim KL, Park SP. Visual function test for early detection of Ethambutol-induced ocular toxicity at the subclinical level. *Cutan Ocul Toxicol*. 2015;35(3):228–32.
18. Interlandi E, Pellegrini F, Giuffrè C, Cirone D, Brocca D, Lee AG, et al. Acute-Onset Retinal Conditions Mimicking Acute Optic Neuritis: Overview and Differential Diagnosis. *J Clin Med*. 2023;12(17):5720.
19. Lal V, editor. A Clinical Approach to Neuro-Ophthalmic Disorders. C.R.C. Press; 2022.
20. Yiannikas C, Walsh JC, McLeod JG. Visual Evoked Potentials in the Detection of Subclinical Optic Toxic Effects Secondary to Ethambutol. *Arch Neurol*. 1983;40(10):645–8.
21. Sokol S. Pattern visual evoked potentials: their use in pediatric ophthalmology. *Int Ophthalmol Clin*. 1980;20(1):251–68.

22. Shahrokhi F, Chiappa KH, Young RR. Pattern shift visual evoked responses: two hundred patients with optic neuritis and multiple sclerosis. *Arch Neurol*. 1978;35(2):65–71.
23. Polak BC, Leys M, Lith GHV. Blue-yellow color vision changes are early symptoms of ethambutol oculotoxicity. *Ophthalmologica*. 1985;191(4):223–6.
24. Trusiewicz D. Farnsworth 100-hue test in diagnosing ethambutol-induced damage to the optic nerve. *Ophthalmologica*. 1975;171(6):425–31.
25. Belcher SJ, Greenshields KW, Wright WD. Colour vision survey using the Ishihara, Dvorine, Boström and Kugelberg, Boström, and American-Optical Hardy-Rand-Rittler tests. *Br J Ophthalmol*. 1958;42(6):355–9.
26. Belcher SJ, Greenshields KW, Wright WD. Colour vision survey: using the Ishihara, Dvorine, Boström and Kugelberg, Boström, and American-Optical Hardy-Rand-Rittler tests. *Br J Ophthalmol*. 1958;42(6):355–9.
27. Bruegger D, Koth AL, Dysli M, Goldblum D, Abegg M, Tschopp M, et al. Evaluation of the Reddesa Chart, a New Red Desaturation Testing Method, for Optic Neuritis Screening and Grading in Clinical Routine. *Front Neurol*. 2022;13:898064.
28. Smith JL. Should Ethambutol be barred? . *J Clin Neuro-ophthalmol*. 1987;7(2):84–6.
29. Garg P, Garg R, Prasad R, Mishra AK. A prospective study of ocular toxicity in patients receiving Ethambutol as a part of directly observed treatment strategy therapy. *Lung India*. 2015;32(1):16–9.
30. Fledelius HC, Petrera JE, Skjöldt K, Trojaborg W. Ocular ethambutol toxicity: A case report with electrophysiological considerations and a review of Danish cases 1972–81. *Acta Ophthalmol (Copenh)*. 1987;65(2):251–5.
31. Heidari M, Radcliff AB, Mclellan GJ, Hoeve JNV, Chan K, Kiland JA, et al. Evoked potentials as a biomarker of remyelination. *Proc Natl Acad Sci U S A*. 2019;116(52):27074–83.

Author biography

Anita Misra, Assistant Professor  <https://orcid.org/0009-0000-5694-2126>

Santosh Kumar Sethi, Associate Professor  <https://orcid.org/0009-0002-8605-4757>

Partha Singh, Senior Resident  <https://orcid.org/0009-0007-8035-5352>

Cite this article: Misra A, Sethi SK, Singh P. Visual evoked potential as an early assessment tool in ethambutol-induced toxic optic neuropathy during treatment of tuberculosis. *Indian J Clin Exp Ophthalmol* 2024;10(2):373-378.