

Content available at: <https://www.ipinnovative.com/open-access-journals>

Indian Journal of Clinical and Experimental Ophthalmology

Journal homepage: [www.ijceo.org](http://www.ijceo.org)

## Original Research Article

## A prospective comparative study of conjunctival autograft (CAG) with dry amniotic membrane graft (AMG) transplantation in pterygium excision surgery

Avinash Gupta<sup>1\*</sup>, Ramyash Singh Yadav<sup>2</sup>, Ram Kumar<sup>2</sup><sup>1</sup>Dept. of Ophthalmology, MVAS Medical College, Basti, Uttar Pradesh, India<sup>2</sup>Dept. of Ophthalmology, BRD Medical College, Gorakhpur, Uttar Pradesh, India

## ARTICLE INFO

## Article history:

Received 22-07-2023

Accepted 09-11-2023

Available online 30-03-2024

## Keywords:

Pterygium

Conjunctival autograft (CAG)

Amniotic membrane graft (AMG)

## ABSTRACT

**Context:** Pterygium is a wing-shaped, fibrovascular proliferation of the bulbar conjunctiva which crosses the limbus and causes encroachment over the cornea. It is mainly treated by surgical excision. Management options for pterygium include conjunctival autografting, and the use mitomycin C, amniotic membrane graft, 5-fluorouracil, anti-vascular endothelial growth factor (anti-VEGF) agents, and  $\beta$ -irradiation along with excision, to avoid recurrence.

**Aims:** To compare the efficacy and safety of conjunctival autograft (CAG) transplantation and dry amniotic membrane graft (AMG) transplantation in pterygium excision surgery.

**Settings and Design:** Prospective comparative study.

**Materials and Methods:** The study was done on 43 eyes of 43 patients. CAG was transplanted on 23 patients & dry AMG was transplanted on 20 patients. All patients were followed up on day 1, day 7, 1 month and 6 months post operatively. On each visit pterygium recurrence, graft retraction, necrosis and visual outcomes were noted from all the patients.

**Statistical Analysis Used:** Fisher exact test.

**Results:** 28(65%) were males while 15(35%) were females. Most of the patients were <40 years of age. During the follow up period, best corrected visual acuity of 3(7%) patients remained same and improved in 40(93%) patients. CAG group had 2(8.69%) while dry AMG group had 4(20%) recurrences (p value = 0.39, non-significant).

**Conclusions:** Although both the groups showed low recurrence rate but recurrence rate was more in dry AMG group as compared to conjunctival autograft group.

**Key Messages:** AMG is not always the best option for treating pterygium, but in some situations—such as those with extensive pterygium, conjunctival scarring etc.—it may be more advantageous for the patient.

This is an Open Access (OA) journal, and articles are distributed under the terms of the [Creative Commons Attribution-NonCommercial-ShareAlike 4.0 License](https://creativecommons.org/licenses/by-nc-sa/4.0/), which allows others to remix, tweak, and build upon the work non-commercially, as long as appropriate credit is given and the new creations are licensed under the identical terms.

For reprints contact: [reprint@ipinnovative.com](mailto:reprint@ipinnovative.com)

## 1. Introduction

Pterygium is a wing-shaped, fibrovascular proliferation of the bulbar conjunctiva that crosses the limbus and causes encroachment over the cornea.<sup>1,2</sup> The encroachment of the corneal surface may result in considerable visual morbidity, including corneal opacity, irregular astigmatism, corneal redness, irritation and foreign body sensation.<sup>2,3</sup> It is

situated in the interpalpebral area. The most common site for pterygium formation is the nasal limbus. Pterygium formation has been associated with outdoor occupation and activities, most likely as a result of exposure to ultraviolet (UV) radiation, in numerous studies.<sup>4,5</sup>

Pterygium is primarily treated through surgical excision. Recurrence is the main challenge with pterygium surgery. Conjunctival autografting, mitomycin C, amniotic membrane grafting, 5-fluorouracil, anti-vascular endothelial

\* Corresponding author.

E-mail address: [avinashgupta1001@gmail.com](mailto:avinashgupta1001@gmail.com) (A. Gupta).

growth factor (anti-VEGF) medicines along with excision, are most commonly used management options for pterygium.

Bare sclera excision refers to the removal of a pterygium without fixing the remaining defect. The bare sclera approach is no longer advised due to its high rate of recurrence (38% to 88%).<sup>6</sup> Apart from its simplicity and short surgery time, this procedure has no advantages.<sup>7</sup>

Conjunctival autografts (CAG) procedure involves removing the pterygium and utilizing the patient's own grafted conjunctiva to close the remaining defect and fix it with fibrin glue or sutures. Both superior and inferior conjunctival autografts may be used, although the ipsilateral superior conjunctiva is most frequently used.<sup>8</sup>

Amniotic membrane graft (AMG) is another technique for covering exposed sclera after pterygium removal. Due to their anti-inflammatory qualities, stimulation of epithelial development, and suppression of transforming growth factor  $\beta$  (TGF- $\beta$ ) signaling and fibroblast proliferation, AMGs accelerate healing and lower recurrence rates.<sup>6,9</sup>

## 2. Materials and Methods

### 2.1. Study design

Prospective comparative study.

### 2.2. Study duration

1 year.

### 2.3. Sample size

43 patients with pterygium, who gave proper informed consent and fulfilled the below mentioned inclusion and exclusion criteria were selected for our study among the patients who attended the outpatient Department of Ophthalmology. This study was approved by institutional review board.

### 2.4. Inclusion criteria

1. Age 21-70 years.
2. Any type of pterygium excluding recurrent pterygium with proper grading.

### 2.5. Exclusion criteria

1. Patient not willing to give consent
2. Eyes with any ocular surface disease (squamous cell neoplasia etc.)
3. Patient with major systemic co-morbidities (Diabetes Mellitus, Hypertension etc.)

### 2.6. Technique of pterygium excision

Local anaesthetic agent was given using proper sterile technique, the eye was prepared and draped. The pterygium

head was separated from the cornea by blunt dissection. By using a Westcott scissors, the body of the pterygium was dissected from the limbus and excised toward the fornices. Fibrous adhesions between the underlying muscle and pterygium were removed carefully. The sclera was exposed, after the pterygium was extensively excised. Minimum wet-field cautery was done to achieve hemostasis at the area of the pterygium. Remaining tissues over the corneal surface were cleaned by scraping with a BP blade.

### 2.7. Technique of graft transplantation

After removal of pterygium, grafts were implanted by using following methods:

#### 2.8. CAG

The globe was rotated to expose the supero-temporal conjunctiva. The supero-temporal bulbar conjunctiva was carefully taken to obtain a free graft of the right size without harming the Tenon capsule beneath. Over the exposed sclera, the autograft was applied in the proper anatomical orientation. By using interrupted 10-0 nylon sutures, grafts were then sutured to the surrounding conjunctiva and episclera. The donor site was left unsutured.<sup>10,11</sup>

#### 2.9. AMG

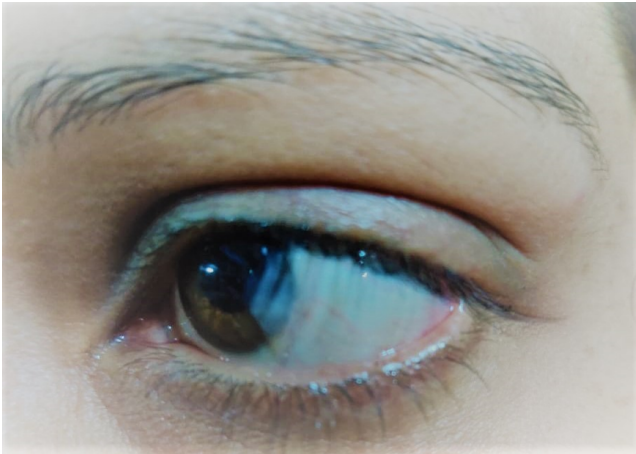
The membrane was removed from the preservation media and sized appropriately to cover the bare sclera. It was thoroughly washed with balanced salt solution. The membrane was spread over the bare sclera so that the epithelial surface was on top. By using interrupted 10-0 nylon sutures, it was sutured to the surrounding conjunctiva and episclera (Figures 1 and 2).<sup>10</sup>

## 3. Results

1. Total 43 patients were taken for evaluation. (Table 1).
2. 28(65.1%) were males and 15(34.9%) were females. In CAG group; 15 males and 8 females were present while in Dry AMG group; 13 males and 7 females were present.
3. Major presenting complaints were: discomfort (10, 23.2%), presence of the fleshy mass in white portion of the eye (9, 20.9%), redness (9, 20.9%), foreign body sensation (5, 11.6%) and diminished vision (2, 4.6%). Some patients had cosmetic complaints also (8, 18.6%).
4. 23 (53.4%) of the patients had previously used topical medications to treat this fleshy mass.
5. Most of the patients (n=28) had preoperative best corrected visual acuity between 6/9 - 6/12 (Table 2). There was improvement of best corrected visual acuity in patients after pterygium surgery. Best corrected visual acuity of 21 patients (91%) improved by one

or more line & remained same in 2 patients (9%) in CAG group while in AMG group; it improved by one or more line in 19 patients (95%) and remained same in 1 patient (5%). However, there was no statistical difference between two groups (p value=1).

- 6. Grafts of two patients were displaced. One in the second and the other in the sixth post-operative follow up visit.
- 7. At the two-week postoperative period, two patients had sutural granulomas, which improved after suture removal and topical steroid therapy.
- 8. During the follow up period, best corrected visual acuity of 3(7%) patients remained same and improved in 40(93%) patients after 6 months of follow up period.
- 9. CAG group had 2(8.69%) while dry AMG group had 4(20%) recurrences (Table 3). There was no statistical significance (p value= 0.39).



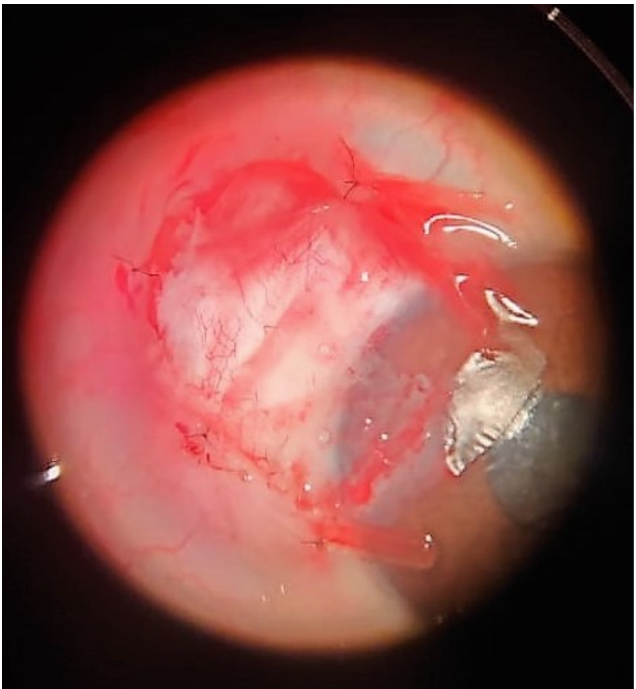
**Figure 1:** Clinical photograph of patient showing primary temporal pterygium

**Table 1:** Age distribution of patients

Age group (years)	CAG	Dry AMG
21-30	4	3
31-40	9	8
41-50	5	4
51-60	3	4
61-70	2	1

4. Discussion

Ophthalmologists continue to have serious concerns about pterygium recurrence despite various methods and advancements in microsurgery. Although surgical management is the only option for the pterygium, the availability of numerous adjuvant therapies for the pterygium in the present era shows that there isn't a single satisfactory and widely accepted therapy option for it.



**Figure 2:** Intraoperative photograph of same patient showing AMG with interrupted 10-0 nylon suture

**Table 2:** The pre operative visual acuity of patients

Visual acuity	Frequency	Percentage
6/9	17	39.5
6/12	11	25.5
6/18	9	20.9
6/24	3	6.9
6/60	3	6.9
Total	43	100

**Table 3:** Recurrences in CAG group anddry AMG group

No. of patients	Procedure	Recurrence
23	CAG	2(8.69%)
20	Dry AMG	4(20%)

In our study, we found that the majority of patients were under 40 years old and came from a variety of occupational backgrounds, from farmers to IT professionals. Pterygium may develop as a result of increased computer use among workers, UV radiation exposure, and dust exposure among farmers.

Males predominated in a research done by Pandey et al.<sup>12</sup> (males, 1051, 75.1%; females, 349, 24.9%). In our study, where 28 participants were male (65.1%) and 15 participants were female (34.9%), similar results were also seen. It implies that males are exposed to the external atmosphere more than females are, proving that the environment is mostly responsible for pterygium production.

In this study, we found that although 40 (93%) patients' best corrected visual acuity increased, 3 (7%) patients' best corrected visual acuity remained the same. Similar findings were made by Allan et al.<sup>13</sup> who examined 93 eyes' preoperative and 3-month postoperative unassisted visual acuities on the Snellen chart. They discovered that in 86 out of 93 instances, the unaided visual acuity was either unchanged or enhanced, whereas seven eyes displayed a deterioration in visual acuity on the Snellen chart. Astigmatism, cataracts, or retinal disease were all contributing factors to the loss in visual acuity.

In order to compare the outcomes of conjunctival autograft and dry amniotic membrane graft using nylon 10-0 suture during pterygium excision surgery, this study was conducted. Conjunctival autografting had a considerably reduced recurrence risk of pterygium following initial excision than AMG, according to a meta-analysis by Li et al.<sup>14</sup> According to Prabhasawat et al.,<sup>15</sup> conjunctival autograft transplantation had a longer time to recurrence than AMG and had considerably higher recurrence rates for treating primary, recurrent, and all forms of pterygia. Similar findings were found in our study as well, where the CAG group had 2 (8.69%) recurrences whereas the dry AMG group had 4 (20%).

## 5. Conclusion

1. AMG has been demonstrated to be less effective than CAG or, at best, comparable to conjunctival autografting (CAG) in the treatment of pterygium.
2. Despite these findings, this method is still useful in the management of pterygium.
3. AMG can be used to fill extensive ocular surface abnormalities, such as in areas of big pterygium.
4. AMG is particularly advantageous when the conjunctiva cannot be harvested due to fibrosis or when the bulbar conjunctiva should be preserved for potential glaucoma filtering surgery in the future.
5. Dry AMG has also been demonstrated to promote the retention of beneficial factors that provide the membrane with advantageous qualities and to provide higher maintenance of structural and biochemical integrity. Additionally, dry AMG is stable and portable, making it a worldwide accessible option for usage in the medical and defense sectors.
6. Therefore, even though using AMG to treat pterygium is not always the best option, there are some situations in which doing so could be most advantageous for the patient.

## 6. Source of Funding

None.

## 7. Conflict of Interest

None.

## References

1. Chui J, Girolamo ND, Wakefield D, Coroneo MT. The pathogenesis of pterygium: current concepts and their therapeutic implications. *Ocul Surf*. 2008;6(1):24–43.
2. Nouredin GS, Yeung SN. The use of dry amniotic membrane in pterygium surgery. *Clin Ophthalmol*. 2016;10:705–12.
3. Rong SS, Peng Y, Liang YB, Cao D, Jhanji V. Does cigarette smoking alter the risk of pterygium? A systematic review and meta-analysis. *Invest Ophthalmol Vis Sci*. 2014;55(10):6235–43.
4. Girolamo ND, Chui J, Coroneo MT, Wakefield D. Pathogenesis of pterygia: role of cytokines, growth factors, and matrix metalloproteinases. *Prog Retin Eye Res*. 2004;23(2):195–228.
5. Zhou WP, Zhu YF, Zhang B, Qiu WY, Yao YF. The role of ultraviolet radiation in the pathogenesis of pterygia (Review). *Mol Med Rep*. 2016;14(1):3–15.
6. Janson BJ, Sikder S. Surgical management of pterygium. *Ocul Surf*. 2014;12(2):112–9.
7. Alpay A, Uğurbaş SH, Erdoğan B. Comparing techniques for pterygium surgery. *Clin Ophthalmol*. 2009;3:69–74.
8. Yeung SN, Lichtinger A, Kim P, Elbaz U, Ku JY, Amiran MD. Superior versus inferior conjunctival autografts combined with fibrin glue in the management of primary pterygia. *Cornea*. 2013;32(12):1582–6.
9. Rosen R. Amniotic Membrane Grafts to Reduce Pterygium Recurrence. *Cornea*. 2018;37(2):189–93.
10. Küçükdönmez C, Akova YA, Altınörs DD. Comparison of conjunctival autograft with amniotic membrane transplantation for pterygium surgery: surgical and cosmetic outcome. *Cornea*. 2007;26(4):407–13.
11. Sheppard JD, Mansur A, Comstock TL, Hovanesian JA. An update on the surgical management of pterygium and the role of loteprednol etabonate ointment. *Clin Ophthalmol*. 2014;8:1105–18.
12. Pandey DJ, Mishra VK, Singh YP, Kumar A, Pandey D. Qualitative and quantitative estimation of tear in pterygium. *Indian J Ophthalmol*. 1984;32(5):373–7.
13. Allan BD, Short P, Crawford GJ, Barrett GD, Constable IJ. Pterygium excision with conjunctival autografting: an effective and safe technique. *Br J Ophthalmol*. 1993;77(11):698–701.
14. Li M, Zhu M, Yu Y, Gong L, Zhao N, Robitaille MJ. Comparison of conjunctival autograft transplantation and amniotic membrane transplantation for pterygium: a meta-analysis. *Graefes Arch Clin Exp Ophthalmol*. 2012;50(3):375–81.
15. Prabhasawat P, Barton K, Burkett G, Tseng SC. Comparison of conjunctival autografts, amniotic membrane grafts, and primary closure for pterygium excision. *Ophthalmology*. 1997;104(6):974–85.

## Author biography

**Avinash Gupta**, Senior Resident  <https://orcid.org/0000-0002-5858-5799>

**Ramyash Singh Yadav**, Professor and Head

**Ram Kumar**, Professor

**Cite this article:** Gupta A, Yadav RS, Kumar R. A prospective comparative study of conjunctival autograft (CAG) with dry amniotic membrane graft (AMG) transplantation in pterygium excision surgery. *Indian J Clin Exp Ophthalmol* 2024;10(1):94-97.