

Content available at: <https://www.ipinnovative.com/open-access-journals>

Indian Journal of Clinical and Experimental Ophthalmology

Journal homepage: [www.ijceo.org](http://www.ijceo.org)

## Original Research Article

# A study on epidemiology, clinical profile, management, and outcome of Covid-19-associated rhino-orbital-cerebral mucormycosis in a tertiary hospital in Tamil Nadu

Hannah Ratna Priya<sup>1,\*</sup>, Sumathi Periasamy<sup>1</sup>, Shanmugapriya Sekar<sup>1</sup><sup>1</sup>Dept. of Ophthalmology, TN Dr MGR Medical University, Chennai, Tamil Nadu, India

## ARTICLE INFO

## Article history:

Received 07-12-2022

Accepted 09-01-2023

Available online 30-06-2023

## Keywords:

COVID- 19

Mucormycosis

COVID- 19 associated ROCM

Diabetes mellitus

Steroid therapy

Ophthalmoplegia

Functional endoscopic sinus surgery

Transcutaneous retrobulbar

amphotericin B

## ABSTRACT

**Objective:** The main objective of the study is to estimate determine the patient demographics, comorbidities, and medications used to treat COVID-19, presenting symptoms and signs, and the outcome of management of COVID-19-associated rhino-orbital-cerebral mucormycosis (ROCM).

**Materials and Methods:** A descriptive cross-sectional study was conducted among 50 patients admitted and suspected with Mucormycosis in 3 months duration from May 21 to July 21 Covid pandemic at a tertiary hospital in Villupuram. Written informed consent was taken from patients or nearest of kin. This study was approved by Institutional Ethical Committee of Villupuram.

**Results:** 84% patients among suspected mucormycosis were found to be diabetic, with 70% being males and 61.9% had covid history either covid positive or post covid status. About 60% of suspected mucor cases had h/o oxygen treatment and almost 44% had h/o steroid treatment for their covid treatment. Clinically 40% had extraocular muscle involvement in the form of restricted eye movement to total ophthalmoplegia and mortality was ranging from 37.5-57.14%. Those with proper glycemic control and initiation of treatment at appropriate time with endoscopic sinus debridement and antifungal therapy showed better recovery.

**Conclusion:** The study reveals that COVID-19 associated Mucormycosis has risen dramatically due to interplay of uncontrolled diabetes and in-appropriate corticosteroid use leading to pathogenic invasion and adverse outcomes. The infection has caused high morbidity and mortality among covid positive than post covid patients. It could be minimized by strict diabetic control under appropriate insulin dosage, wise use of steroids/oxygen and timely intervention based on clinical evaluation rather than waiting for investigations could minimize the complications from the infection and shorten the hospital stay.

This is an Open Access (OA) journal, and articles are distributed under the terms of the [Creative Commons Attribution-NonCommercial-ShareAlike 4.0 License](https://creativecommons.org/licenses/by-nc-sa/4.0/), which allows others to remix, tweak, and build upon the work non-commercially, as long as appropriate credit is given and the new creations are licensed under the identical terms.

For reprints contact: [reprint@ipinnovative.com](mailto:reprint@ipinnovative.com)

## 1. Introduction

Mucormycosis is an opportunistic devastating fungal infection caused by filamentous fungi belonging to Order Mucorales and Class Mucormycetes.<sup>1,2</sup> It commonly involves nasal mucosa, sinus, orbit and brain and is acquired from inhalation of spores through nasal route. Being an Angioinvasive fungus it causes occlusion of

blood vessels and result in tissue necrosis. Corona virus disease 19 was established as pandemic by WHO in 2019.<sup>3,4</sup> Recently it led to the emergence of Mucormycosis, declared as a notifiable disease.<sup>4,5</sup> It commonly affects diabetics, immunocompromised and malignancy patients but its prevalence increased during covid pandemic due to various factors.<sup>2</sup> Since there has been an exponential increase of ROCM along with the soaring second wave of COVID-19, this study was done with the aim to determine the patient demographics and population at risk,

\* Corresponding author.

E-mail address: [abi6109priya@gmail.com](mailto:abi6109priya@gmail.com) (H. R. Priya).

presenting symptoms and signs, the role of comorbidities and medications used to treat COVID-19, and the outcomes of management in our tertiary care hospital.

The diagnosis of COVID-19 was based on reverse transcription polymerase chain reaction (RT-PCR) test on nasopharyngeal or oropharyngeal swabs, or computed tomography (CT) chest scores in the absence of a positive RT-PCR test in a clinically symptomatic case. A patient with symptoms and signs of ROCM, in the clinical setting of concurrent or recently treated COVID-19, was considered as possible ROCM.

## 2. Discussion

Gail et al<sup>6</sup> study concluded that mucormycosis occurs primarily among poorly controlled diabetics in developing countries with 30-50% mortality which correlates with our study with high mortality of 37.5% to 57.14%.<sup>7</sup>

In a multi centered study conducted by A Patel<sup>8,9</sup> among 465 patients, ROCM was the common form of mucormycosis and 73.5% were diabetics which is comparable to our study with 84% diabetics.<sup>7</sup>

Ge Song et al<sup>10</sup> study stated that fungal co infections are associated with global COVID-19 pandemic especially among immunocompromised which is in accordance with our study where mucormycosis is suspected more among the COVID-19 patients admitted in pandemic.

Sen et al<sup>11</sup> and Arjun et al<sup>12</sup> studies concluded that Diabetes mellitus was a common risk factor for all patients, most patients had requirement of supplemental oxygen and received corticosteroids as a part of COVID-19 treatment.

The findings of the analysis are as follows:

Data collected regarding patients age, covid status, diabetic status, h/o steroid and oxygen therapy, staging at presentation, radiological and clinical manifestation along with vaccination status among the 50 suspected Mucor cases were studied. Among them 42 were found to be diabetics (2 new onset DM – 1 post covid and 1 covid positive) and 8 were non diabetics with 70% being males.

**Table 1:**

Parameter	Mean ± SD	Median	Minimum	Maximum
Age	51.68 ± 11.17	53	30	80

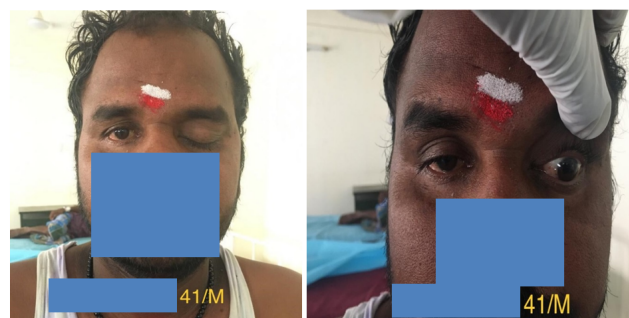**Table 2: Demographic details**

Age	Male	Female
30-40	8	1
41-50	6	6
51-60	17	5
>60	4	3
Total	35(70%)	15(30%)

Among 42(84%) diabetic patients, 14(33%) were covid positive, 12(28.5%) were post covid, 16(38.1%) were covid negative. Within 14 covid positive, 13(92.8%) had steroid treatment, 9(64.2%) had oxygen therapy, only 7.14% vaccinated while mortality was 57.14%. Of 71.4% microbiologically tested covid positive- only 20% KOH and 10% culture tested positive for Mucor. Only 14.2% underwent CT scan (could not be shifted as many were under oxygen therapy) and they had both sinus and orbital involvement. Clinically 28.5% had mild symptoms like lid edema or conjunctival chemosis, 71.4% had muscle involvement with restricted extra ocular movements or ophthalmoplegia, 50% had vision affected ranging from <2/60 to PL<sup>-</sup>, 42.8% patients were in Stage 3c at the time of presentation.

**Table 3: Clinical presentation**

Features	Covid Positive	Covid Negative	Post Covid
Mild Symptoms	28.50%	31.25%	25%
Muscle Involvement	71.40%	43.75%	25%
Only Ptosis	0%	0%	17%
Eschar	0%	25%	8.33%
Palatal Ulcer	0%	0%	16.66%
Normal Anterior Segment	0%	25%	25%



**Fig. 1:**

Within 16 covid negative patients, 6(37.5%) had steroid history, 6(37.5%) had oxygen therapy, none were vaccinated and mortality was 37.5%. Among the only 50% microbiologically tested patients - 62.5% KOH and 12.5% culture tested positive for Mucor. On CT/MRI-66.6% had sinus/orbital extension; Clinically-25% normal, 31.25% had mild symptoms, 43.75% had extra ocular muscle involvement; 6.25% had vision affected while 31.25% patients were in Stage 3a, 3b, 3c each at the time of presentation.

Among 12 post covid patients, 5(42.6%) had steroid history, 10(83.3%) had oxygen therapy, none were vaccinated and mortality was 8.33%; Among 83.33% microbiologically tested suspected cases, 70% KOH and

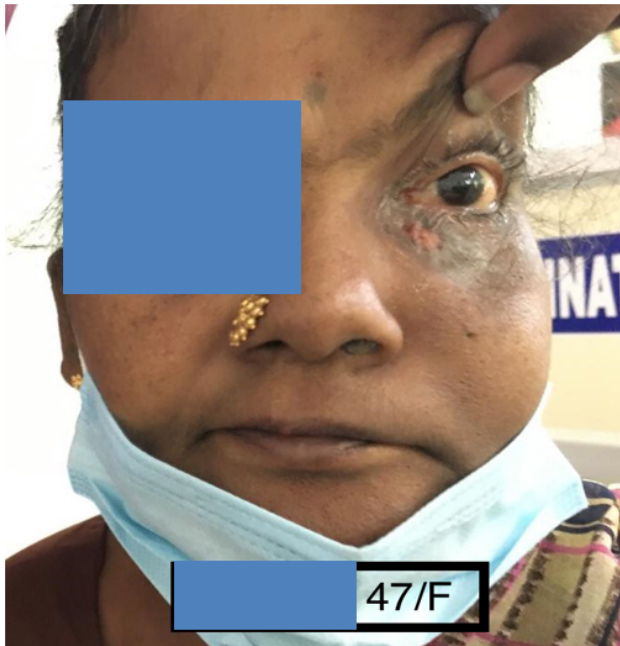

Fig. 2:

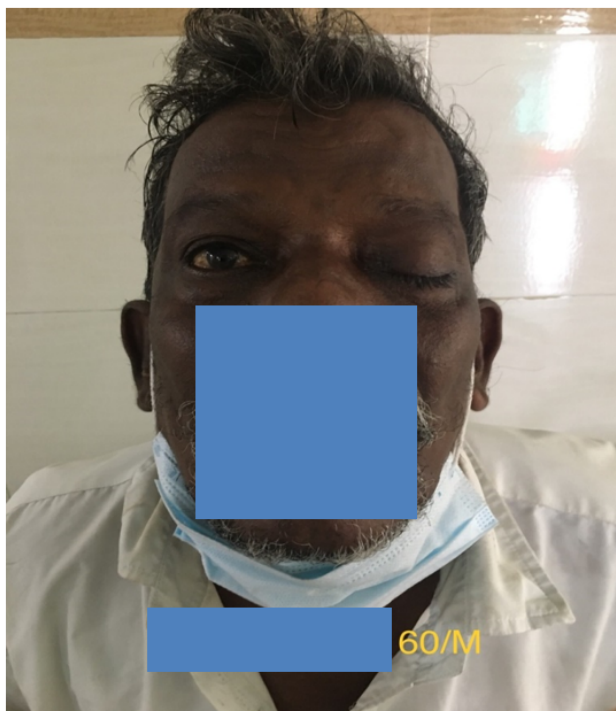

Fig. 3:

40% culture tested positive for fungal growth. 58.3% underwent functional endoscopic sinus surgery FESS of which 71.4% HPE samples were positive for fungus; of those who had taken CT/MRI- 50% had sinus involvement and 50% had orbital extension each; clinically 25% patients were normal, 25% had mild symptoms, only 25% had muscle involvement in the form of restricted extra ocular movements or ophthalmoplegia while 16.6% had palatal ulcer.

**Table 4:** Staging at presentation

Staging	Covid Positive	Covid Negative	Post Covid
1a	0%	6.25%	0%
2c	0%	0%	8.33%
2d	0%	0%	16.66%
3a	21.40%	31.25%	16.66%
3b	28.50%	31.25%	58.33%
3c	42.85%	31.25%	0%
3d	7.14%	0%	0%

Functional Endoscopic Sinus Surgery with debridement was done for all possible patients. Antifungal treatment with IV Amphotericin B/Posaconazole<sup>13</sup> was given under renal monitoring for only 23.8% because of variable availability of drug and 3 doses of Transcutaneous Retrobulbar Amphotericin B, TRAMB<sup>13</sup> was given for necessary patients under precautions. Proper glycemic control was attained with appropriate insulin dosage and Monitoring of sugars, and other supportive measures were given to all the patients.

Among the 8 non diabetics, 1(12.5%) was covid positive, 4(50%) were covid negative and 3(37.5%) were post covid. Covid positive patient had steroid history and presented in stage 3a while among covid negative none had oxygen or steroid history and each presented in stage 3a, 3b, 3c and 3d and among post covid 33.33% had steroid and oxygen history and 33.33% presented in stage 2c, 2b and 3a each.

### 3. Conclusion

The study reveals that Covid 19 has caused an alarming increase in opportunistic Mucormycosis infection among diabetic patients. The infection caused high morbidity and mortality among covid positive than post covid patients. It could be minimized by strict diabetic control with appropriate insulin dosage, wise use of steroids/oxygen and timely intervention based on clinical evaluation rather than waiting for investigations could minimize the complications from the infection and shorten the hospital stay.

### 4. Source of Funding

None.


## 5. Conflict of Interest

Nil.

## References

- Hibbett DS, Binder M, Bischoff JF, Blackwell M, Cannon PF, Eriksson OE, et al. A higher-level phylogenetic classification of the Fungi. *Mycol Res*. 2007;111(Pt 5):509–47.
- Prakash H, Chakrabarti A. Epidemiology of Mucormycosis in India. *Microorganisms*. 2021;9(3):523.
- Cucinotta D, Vanelli M. WHO Declares COVID-19 a Pandemic. *Acta Biomed*. 2020;91(1):157–60.
- Mishra Y, Prashar M, Sharma D, Akash, Kumar VP, Tilak T. Diabetes, COVID 19 and mucormycosis: Clinical spectrum and outcome in a tertiary care medical center in Western India. *Diabetes Metab Syndr*. 2021;15(4):102196.
- Sarda R, Swain S, Ray A, Wig N. COVID-19-associated mucormycosis: an epidemic within a pandemic. *QJM*. 2021;114(6):355–6.
- Reid G, Lynch JP, Fishbein MC, Clark NM. Mucormycosis. *Semin Respir Crit Care Med*. 2020;41(1):99–114.
- Prakash H, Ghosh AK, Rudramurthy SM, Singh P, Xess I, Savio J. A prospective multicenter study on mucormycosis in India: Epidemiology, diagnosis, and treatment. *Med Mycol*. 2019;57(4):395–402.
- Patel A, Kaur H, Xess I, Michael JS, Savio J, Rudramurthy S, et al. A multicentre observational study on the epidemiology, risk factors, management and outcomes of mucormycosis in India. *Clin Microbiol Infect*. 2020;26(7):944.
- Patel AK, Patel KK, Patel K, Gohel S, Chakrabarti A. Mucormycosis at a tertiary care centre in Gujarat, India. *Mycoses*. 2017;60(6):407–11.
- Song G, Liang, Liu W. Fungal Co infections associated with global Covid 19 pandemic. *Mycopathologia*. 2020;185(4):599–606.
- Sen M, Lahane S, Lahane TP, Parekh R, Honavar SG. Mucor in a Viral Land: A Tale of Two Pathogens. *Indian J Ophthalmol*. 2021;69(2):244–52.
- Arjun R, Felix V, Niyas VKM, Kumar MAS, Krishnan RB, Mohan V, et al. COVID-19-associated rhino-orbital mucormycosis: a single-centre experience of 10 cases. *QJM*. 2022;114(11):831–4.
- Kumar M, Sarma DK, Shubham S, Kumawat M, Verma V, Singh B, et al. Mucormycosis in COVID-19 pandemic: Risk factors and linkages. *Curr Res Microb Sci*. 2021;2:100057. doi:10.1016/j.crmicr.2021.100057.

## Author biography

**Hannah Ratna Priya**, Assistant Professor  <https://orcid.org/0000-0003-3004-3119>

**Sumathi Periasamy**, Professor

**Shanmugapriya Sekar**, Junior Resident

**Cite this article:** Priya HR, Periasamy S, Sekar S. A study on epidemiology, clinical profile, management, and outcome of Covid-19-associated rhino-orbital-cerebral mucormycosis in a tertiary hospital in Tamil Nadu. *Indian J Clin Exp Ophthalmol* 2023;9(2):261–264.