

C-Rhexis” the surgical grail in intumescent mature cataract

Sahil Bhandari^{1,*}, Manas Nath², Prasanth Gireesh³

¹Fellow, Dept. of Vitreo-retinal Services,
^{2,3}Consultant, Dept. of Cataract and Refractive Services,
 Aravind Eye Hospital, Pondicherry, India

***Corresponding Author**

E-mail: sahilstanlean@gmail.com

Abstract


Background: Capsulorhexis in intumescent mature cataract has high chance of peripheral extension. This paper aims at describing a modified “C- rhexis technique”, with the unique mechanism of “simultaneously acting unidirectional vector forces” for virtually eliminating the risk of peripheral extension.

Methods: Retrospective analyses of patients who were diagnosed to have intumescent mature cataract and underwent surgical intervention by a single surgeon using the modified “C-rhexis technique” were included.

Results: A total of 125 eyes were included. None of the eyes experienced any capsular tag or peripheral extension of rhexis.

Conclusion: In the nutshell, the “C-rhexis” virtually eliminates the risk of peripheral extension of capsulorhexis due to its unique “simultaneously acting unidirectional vector forces”. It can be easily mastered, creates an adequate size rhexis in first attempt, does not require expensive instruments and can be advocated in both MSICS and phacoemulsification.

Keywords: C-rhexis¹, Intumescent cataract², Rhexis extension³, Uni-directional vector⁴

Access this article online	
Quick Response Code:	Website: www.innovativepublication.com
	DOI: 10.5958/2395-1451.2016.00007.X

Materials and Methods

Surgical Technique: Informed consent was obtained from all the patients before proceeding for the intervention. The study was approved by Institutional Review Board and follows the tenets of the Declaration of Helsinki. The proposed “C-flap” technique can be performed in both manual small incision cataract surgery (MSICS) and Phacoemulsification (PE). Routine aseptic preparation of patient is followed and either sclerocorneal tunnel (MSICS) or clear corneal tunnel (PE) is fashioned. Trypan blue 0.06% (AUROBLUE, AUROLAB, India) is used to stain the anterior lens capsule (ALC). Dispersive viscoelastics are used to fill the anterior chamber (AC) after removal of trypan blue. A cystitome fashioned from 26 gauge needle is used through side port incision (PE) or primary tunnel (MSICS) to create a ‘C’ shaped opening (3mm by 1mm) in the ALC starting from the center (Fig. 1A, 2B, 3A) and anti-clockwise. Liquefied cortical fluid is aspirated by 25 gauge hydro dissection cannula through side port incision to decompress the lens (fig. 1B, 2C, 3B) and reduce the intralenticular pressure. AC is refilled with dispersive viscoelastic substance. Simultaneously, the capsular flap is flipped over and flattened. Capsulorhexis forceps or cystitome (fig. 1C, 2D, 3C) can be used to extend the base of the flap and rhexis is completed in regular curvilinear manner under the scaffold of viscoelastics. Rhexis expansion (double rhexis) can be performed in MSICS, if the rhexis appears to be small for the nucleus size. Rest of the steps are similar to any standard surgical maneuver.

Introduction

Continuous Curvilinear Capsulorhexis (CCC) is one of the crucial surgical step especially in intumescent mature cataract¹. Due to high intralenticular pressure² there are chances of radial extension with the first nick leading to Argentinean flag sign. In order to avoid it, several methods¹⁻⁸ have been devised. The main aim of these techniques have been to reduce intralenticular pressure,⁶ avoid fluctuation in anterior chamber,⁵ enhance visibility,⁷ decompress posterior lenticular pressure² and create two stage capsulorhexis.⁸

However, these techniques raise few questions pertaining to surgical complexity,⁵ surgical expertise⁸ and the need of expensive instruments like endoilluminator¹ in its performance. Looking at these limitations, we have devised a modified technique, which is both simpler and reduces the rate of complications.

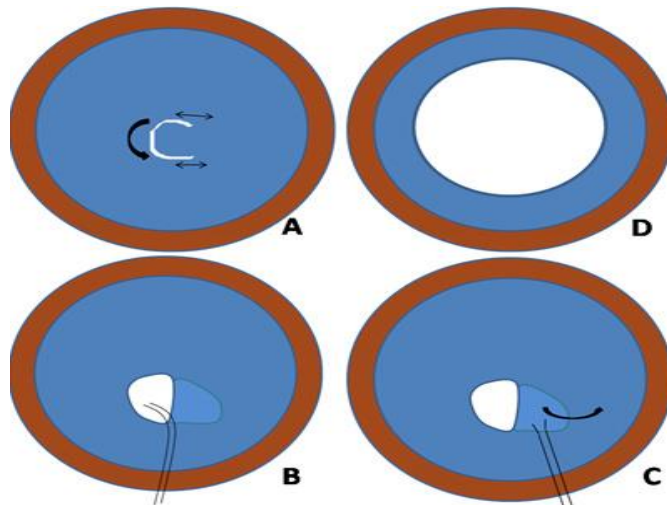


Fig. 1: Animatic representation (anticlockwise) of “C-rhexis technique”. (A) Creation of “C-incision” in the anterior capsule. (B) Decompressing the lens with hydrodissection cannula. (C) Continuing rhexis with forceps. (D) A well centered round rhexis in intumescent mature cataract

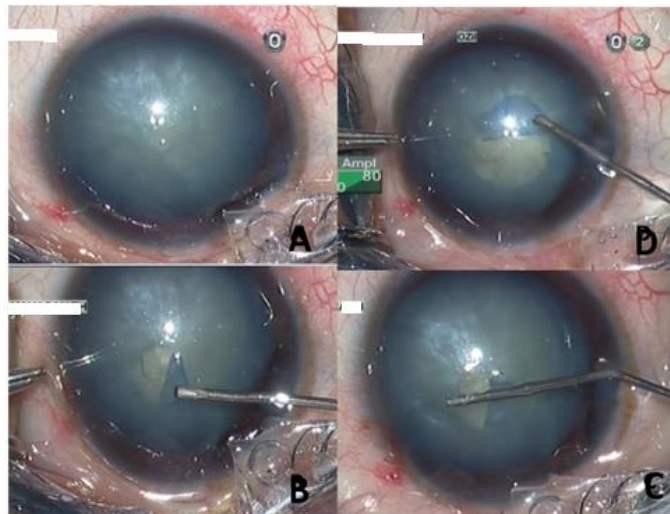


Fig. 2: Stepwise creation (A-D; anticlockwise) of “C-rhexis” technique in phacoemulsification from side port incision

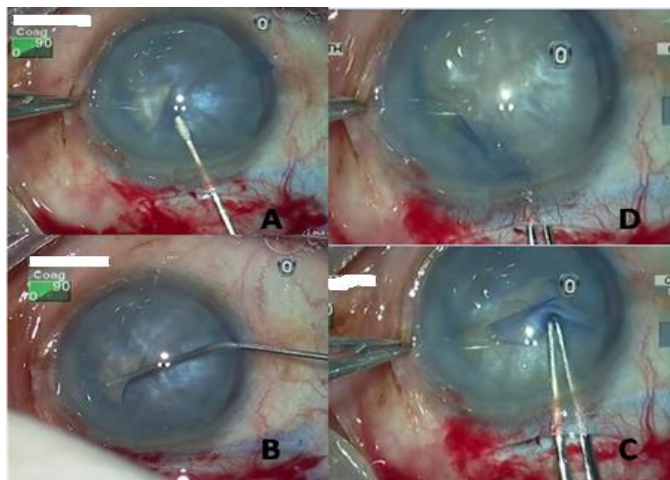


Fig. 3: Stepwise creation (A-D; anticlockwise) of “C-rhexis” technique in MSICS from main tunnel

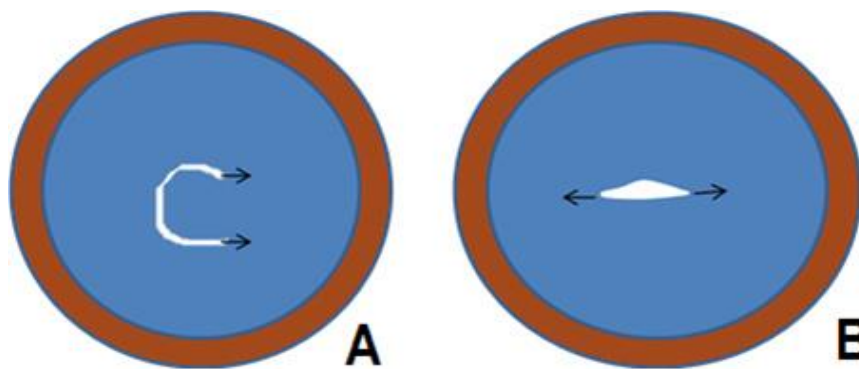


Fig4: Depicting the same direction vector forces in “C” – incision (A) in comparison to opposing vector forces in straight puncture (B)

Discussion

Figueiredo et al² gave new nomenclature to different types of white cataract and described the role of posterior intralenticular pressurized compartment in Argentinean flag sign. Different methods¹⁻⁸ of rhexis formation in fluid filled pearly white cataract was devised in order to combat the dreaded complication of peripheral extension. We have devised a modified “C-flap” technique to improvise the same.

In our technique main modification is the creation of a “C” shaped incision in ALC instead of a straight puncture. The benefit of “C” incision over a puncture is that the vector forces acting on the ends of C-flap are in the same direction (fig. 4A) instead of opposing forces in straight incision; this facilitates synergism to pull the edges of the nick to the periphery (fig. 4B). Secondly, the curvilinear part of “C” incision is equivalent to an arc of rhexis which provides sufficient resistance towards any peripheral extension. Lastly the “C” incision immediately provides a wider area for the pressurized anterior intralenticular chamber to decompress as compared to anterior capsule puncture. This helps in hastened equilibrium between the intralenticular and AC pressure.

Figueiredo et al² have described the Brazilian technique for prevention of Argentinean flag sign. Though the technique is effective, theoretically there still is a risk of peripheral extension during central puncture of ALC (fig. 4B). Also there may be mild fluctuation in AC while injecting viscoelastics through the main wound which could also increase the chances of peripheral extension. In case of “C” flap rhexis, we noticed that even if there is fluctuation of AC rhexis doesn't get extended as the acting vector forces are not in opposite directions, also, we experienced that in most of the cases, a rhexis created in the first attempt would be large enough to avoid the need of rhexis expansion.²

As compared to the technique described by Bhattacharjee et al,¹ our technique holds the advantage of single step rhexis. Also, there is no essential requirement for cohesive viscoelastic and we have been using dispersive viscoelastic like hydroxyl propyl methyl cellulose (HPMC) for AC maintenance. This is

in contrary to what has been discussed by Arshinoff et al.⁹ In their letter to editor Arshinoff et al⁹ have mentioned that raising the anterior chamber pressure by injecting high molecular weight viscoelastics, the anterior capsule curvature is altered from convex anteriorly to concave anteriorly, thus redirecting the rhexis extension force inwards, but as per our study results and the technique described, the equalization of intralenticular and anterior chamber pressure occurs immediately after the creation of “C” incision which neutralizes any chance of rhexis extension even in the presence of pressure variation. Thus a well-constructed “C-flap rhexis” negates the need of high molecular weight cohesive OVD which would otherwise be required to compensate for the intralenticular positive pressure.¹⁰

The difficulties associated are primarily concerned with the formation of an adequate “C” incision. Ideally the “C” incision should start at the center of capsule and the size should range approximately between 2mm by 1mm to 3mm by 1mm. With minimal experience of few cases this can easily be mastered. It could be argued upon that our technique involves a central puncture in the anterior capsule which could still increase the risk of peripheral extension. In this regard the author's would like to stress upon the need of immediate extension of central puncture into “C” incision which can completely avoid the above mentioned problem. In clinical practice we have noticed that even if there is an extension of the initial puncture, it never goes beyond 1 or 2mm due to the dynamics of “C” incision.

The size and position of “C” incision is important, because an eccentric and larger flap would otherwise increase the risk of peripheral extension due to peripheral proximity of one edge of flap. On the contrary a smaller flap would lead to smaller rhexis in the first attempt defying the whole purpose of single stage rhexis. Another significance of the size is that it aids in formation of an adequate diameter rhexis especially for MSICS cases.

Finally concluding, the “C-rhexis” virtually eliminates the risk of peripheral extension of capsulorhexis due to its unique “simultaneously acting

unidirectional vector forces". It can be easily mastered, creates an adequate size rhexis in first attempt, does not require expensive instruments and can be advocated in both MSICS and phacoemulsification.

Results

"C" flap rhexis technique was performed on a total of 125 eyes with intumescent white cataract by a single surgeon (M.N.) during April 2014 to December 2014. Out of these 125 eyes, MSICS was performed in 87 eyes and the remainder 38 eyes had phacoemulsification. In total 67 of the MSICS eyes and 30 of the Phacoemulsification eyes had a circular well centered rhexis; rest of the eyes had irregular but curvilinear rhexis. None of the eyes had any capsular tags. Intraoperative peripheral extension was neither experienced during creation of 'C' incision nor during the continuation of capsulorrhexis in both MSICS and phacoemulsification.

Of all MSICS eyes, double rhexis was done only in 6 eyes as the nucleus size was sufficiently larger than the capsulorrhexis opening. Neither of the eyes during phacoemulsification required a double rhexis. Postoperatively 105 eyes (84%) had uncorrected visual acuity of 20/40 or better.

Conflict of Interest: None

Source of Support: Nil

References

1. Bhattacharjee K, Bhattacharjee H, Goswami BJ, Sarma P. Capsulorrhexis in intumescent cataract. *J Cataract Refract Surg.* 1999;25:1045-7.
2. Figueiredo CG, Figueiredo J, Figueiredo GB. Brazilian technique for prevention of the Argentinean flag sign in white cataract. *J. Cataract Refract. Surg.* 2012;38:1531-6.
3. Lee JE, Choi HY, Oum BS, Lee JS. Capsulorrhexis assisted by slit illuminator for white cataract without a red reflex. *Ophthalmic Surg Lasers Imaging.* 2007;38:349-52.
4. Kara-Junior N, de Santhiago MR, Kawakami A, Carricondo P, Hida WT. Mini-rhexis for white intumescent cataracts. *Clinics (Sao Paulo).* 2009;64:309-12.
5. Chan DD, Ng AC, Leung CK, Tse RK. Continuous curvilinear capsulorrhexis in intumescent or hypermature cataract with liquefied cortex. *J. Cataract Refract. Surg.* 2003;29:431-4.
6. Rao SK, Padmanabhan P. Capsulorrhexis in white cataracts. *J. Cataract Refract. Surg.* 2000;26:477-8.
7. Fritz WL. Fluorescein blue, light-assisted capsulorrhexis for mature or hypermature cataract. *J. Cataract Refract. Surg.* 1998;24:19-20.
8. Gimbel H V, Willerscheidt AB. What to do with limited view: the intumescent cataract. *J. Cataract Refract. Surg.* 1993;19:657-61.
9. Arshinoff SA. Ophthalmic viscosurgical devices for intumescent cataracts: Pressure-equalized cataract surgery. *J Cataract Refract Surg.* 2015;41(7):1549-50.
10. Hengerer FH, Dick HB, Kohnen T, Conrad-Hengerer I. Assessment of intraoperative complications in intumescent cataract surgery using 2 ophthalmic viscosurgical devices and trypan blue staining. *J Cataract Refract Surg.* 2015;41(4):714-8.