



Case Report

Sebaceous gland carcinoma of right lower eyelid: A case report

Partha Pratim Roy^{1,*}, Tanveer Ahmed¹, Gautam Paul¹, Prasannajit Das¹

¹Dept. of Ophthalmology, Silchar Medical College and Hospital, Silchar, Assam, India



ARTICLE INFO

Article history:

Received 07-01-2020

Accepted 22-02-2020

Available online 16-06-2020

Keywords:

Lid mass

Lid reconstruction

Sebaceous cell carcinoma

Tenzel flap technique

ABSTRACT

A 50 year old lady presented to eye opd with a painless, nodular lid mass in right lower eye lid for 6 months with an aggressive growth for last 3 months. Physical examination revealed a solid mass of size about 30 mm x 30 mm x 20 mm. A complete excision of the mass with a 3mm clear margin was done along with lid reconstruction using Tenzel Flap technique. Biopsy and immunohistochemistry study revealed sebaceous cell carcinoma of right lower eye lid.

© 2020 Published by Innovative Publication. This is an open access article under the CC BY-NC license (<https://creativecommons.org/licenses/by-nc/4.0/>)

1. Introduction

Sebaceous cell carcinoma is a common yet aggressively malignant and potentially lethal tumor of the sebaceous glands present in the skin. Presence of sebaceous gland carcinoma in ocular adnexa is rare with an incidence of about 1-5.5% worldwide. The tumor may arise in the eyelid from its various modified sebaceous gland units like glands of Zeis, Meibomian glands in the tarsus, skin of lids and from caruncle even. Its occurrence is usually more in the upper lid probably because of the presence of higher number of sebaceous glands on upper lid. It has got a higher prevalence in female sex, Asian population and in the 5th to 7th decade of life and patients previously treated with radio therapy. Involvement of the adnexa and regional involvement of lymph nodes are initial phases of spreading of the cancer. In a few cases metastasis has also been reported. Wide local excision with lid reconstruction (wherever applicable) and proper follow up has shown good results in the management of it.

2. Case Report

A 50-year-old lady presented to the eye opd with a painless, nodular mass of right lower lid that has started 6 months back. The mass has started growing aggressively for the last 3 months and it has become so bulky for the last 1 month that it is affecting her eye closure and ocular motility. There is no history of active bleeding or any discharge from the mass.

Physical examination revealed a solitary mass in the middle third of lower eyelid overhanging the lid margin and is of size 30mmx30mmx20mm. The mass was underlying the right lower lid skin extending beyond the lash line without invading the palpebral conjunctiva. It was firm to hard in consistency, tender on touch, did not appear to extend to deeper tissues and did not bleed on touch. There was no regional lymphadenopathy. The ocular examination was found to be normal except a few age related changes.

Systemic examinations were within normal limits. Routine pre-op investigations were done. Malignancy was suspected on clinical basis. Patient was planned for excision biopsy with lid reconstruction.

A complete, wide excision of the nodular mass with a 3 mm clear margin was performed using Tenzel flap method. The mass was sent for histopathological and

* Corresponding author.

E-mail address: royparthapratim1984@yahoo.com (P. P. Roy).

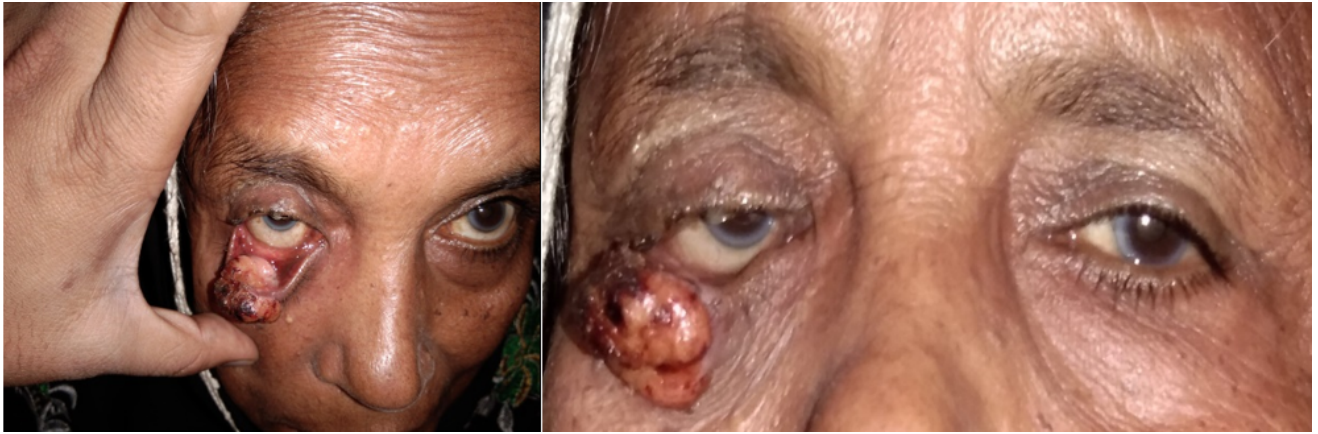

Fig. 1: Gross examination of the mass

immunohistochemistry study.

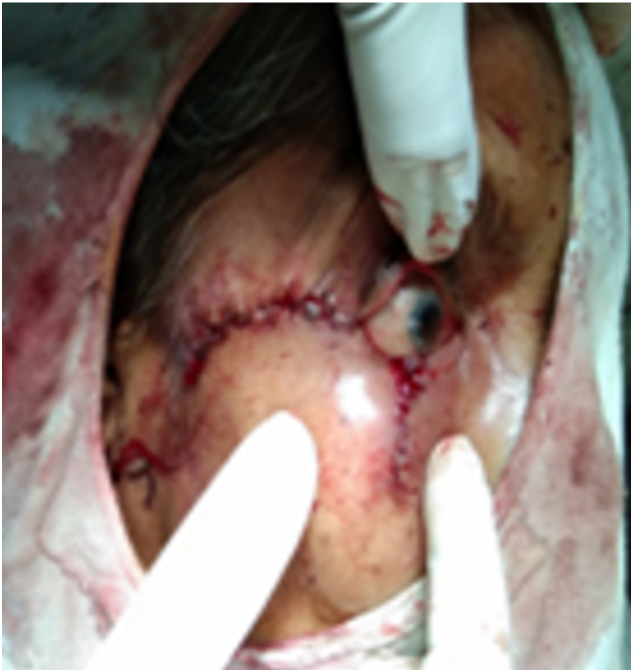

Fig. 2: Lid reconstruction was done by Tansel flap technique

Follow up on 1st, 7th, 30th day and 6 month revealed no complication or recurrence. Biopsy revealed presence of large hyperchromatic neoplastic cells with vacuolated basophilic cytoplasm.¹ The IHC report came positive for cytokeratin 7 and negative for cytokeratin20, CD10 and Vimentin. There is 3%-5% of KI67 positivity indicating its invasiveness. The final diagnosis came out to be sebaceous gland carcinoma of eyelid.

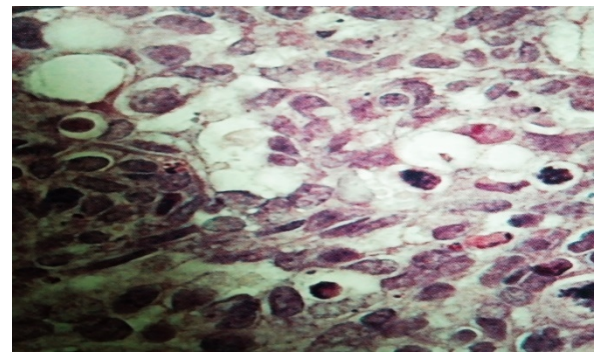


Fig. 3: Microphotograph (H and E X100) of moderately differentiated MGC showing lobules of malignant cells with sebaceous differentiation / intra-cytoplasmic lipid

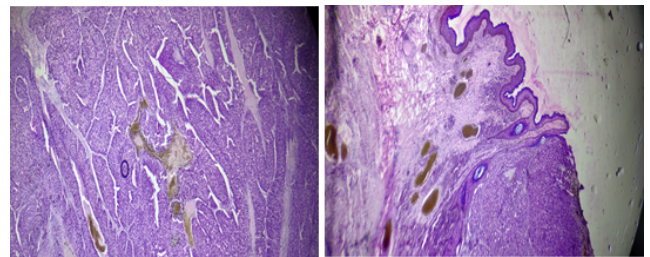


Fig. 4: Immunohistochemistry revealing focal positivity for cytokeratin, moderate (3-5%) positivity for KI67 and negativity for CD10, Vimentin, S-100 and CK5/6 confirming it to be sebaceous cell carcinoma

3. Discussion

Sebaceous gland carcinoma is a relatively common yet aggressive malignant carcinoma in country like India. It is more common in head and neck region and commonest to occur in eyelids in India. The incidence of sebaceous gland carcinoma varies from 0.5-5% in the USA and upto 28% in China^{2,3} Late middle age, Asian ethnicity,

radiation exposure in the form of occupational hazard or even following radiotherapy as a complication. The condition is found to be more common in females. Upper eyelid is affected more than the lower eyelid⁴ Differential diagnosis includes squamous cell carcinoma, basal cell carcinoma dermolipoma, hydradenoma, chalazion etc. Regional metastasis can occur in about 20%-30% of cases while systemic metastasis is also reported in a few cases. The treatment may vary from wide local excision to orbital exenteration. Radiotherapy is reserved for cases which are not suitable for surgical interventions.⁵

In our case there is sebaceous gland carcinoma in a 50 year old female in the right lower eyelid without any regional or distant metastasis. The patient showed good response to wide local excision with lid reconstruction by Tanzel flap method and there is no recurrence seen on regular follow up.

4. Declaration of Patient Consent

The authors certify that they have obtained all appropriate patient consent forms. In the consent form the patient has given her consent for her images and other clinical informations to be reported in the journal. The patient understands that her name and initials will not be published and due efforts will be made to conceal their identity, but anonymity cannot be guaranteed.

5. Source of Funding

None.

6. Conflicts of Interest

None.

References

1. Zurcher M, Hintschich CR, Garner A, Bunce C, Collin JRO. Sebaceous carcinoma of the eyelid: A clinicopathological study. *Br J Ophthalmol.* 1998;82(9):1049–55.
2. Ni C, Kou PK. Meibomian gland carcinoma: A clinico-pathological study of 156 cases with long-period follow up of 100 cases. *Jpn J Ophthalmol.* 1979;23:388–401.
3. Khalil MK, Lorenzetti HD. Sebaceous gland carcinoma of the lid. *Can J Ophthalmol.* 1980;15:117–21.
4. Rao NA, Hidayat AA, McLean IW, Zimmerman LE. Sebaceous carcinomas of the ocular adnexa: A clinicopathologic study of 104 cases, with five-year follow-up data. *Human Pathol.* 1982;13(2):113–22.
5. Shields JA, Demirci H, Marr BP, Eagle RC, Jr, Shields CL. Sebaceous carcinoma of the eyelids: Personal experience with 60 cases. *Ophthalmol.* 2004;111:2151–7.

Author biography

Partha Pratim Roy Registrar

Tanveer Ahmed Post Graduate Trainee

Gautam Paul Associate Professor

Prasannajit Das Assistant Professor

Cite this article: Roy PP, Ahmed T, Paul G, Das P. Sebaceous gland carcinoma of right lower eyelid: A case report. *Indian J Clin Exp Ophthalmol* 2020;6(2):305-307.