



Case Report

Ocular cysticercosis in north India- A case series

Deepti Joshi^{1,*}, Reena Sharma¹, Shanti Pandey²

¹Dept. of Ophthalmology, Uttar Pradesh Medical University of Medical Sciences, Saifai, Uttar Pradesh, India

²Dept. of Ophthalmology, Government Medical College, Haldwani, Uttarakhand, India



ARTICLE INFO

Article history:

Received 17-11-2019

Accepted 25-02-2020

Available online 16-06-2020

Keywords:

Albendazole

Ocular cysticercosis

Orbital cysticercosis

Scolex

T.solium

ABSTRACT

Ocular cysticercosis is a parasitic infestation in human eye caused by encystment of parasite, *Taenia solium* in tissues. We present a 3cases of ocular cysticercosis in a young child managed surgically. We discussed our findings in context to cases described by other researchers.

© 2020 Published by Innovative Publication. This is an open access article under the CC BY-NC license (<https://creativecommons.org/licenses/by-nc/4.0/>)

1. Introduction

Cysticercosis is a parasitic infection caused by the larval form of the cestode of *Taenia solium* (*T. solium*), also known as a pork tapeworm.¹ The most common systemic involvement is neurocysticercosis.² Ocular and adnexal cysticercosis (OCC) represents 13% to 46% of systemic disease.³ OCC is preventable cause of blindness⁴ OCC manifests in many ways depending on the location of the cysts.

Initial medical treatment of Intraocular cysticercosis with antihelminthic drugs like albendazole or praziquantel is useful. Consequently surgical removal of the parasite is the treatment of choice.⁵⁻⁷

We hereby present three interesting cases of OCC and a review of literature.

2. Case 1

An eight-year boy presented with diminution of vision, painless swelling right eye since 15 days. His best corrected

visual acuity right eye (OD) 6/12 and left eye (OS) was 6/6. Clinical examination right eye revealed axial proptosis with abduction deficit. Right eye pupil shows relative afferent pupillary defect and disc edema. MRI shows cystic lesion near orbital apex and right parieto occipital lobe lesion with scolex (Figure 1).

Child was diagnosed with ocular cysticercosis, and he was treated with oral steroid 1.5 mg per kg body weight 3 days followed by tablet albendazole 15 mg per kg body weight started 3 days later for 28 days. At his follow up visit there was reduction in proptosis and disc edema resolved and extraocular movement also improved (Figure 2).

3. Case 2

A twelve-year-old child presented with whitish lesion in left eye since 2 months. His BCVA 6/18 OD and 6/6 OS. Clinical examination left eye revealed an inferior subconjunctival cyst rest posterior segment examination was within normal limits. Patient was admitted for surgical excision but there was spontaneous extrusion of cyst same evening. CT scan shows involvement of left temporal lobe and histopathology report suggestive of scolex with

* Corresponding author.

E-mail address: deeptijoshi10@gmail.com (D. Joshi).

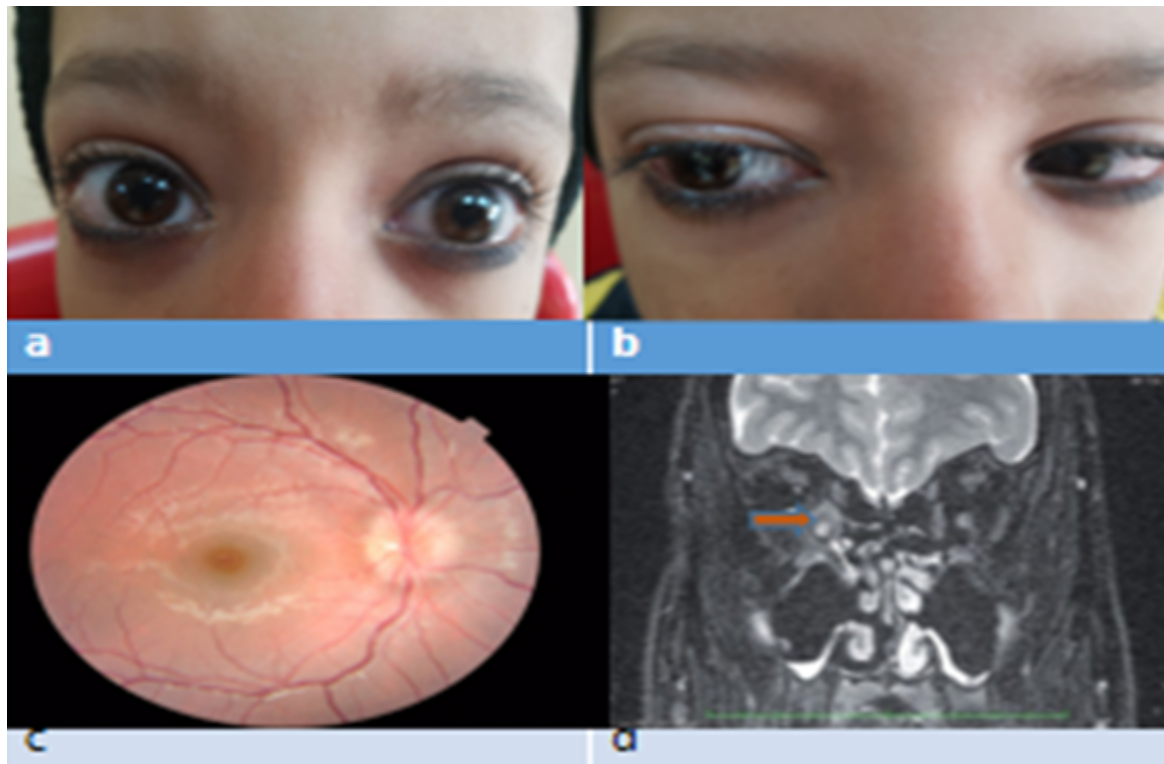


Fig. 1: (a): Proptosis right eye; (b): Abduction deficit right eye; (c): Color fundus photograph showing disc edema; (d): MRI showing medial rectus cystic lesion with scolex

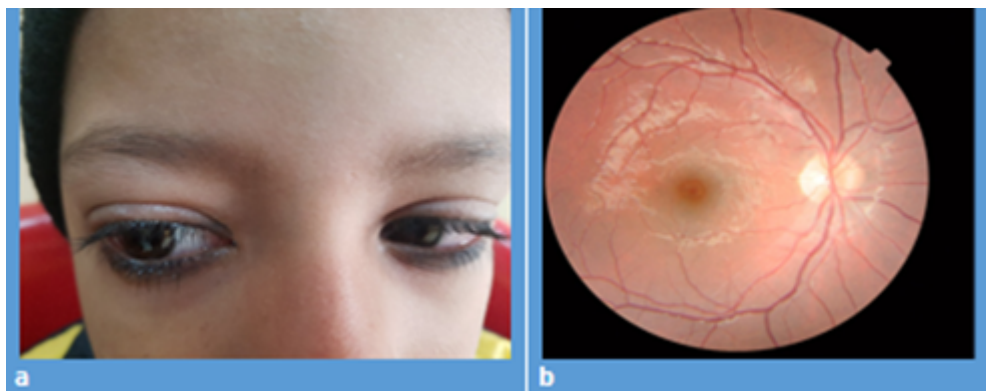


Fig. 2: (a): Post treatment photograph showing improved abduction in right eye; (b): Color fundus photograph showing disc with regular margins

hooklets. Oral steroids 1.5 mg per kg body weight were started in followed by tablet albendazole 15mg per kg body weight for 28 days (Figure 3).

4. Case 3

A 42 year alcoholic male with whitish floating mass in left eye and blurred vision. His BCVA 6/18 OS and 6/6 OD. Clinical examination left eye shows anterior chamber cyst with scolex and icterus in both the eye, rest examination with in normal limits. Liver function tests were borderline.

CT scan revealed tiny calcified lesion in parietal and frontal lobe, USG abdomen shows simple cyst with hepatomegaly. Surgery Visco expression of cyst left eye was done. Steroid was started with 1.5 mg per kg body weight, followed by tablet albendazole 400 mg twice daily for 28 days. Histopathology report of aqueous sample suggestive of larval stage of taenia solium. Post op day 7 vision was 6/6 (Figure 4).

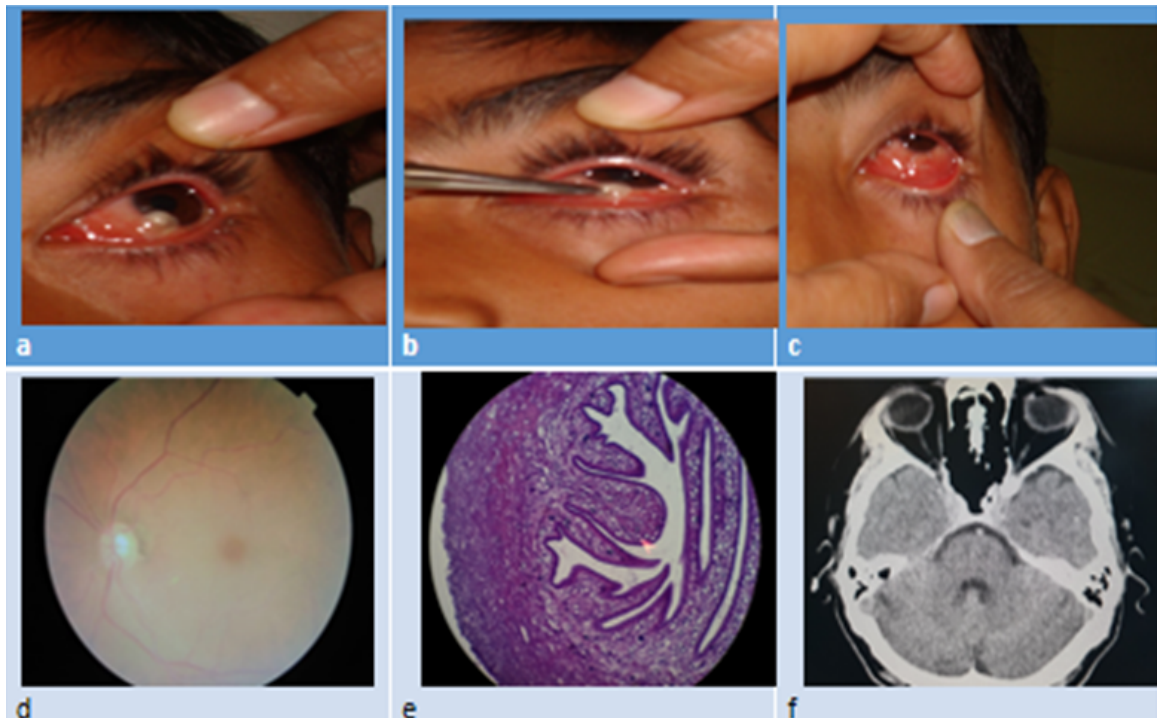


Fig. 3: (a): Photograph showing subconjunctival cyst left eye; (b): Spontaneous extrusion of subconjunctival cyst; (c): Eye after cyst extrusion (d): Color fundus photograph of left eye; (e): Histopathology showing taenia solium scolex with hooklets indicating larval stage; (f): CT showing calcified lesion in left temporal lobe

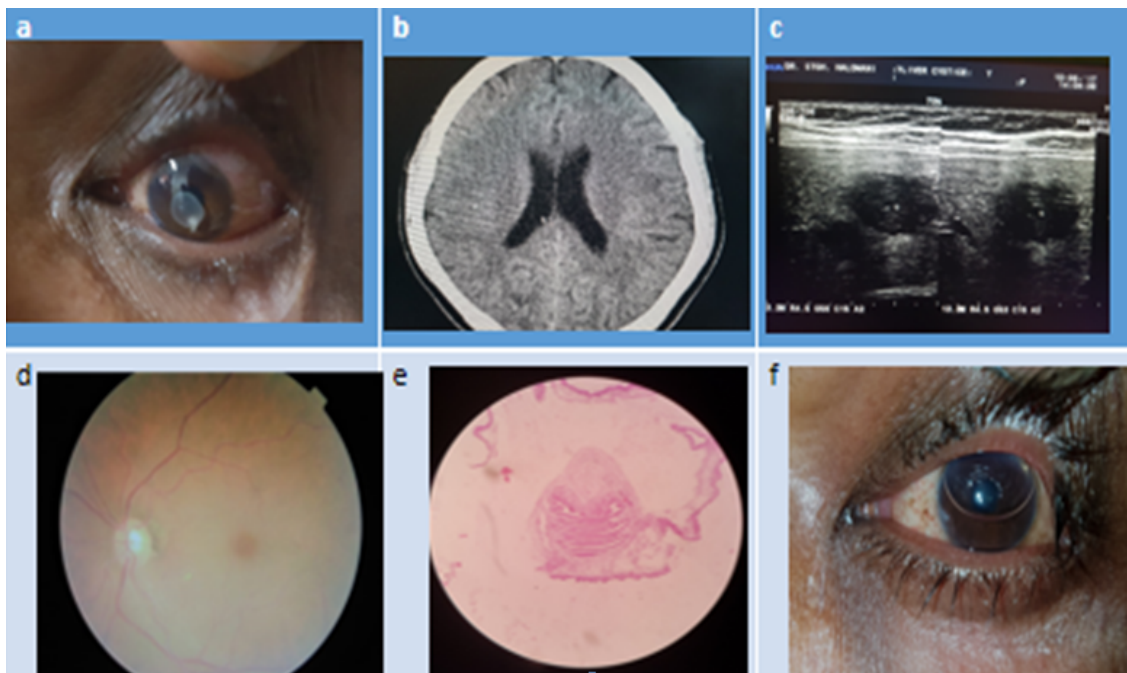


Fig. 4: (a): Left eye with cyst in anterior chamber; (b): Calcified lesions in parietal lobe; (c): USG abdomen showing simple liver cyst; (d): Fundus photograph of left eye showing normal fundus; (e): Histopathology showing taenia solium scolex with hooklets indicating larval stage; (f): Eye after viscoexpression of cyst

5. Discussion

Cysticercosis of extraocular muscle usually presents as recurrent pain, redness, proptosis, ocular motility restriction, diplopia and ptosis.^{8,9} In some cases optic nerve compression by the cyst may cause decreased vision, disc edema and painful ocular motility.¹⁰ Enlarging cyst may lead to axial proptosis, restricted ocular motility or simply may present as atypical optic neuritis.¹¹ Two different studies on myocysticercosis reveal inferior rectus (Sekhar & Honavar 1999) and medial rectus (Puri & Grover 1998), respectively, as the commonest muscle to get affected.

The problem is common in children because of their unhygienic habits. In our first case child presented with diminution of vision along with axial proptosis with abduction restriction in right eye due to involvement of medial rectus and optic nerve. Similarly Neelam Pushkar et al¹² reported involvement of medial rectus with atypical optic neuritis in 2001. This report is interesting because involvement of medial rectus is less common and involvement of medial rectus along with optic nerve is rarer. NCC and *ooc* are endemic in areas of poor sanitation, such as Southeast Asia, the Indian subcontinent, Latin America, and Africa. In India, 78% of the cases with ocular cysticercosis have been reported from states of Andhra Pradesh and Pondicherry.⁵

In our second case adolescent boy presented with inferior subconjunctival cyst.

RK Bansal et al.¹³ reported spontaneous extrusion of cyst in three adolescent cases. Similarly Karan Bhatia et al.¹⁴ also reported extrusion of cyst in adolescent boy.

Conjunctival involvement is usually in the form of a painless or painful yellowish, nodular subconjunctival mass with surrounding conjunctival congestion. Rarely subconjunctival abscess or granuloma may occur. Subconjunctival presentation could be due to spontaneous extrusion of cyst from extraocular muscle into the subconjunctival space. Because of its constant motility it may erode through the conjunctiva and comes out leaving a rent in the conjunctiva which heals in a short period.¹⁵ In a series on ocular cysticercosis from India, 60% patients had subconjunctival Cysticerci.¹⁶ In another case series from India, the cyst was in the anterior orbit in 69% of cases, subconjunctival space in 24.6%, posterior orbit in 5.8%, and the eyelid in 0.6% of cases.¹⁷ The posterior segment is more affected in western countries, whereas in India the cysts are more often subconjunctival.¹⁸

Our third case young male presented with a free floating live cyst in anterior chamber of left eye. The cysts enter the eye via posterior ciliary arteries while the route to anterior chamber is still debatable. SP Singh et al.¹⁹ also reported live cyst in anterior chamber. Surgical removal of parasite is treatment of choice.⁹ We also removed cyst surgically by viscoexpression. Cyst if ruptured can cause intense inflammatory reaction leading to plastic iridocyclitis²⁰ so

careful removal of cyst is necessary. Very few anterior chamber cyst cases has been reported yet.

Ocular involvement is usually unilateral but bilateral involvement may occur in cases of disseminated cysticercosis. Left eye is more commonly involved in comparison to the right, possibly because larva may be preferentially routed to the left internal carotid artery which directly originates from the aorta; Serial B-scan ocular ultrasonography or CT scanning of the orbit helps to follow the resolution of the cyst, by the disappearance of the scolex. Medical therapy with albendazole and oral steroid is recommended for the extra ocular muscle form and retro orbital cysticercosis, in these cases dramatic improvements have been reported.²¹

It is important to have CT scan of the head done to rule out cysts in the brain before starting cysticidal drugs. In patients with associated cysticercosis of the brain, the patient should be hospitalized and the cysticidal drug administration should be under neurological supervision as these agents provoke.

6. Source of Funding

None.

7. Source of Funding

None.

References

- Center for Disease Control. Neglected Parasitic infections in the United States: Neurocysticercosis. CDC Division of Parasitic Diseases and Malaria.
- Grover AK, Puri P. Orbital myocysticercosis presenting as subconjunctival abscess. *Ind J Ophthalmol.* 1996;44(4):229–31.
- Mais FA. Cryosurgery in ocular cysticercosis. *Rev Bras Ophthalmol.* 1969;28(2):99–106.
- Dhiman R, Devi S, Duraipandi K. Cysticercosis of the eye. *Int J Ophthalmol.* 2017;10(8):1319–24.
- Santos R, Chavarria M, Aguirre AE. Failure of medical treatment in two cases of intraocular cysticercosis. *Am J Ophthalmol.* 1984;97(2):249–50.
- Sharma T, Sinha S, Shah N. Intraocular cysticercosis: clinical characteristic and visual outcome after vitreoretinal surgery. *Ophthalmol.* 2003;110:996–1004.
- Gemolotto G, Pandey PK, Chaudhuri Z, Sharma P, Bhomaj S. A contribution to surgical treatment of intraocular cysticercosis. *J Pediatr Ophthalmol Strabismus.* 1955;59(5):273–8.
- Sekhar GC, Lemke BN. Orbital cysticercosis. *Ophthalmol.* 1997;104(10):1599–1604.
- Goyal JL, Das S, Kumar S, Chauhan D, Baheti U, Sangit V. Retrobulbar cysticercosis masquerading as optic nerve glioma. *Orbit.* 2007;26(1):61–3.
- Bawa YS, Wahi PL. Cysticercosis cellulosa of the optic disc with generalized cysticercosis. *Br J Ophthalmol.* 1962;46(12):753–5.
- Pushker N, Bajaj MS, Chandra M, Neena. Ocular and orbital cysticercosis. *Acta Ophthalmol Scand.* 2001;79(4):408–13.
- Bansal RK, Gupta A, Grewal SP, Mohan K. Spontaneous extrusion of cysticercosis: report of three cases. *Ind J Ophthalmol.* 1992;40(2):59–60.
- Bhatia K, Sengupta S, Sharma S. Spontaneous extrusion of subconjunctival cysticercosis cyst. *JAMA Ophthalmol.* 2016;134(4):e155025.

14. Topilow HW, Yimoyines DJ, Freeman HM, Young GAM, Addison R. Bilateral multifocal intraocular cysticercosis. *Ophthalmol.* 1981;88(11):1166–72.
15. Reddy PS, Satyendran OM. Ocular cysticercosis. *Am J Ophthalmol.* 1964;57(4):664–6.
16. Rath S, Honavar SG, Naik M, Anand R, Agarwal B, Krishnaiah S, et al. Orbital cysticercosis: clinical manifestations, diagnosis, management, and outcome. *Ophthalmol.* 2010;117(3):600–5.
17. Ryan SJ. Ocular cysticercosis. In: *Retina*. vol. 2. St. Louis: CV Mosby; 1989. p. 583–8.
18. Singh SP, Rana J, Dukre J, Singh PA. Extracting a large live freely floating cysticercosis cyst from the anterior chamber of the eye using visco expression technique: A case report. *Saudi J Ophthalmol.* 2016;30(1):56–9.
19. Mathur RN, Abraham L. Cysticercosis of the eye: a case of a plastic iridocyclitis due to cysticercus cyst in the anterior chamber. *Arch Ophthalmol.* 1962;67:562–563.
20. Sundaram PM, Jayakumar N, Noronha V. Extraocular muscle cysticercosis - A clinical challenge to the ophthalmologists. *Orbit.* 2004;23(4):255–62.
21. Raina UK, Taneja S, Lamba PA, Bansal RL. Spontaneous Extrusion of Extraocular Cysticercus Cysts. *Am J Ophthalmol.* 1996;121(4):438–41.

Author biography

Deepti Joshi Senior Resident

Reena Sharma Assistant Professor

Shanti Pandey Associate Professor

Cite this article: Joshi D, Sharma R, Pandey S. Ocular cysticercosis in north India- A case series. *Indian J Clin Exp Ophthalmol* 2020;6(2):300-304.