



Original Research Article

Comparison between fibrin glue and polyglactin sutures in limbal based conjunctival autograft technique in primary pterygium surgery in adults- A randomised controlled trial

Piyali Sarkar¹, Kumaresh Chandra Sarkar^{1,*}, Sujit Mondal², Rabindra Nath Saha²

¹Dept. of Ophthalmology, Calcutta National Medical College, Kolkata, West Bengal, India

²North Bengal Medical College, Darjeeling, West Bengal, India



ARTICLE INFO

Article history:

Received 30-11-2019

Accepted 17-12-2019

Available online 17-03-2020

Keywords:

Conjunctivo-limbal autograft

Fibrin glue

Progressive pterygium

ABSTRACT

Introduction: Pterygium is a slow growing, wing shaped, elastoticsubconjunctival degeneration within the palpebral fissure involving the cornea. As it encroaches the limbus, it proliferates as vascularised granulation tissue destroying the superficial stroma and Bowman's membrane and is characterized by tissue remodelling, cellular proliferation, neovascularisation and inflammation.

Objective: To compare between fibrin glue and polyglactin sutures in limbal based conjunctival autograft technique in primary pterygium surgery in terms of duration of surgery and early and late post-operative complications.

Materials and Methods: It was a prospective comparative, randomized controlled trial which was conducted at North Bengal Medical College, Darjeeling, from July 2016 to June 2017. Patients with progressive pterygium diagnosed after proper clinical examinations and admitted for excision with conjunctival autograft attached with fibrin glue or for excision with conjunctival autograft sutured with 8-0 polyglactin. Data were collected and analysed.

Results: 52 patients were randomly and equally divided into two groups, group A (fibrin glue) and group B (sutured with polyglactin) according to the type of surgery. In both the groups, there was female preponderance and the average age of the patients were 45.15 (± 5.576) and 40.65 (± 8.299) years respectively. Regarding the post-operative complications such as graft oedema ($p = 0.002$, $\chi^2 = 10.035$, $df = 1$), graft granuloma ($p = 0.037$, $\chi^2 = 4.333$, $df = 1$) and recurrence ($p = 0.638$, $\chi^2 = 0.221$, $df = 1$), the group A had less incidence than group B. The reduction of complications was statistically significant in group A in terms of graft oedema and graft granuloma but not in recurrence.

© 2020 Published by Innovative Publication. This is an open access article under the CC BY-NC-ND license (<https://creativecommons.org/licenses/by/4.0/>)

1. Introduction

Pterygium, derived from Pterygion (ancient Greek word means wing)^{1,2} is a slow growing wing shaped elastotic degeneration of sub-epithelial bulbar conjunctival tissues encroaching over the limbus which proliferate as vascularised granulation tissue which invades the cornea destroying the superficial stroma and Bowman's membrane and characterized by tissue remodelling, cellular proliferation, neovascularisation and inflammation within

the palpebral fissure.^{3–5} It commonly affects the nasal than temporal limbus of one or both eyes.³

Pterygium is more common in warm and dry climates though it is prevalent worldwide.^{6,7} It is more common in males (2:1) but in case of outdoor workers, males and females are equally affected. Clinically, pterygium has got following parts:⁸ head: the part invading the cornea from limbus (apex of the pterygium, highly vascular), neck: the narrowest part at the limbus, body: the widest portion found on bulbar conjunctiva and grey cap (small opacities on the cornea in front of the head in progressive pterygium). Sometimes, it has a pigmented (brownish) epithelial iron

* Corresponding author.

E-mail address: drkumareschs@gmail.com (K. C. Sarkar).

line adjacent to the pterygium is known as Stocker's line.

It may be categorized as- early pterygium: very small fleshy pterygium with little encroachment on cornea. Progressive pterygium: thick, fleshy with marked vascularity and increasing in size and encroaches towards the centre of the cornea. Usually opaque infiltrative spot known as cap is present. Atrophic pterygium: thin attenuated with poor vascularity with no cap is seen. Recurrent pterygium: seen with more scarring and with more width usually after surgical treatment of primary pterygium.

According to the length of encroachment onto the cornea, pterygium may be classified into the following stages:

1. Stage 0: The pterygium is restricted to posterior to the limbus,
2. Stage I: The pterygium is restricted to the limbus,
3. Stage II: The pterygium only marginally invades the cornea,
4. Stage III: The pterygium is between the limbus and papillary margin,
5. Stage IV: The pterygium is from the papillary margin and beyond.

The etiopathogenesis may be the degenerative process or chronic inflammation of the conjunctiva due to irritation from the elements like wind, dust and sun. Other factors may be hereditary and outdoor activities.^{3,4} Ultra-violet radiation mediated inflammation^{5,9} may lead to ocular surface damage and tear film instability, ultimately resulting in epithelial cell loss, a reduction in mucus secretion and tear hyperosmolarity, leading to pterygium formation. Limbal stem cell (LSC) has got important role to prevent conjunctival overgrowth on the cornea. Their deficiency at the limbus allows conjunctivalization of corneal epithelium along with fibrovascular overgrowth.

Surgery is the treatment of choice for pterygium management. The main challenge to successful surgical treatment of pterygium is recurrence. Many surgical techniques have been used, though none is universally accepted because of variable recurrence rates. Regardless of the technique used, excision of the pterygium is the first step of treatment. Previously excision of pterygium with bare sclera (80% recurrence rate) was the mode of operation. Commonly advocated procedures are excision of pterygium with amniotic membrane transplantation with or without application of mitomycin C, bare sclera with mitomycin C, beta irradiation, combined rotational autograft with intra-operative mitomycin C and limbal based conjunctival autograft. Compared to other techniques limbal based conjunctival autografting is the most popular approach¹⁰ having very low recurrence rate and complications. Nevertheless, graft suturing has disadvantages of longer surgery time and complications like suture granuloma formation, giant papillary conjunctivitis and significant

patient discomfort and rarely stitch infection.¹¹

Nowadays, fibrin-based glue for conjunctival autografting is becoming popular to minimize operating time and discomfort associated with sutures. Fibrin based adhesives are having biological and biodegradable properties may be used under the superficial covering layers such as conjunctiva or amniotic membrane without inducing inflammation.^{10,12} It is well tolerated, non-toxic to tissues and has some antimicrobial activity. The smooth seal along the entire length of the wound edge results in higher tensile strength, with low incidence of allergic reaction. It reduces the total surgical time and it has been found to lower the risk of post-operative wound complications, contrary to the conventional suturing.

2. Aims and Objectives

To compare the duration of surgery, early and late post-operative complications such as graft oedema and granuloma as well as recurrence between fibrin glue and polyglactin sutures in limbal based conjunctival autograft technique in primary pterygium.

3. Materials and Methods

3.1. Study type and design

The study was a prospective, comparative, randomized controlled trial.

3.2. Place of study

Department of Ophthalmology, North Bengal Medical College and Hospital, Darjeeling.

3.3. Study period

Twelve months (July 2016 to June 2017) .

3.4. Case definition

Primary progressive pterygium involving at least 2 mm from limbus between 20 –50 years.

3.5. Study population

Patients with primary progressive pterygium attending OPD, department of Ophthalmology, North Bengal Medical College and Hospital, Darjeeling.

3.6. Inclusion criteria

- a). Unilateral or bilateral primary progressive pterygium in patients of 20 -50 years.
- b). Unilateral or bilateral primary progressive pterygium with corneal involvement.

3.7. Exclusion criteria

If the patient had very early pterygium (<2mm), recurrent pterygium, active ocular infection, acute or chronic dacryocystitis, previously diagnosed Diabetes Mellitus, bleeding disorders, pregnancy and patients unwilling to be included into the study were excluded.

3.8. Study variable

These were graft oedema (central corneal thickness > 1mm), conjunctival granuloma formation, recurrence (fibrovascular conjunctiva tissue > 1 mm into the cornea) and duration of the surgery.

3.9. Sample size

As per inclusion and exclusion criteria 52 patients who attended eye OPD were included in this study.

3.10. Sampling design

52 patients were randomly allocated into two groups. Appropriate computer-generated randomization technique had been implemented into these groups. Two groups were equally divided into Group A and group B which were excision of pterygium with conjunctivo-limbal autograft attached with fibrin glue and suture with 8-0 polyglactin respectively. All the patients were pre-operatively properly examined and investigated for surgical intervention which had been performed by same surgeon. The surgical time was noted from the first incision until lid speculum was removed. The total duration of the surgery was noted in every case. After operation eyes were patched with local steroid-antibiotic ointment for 24 hours and post-operatively, the patients were treated with eye drops Moxifloxacin hydrochloride 0.5% and Dexamethasone 0.1% six times a day with gradual tapering over one month. Artificial tear substitute (0.5% carboxy methyl cellulose) four times a day for one month was used. After 1st day post-operative follow-up, every patient was scheduled for follow up examination as follows: 1st week, 3rd week, 6th week and then, every month up to 6th month. In each follow up, patients were thoroughly examined under slit lamp for any complications such as graft oedema, graft granuloma and recurrence etc.

3.11. Study tools

Proforma for informed written consent, proforma for data collection, torch- light, slit lamp, instruments needed for both the surgical procedures.

3.12. Statistical analysis

Collected data were entered in excel data sheet and statistical analysis were performed using SPSS version 20.0

software. The Chi-square test and Student t-test were used to compare qualitative and continuous quantitative variables, respectively. A 'p' value < 0.05 was considered significant.

4. Results

52 patients were randomly and equally divided into two groups-group A (fibrin glue group) and group B (suture with polyglactin group) according to the type of surgery. In both the groups, there was female preponderance and the average age of the patients were 45.15 (\pm 5.576) and 40.65 (\pm 8.299) years respectively. Regarding the post-operative complications such as graft oedema ($p = 0.002$, $\chi^2 = 10.035$, $df = 1$), graft granuloma ($p = 0.037$, $\chi^2 = 4.333$, $df = 1$) and recurrence ($p = 0.638$, $\chi^2 = 0.221$, $df = 1$) (Table 1), the group A had less incidence than group B. The reduction in complications was statistically significant in group A in terms of graft oedema and granuloma formation but not in recurrence. The average size of pterygium which was operated was 2.94 (\pm 0.698) mm (Table 2). The average time of surgery in terms of fibrin glue group and polyglactin suture group were 18.65 (\pm 16.71) and 32.69 (\pm 24.01) minutes respectively. The recurrence rate of pterygium after surgery was increased with increasing size of pterygium and it was statistically significant ($\chi^2 = 9.690$, $p = 0.007$). (Table 3) It was found that the incidence of recurrence was low in fibrin glue group in comparison to polyglactin suture group as a whole but it was more with the size of pterygium. (Table 4) The incidence of pterygium was found more common in housewives in both the groups. (Table 5)

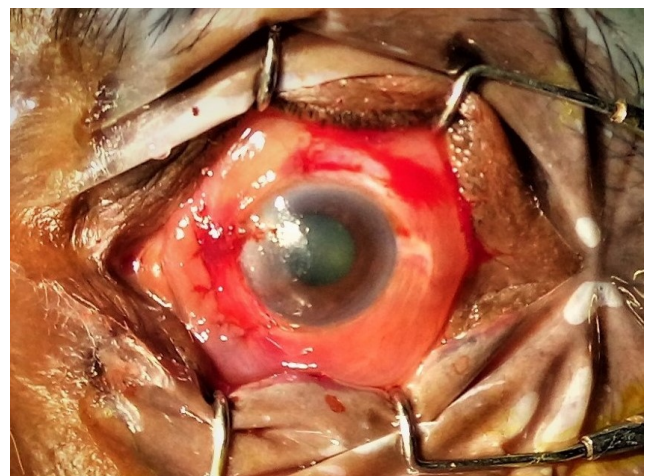


Fig. 1: Pterygium excision with autograft sutured with polyglactin

Table 1: Distribution of study subjects according to the incidence of post- operative complications of different surgical procedures (Fibrin glue group and Polyglactin suture group).

Type of surgery	Graft oedema (%)		Chi-square Test (χ^2) $\chi^2=10.035$, p = 0.002	Graft granuloma (%)		Chi-square Test (χ^2) $\chi^2 = 4.333$, p = 0.037	Recurrence (%)		Chi-square Test (χ^2) $\chi^2 = 0.221$, p = 0.638
	Yes	No		Yes	No		Yes	No	
Fibrin glue	4 (07.7)	22(42.3)		0(0.0)	26(50.0)		2(03.8)	24(46.2)	
Suture with Polyglactin	15(28.8)	11(21.2)		4 (07.7)	22(42.3)		3(05.8)	23(44.2)	

Table 2: Distribution of study subjects according to size of pterygium of different surgical procedure (Fibrin Glue group and Polyglactin Suture group)

Size of Pterygium (mm)	Fibrin Glue group	Polyglactin Suture group	Total	Chi-square Test (χ^2)
2mm	6 (11.5%)	8 (15.4%)	14 (26.9%)	$\chi^2 = 2.0298$ p = 0.362
3mm	16(30.8%)	11(21.1%)	27(51.9%)	
4mm	4 (7.7%)	7(13.5%)	11(21.2%)	
Total	26 (50%)	26 (50%)	52(100%)	

Table 3: Incidence of recurrence according to the size of pterygium

Size of pterygium (mm)	Recurrence (%)		Total	Chi-square Test (χ^2) $\chi^2 = 9.690$, p = 0.007
	Yes	No		
2	1(1.9)	13(25.0)	26.9%	
3	2(3.8)	25(51.9)	51.9%	
4	5(9.6)	6(11.6)	21.2%	
Total	5(9.6)	47(90.4)	100%	

Table 4: Incidence of recurrence according to the size of pterygium of different surgical procedures (Fibrin glue group and Polyglactin suture group) at 5-6 months of follow up

Size of pterygium (mm)	Fibrin glue group Recurrence (%)		Polyglactin suture group Recurrence (%)		Total
	Yes	No	Yes	No	
2	0(0.00)	6 (11.5)	1(1.9)	7 (13.5)	14 (26.9%)
3	0(0.00)	16 (30.8)	2 (3.8)	9 (17.3)	37 (51.9%)
4	2 (3.8)	2 (3.8)	3 (5.8)	4 (7.7)	11 (21.2%)
Total	2(3.8)	24 (46.2)	6 (11.5)	20 (38.5)	52 (100%)

Table 5: Distribution of study subject according to their occupation of different surgical procedures (Fibrin glue group and Polyglactin suture group)

Types of surgery	Occupation			Total	Chi-square Test (χ^2) $\chi^2 = 0.733$ p = 0.693
	Housewife	Agricultural worker	Other unskilled worker		
Fibrin Glue Group	15 (28.8%)	7 (13.5%)	4 (07.7%)	26 (50.0%)	
Polyglactin Sutures	15 (28.8%)	5 (09.6%)	6 (11.6%)	26 (50.0%)	
Total	30 (57.6%)	12 (23.1%)	10 (19.3%)	52(100%)	

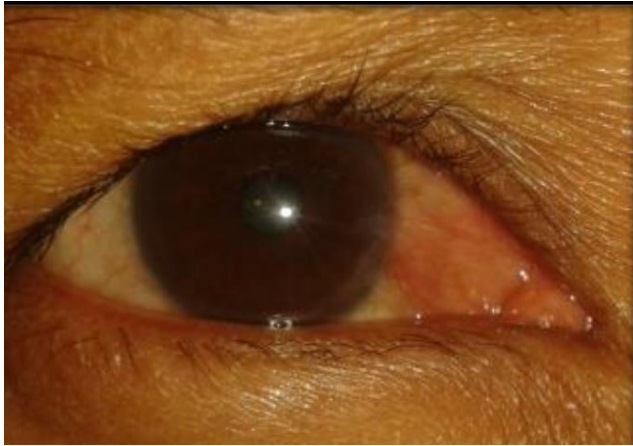

Fig. 2: Recurrence following pterygium surgery

5. Discussion

Although autologous limbalconjunctival grafting is an effective mode for preventing recurrence following pterygium excision but biological tissue adhesives like fibrin glue attachment of graft may prevent suture induced complications such as foreign body sensation, discomfort, dellen formation and symblepharon.

Bahar I et al¹¹ showed that the mean age of the study population was 49 years (± 12 years) but present study showed 42.9 years (± 7.36 years). It showed that study population had female preponderance which was corroborating in the present study.

Wadgaonkar SP et al¹³ found that the mean operative time was 15.76 min and 33.56 min in the fibrin glue group and the vicryl suture group respectively. Bora Y et al¹⁴ showed that the mean operative time was 23.42 ± 13.34 min and 41.45 ± 3.20 min in the fibrin glue and the suture group respectively. ($p < 0.05$) Bahar I et al¹¹ suggested the average operative time was 16 minutes and 28 mins in the fibrin group and in the vicryl suture group respectively. ($p < 0.05$) Hall RC et al¹⁵ showed that the mean surgical time for the fibrin glue group was significantly shorter at 12 minutes compared with the suture group at 26 minutes ($p < 0.001$). The present study showed that surgical time was $18.65 (\pm 16.71)$ min and $32.69 (\pm 24.01)$ min in the fibrin glue and the suture group respectively. The operating time was significantly less in the fibrin glue group in comparison to suture group. ($p < 0.001$).

Bora Y et al¹⁴ suggested that there was one case of haemorrhage under the graft (3.4%), one case of dellen and conjunctival cyst formation each in the fibrin group. No such complication was seen in the suture group. There was one case of granuloma formation in fibrin glue group whereas 7 cases in the suture group. Wadgaonkar SP et al¹³ showed that there were two episodes of subconjunctival haemorrhage in the suture group (8%) and none in the glue group. There was 1 case of pyogenic granuloma in the fibrin

glue group (4%) and none in the suture group. Bahar I et al¹¹ found that there was no complication during follow up period in the fibrin glue used patients. One patient had medically treatable corneal dellen in suture group. Hall RC et al¹⁵ found that there was a graft dehiscence in the fibrin glue group that required re-positioning. The present study showed that there was significant reduction in 'graft oedema' ($p = 0.002$) and granuloma formation ($p = 0.037$) in the fibrin glue group in comparison to the suture group.

Bahar I et al¹¹ showed that the recurrence rate was higher in fibrin glue group (11.9%) in comparison to the suture group (7.7%) ($p < 0.05$). Goswami S. et al¹⁶ stated that recurrence was found more in suture group (10%) than in the glue group after 12 months of follow-up.

($p < 0.05$) Bora Y et al¹⁴ suggested that pterygium recurrence was developed in fibrin glue group (6.8%) and in the suture group (13.7%). ($p < 0.05$) Bahar I et al¹¹ showed that recurrence was more in fibrin group (11.9%) than that of suture group (7.7%) ($p < 0.05$).

Wadgaonkar SP et al¹³ showed that there were 2 cases (8%) of recurrences after six months in the suture group but none in the fibrin glue group. ($p < 0.05$)

In our study there was no significant recurrence between the two study groups ($p = 0.638$) The recurrence was more in the suture group (11.6%) than in the glue group (7.7%) and it was found in 5-6 months follow up.

6. Conclusion

The fibrin glue group reported significantly higher overall satisfaction with its excellent haemostasis properties, preventing foreign body sensation, discomfort, less time consumption, low recurrence rate and easier to perform in comparison to suture polyglactin group though glue is costlier than suture.

7. Source of Funding

None.

8. Conflict of Interest

None.

References

1. Duke-Elder S. System of Ophthalmology. In: Disease of the Outer Eye, 2nd edition. vol. 8. St. Louis: CV Mosby ; 1965., p. 573–583.
2. Hippocrates of Kos. Predictions II. V-IV century BC ;
3. Coroneo MT, Girolamo ND, Wakefield D. The pathogenesis of pterygia. *Curr Opin Ophthalmol*. 1999;10(4):282–288.
4. Hill JC, Maske R. Pathogenesis of pterygium. *Eye*. 1989;3(2):218–226.
5. Coroneo MT. Pterygium as an early indicator of ultraviolet insolation: a hypothesis. *Br J Ophthalmol*. 1993;77(11):734–739.
6. Cameron ME. Pterygium throughout the world ; 1965.,
7. Goldberg L, David R. Pterygium and its relationship to the dry eye in the Bantu. *Br J Ophthalmol*. 1976;60(10):720–721.

8. Pico G, King JH, Mctigue JW. The cornea world congress. *Butterworth Inc.* 1965;p. 280–291.
9. Moran DJ, Hollows FC. Pterygium and ultraviolet radiation: a positive correlation. *Br J Ophthalmol.* 1984;68(5):343–346.
10. Karalezli A, Kucukerdonmez C, Akova YA, Altan-Yaycioglu R, Borazan M. Fibrin glue versus sutures for conjunctival autografting in pterygium surgery: a prospective comparative study. *Br J Ophthalmol.* 2008;92(9):1206–1210.
11. Bahar I, Weinberger D, Gaton DD, Avisar R. Fibrin Glue versus Vicryl Sutures for Primary Conjunctival Closure in Pterygium Surgery: Long-Term Results. *Curr Eye Res.* 2007;32(5):399–405.
12. Panda A, Kumar S, Kumar A, Bansal R, Bhartiya S. Fibrin glue in ophthalmology. *Indian J Ophthalmol.* 2009;57(5):371–379.
13. Tiwari RR, Wadgaonkar S, Patil PA, Kamble BS. Fibrin glue versus suture technique for pterygium excision: A prospective study in tertiary-based rural hospital. *J Clin Ophthalmol Res.* 2017;5(1):23–27.
14. Yüksel B, Kayaünsal S, Unat S. comparison of fibrin glue and suturing technique in pterygium surgery performed with limbal autograft. *Int J Ophthalmol.* 2010;3(4):316–320.
15. Hall RC, Logan AJ, Wells AP. Comparison of fibrin glue with sutures for pterygium excision surgery with conjunctival autografts. *Clin Exp Ophthalmol.* 2009;37(6):584–589.
16. Goswami S, Chatterjee SS, Gowsami S, Bhaduri G. A comparative study of use of fibrin glue and vicryl suture in conjunctival autograft transplantation following pterygium excision. *Indian J Basic Appl Med Res.* 2014;4:169–175.

Author biography

Piyali Sarkar Associate Professor

Kumaresh Chandra Sarkar Associate Professor

Sujit Mondal Postgraduate Student

Rabindra Nath Saha Professor

Cite this article: Sarkar P, Sarkar KC, Mondal S, Saha RN. Comparison between fibrin glue and polyglactin sutures in limbal based conjunctival autograft technique in primary pterygium surgery in adults- A randomised controlled trial. *Indian J Clin Exp Ophthalmol* 2020;6(1):35–40.