



Case Report

Plant sap keratouveitis

Vasantha N¹, Theertha Rajesh^{1,*}, Mohammed Haneef¹, Haleema A¹, Parvathy P S¹¹Dept. of Ophthalmology, Azeezia Medical College, Meeyannoor, Kerala, India

ARTICLE INFO

Article history:

Received 17-10-2019

Accepted 21-10-2019

Available online 27-11-2019

Keywords:

Plant sap

Striate keratopathy

ABSTRACT

Sap from plants commonly seen in the gardens can cause various degrees of inflammation when the y enter into the eye. There are few plants which have sap are Calotropis Procera, Euphorbia Tirucalli, Dieffenbachia Sequine, Candelabra Cactus, Fig etc. The juices of these plants have been shown to possess several pharmacological properties. Several cases of plant sap -induced keratouveitis reported here, showed varying clinical signs like lid oedema, corneal epithelial defect, corneal oedema with descemets folds and cells in the anterior chamber. The ocular inflammation was reversed by the topical application of Steroid drops, Mydriatics and other supportive measures.

© 2019 Published by Innovative Publication. This is an open access article under the CC BY-NC-ND license (<https://creativecommons.org/licenses/by/4.0/>)

1. Introduction

Some garden plants which produce milky juice s can cause ocular injuries in case of accidental contact with human eyes. The plant juice from different kinds of plants contains varying chemical components. Few of them are toxic and can elicit different pathogenic mechanisms and varied clinical manifestations. The ocular injuries which can be caused by plant juice from the family of Euphorbiaceae consists of contact or photo dermatitis, conjunctivitis, keratitis of varied intensity, corneal ulceration, uveitis with or without hypopyon, corneal scarring, miosis and blindness.^{1,2} Plants from genera Dieffenbachia have been reported to cause mild to moderate conjunctival chemosis with congestion, subconjunctival hemorrhage, and fine needle-like blue crystals in the corneal stroma.³⁻⁵ We report a case of ocular injuries caused by

1. Euphorbia tirucalli (also known as pencil tree, milk bush, malabar tree) sap
2. Dieffenbachia sequine (dumb-cane) sap
3. Euphorbia tithymaloides.

2. Case Report

2.1. Case 1

A 35 -year-old male suffered plant juice fall on his face while he was cutting Euphorbia tirucalli. He suddenly washed his face with tap water. After some time, developed a foreign body sensation in right eye. There was associated burning pain with red eye and visual blurring for 4 hours. Then he came to ophthalmology OPD where examination findings showed visual acuity of 6/12 OD and 6/6 OS, with moderate conjunctival congestion. He was given thorough eye wash and started initial treatment with topical corticosteroids, cycloplegics and antibiotic eye drops. On following day there was a reduction in vision to 6/18 OD. Stromal edema and Descemet's folds developed in the right eye. Anterior chamber showed 2+ cells and moderate flare. The intraocular pressure and fundus were unremarkable. Treatment consisted of topical 1% prednisolone acetate eye drops, 2% homatropine eye drops and 0.5% moxifloxacin eye drops. The epithelial erosions healed in 2 days, and the stromal edema and anterior chamber reaction back to normal in 1 week. His vision returned to 6/6 OD with no findings in the cornea.

* Corresponding author.

E-mail address: rajeshtheertha@gmail.com (T. Rajesh).

2.2. Case 2

A 24-year-old male was accidentally inoculated with the *Dieffenbachia* sequine (Figure 3) sap into his left eye while he was cutting it. He felt a stinging pain and watering immediately. He irrigated his left eye with tap water by himself, and was given eye wash from a local hospital 2 hours later. The symptoms worsened and visual blurring progressed, so he came to our OPD 5 hours later. On examination of the left eye visual acuity was 6/24, with mild eyelid swelling, conjunctival chemosis with corneal epithelium intact. There was mild stromal edema, descemet's membrane folds and fine KPs +. Anterior chamber showed 1+ cells and mild flare. The examination done in the next day showed that visual acuity in the left eye was still same. There was mild upper eyelid swelling, as well as mild conjunctival chemosis and congestion (Figure 4). The cornea showed mild stromal edema from subepithelial layer to the posterior stroma which were predominantly in the interpalpebral area. The intraocular pressure, anterior chamber and fundus were unremarkable. The left eye was treated with topical 1% prednisolone acetate, 2% homatropine eye drops and moxifloxacin eye ointment. On his last follow-up vision returned to 6/6



Fig. 1:

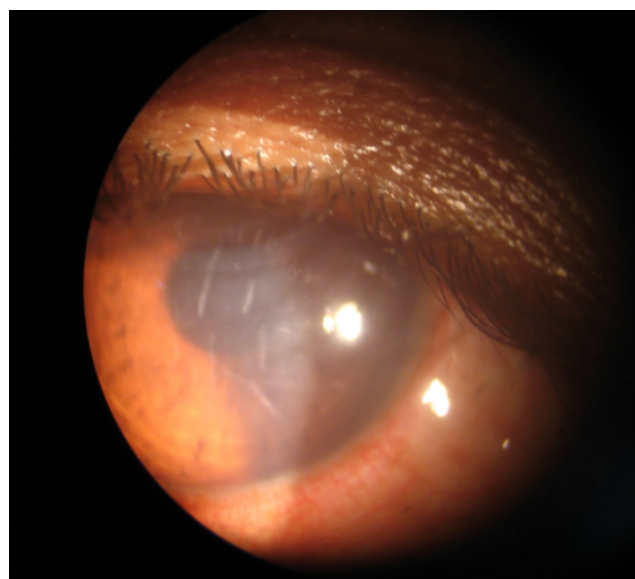


Fig. 2:

2.3. Case 3

65 year old male presented with history of fall of sap from *Euphorbia tithymaloides* plant (Figure 5) in the right eye of 3 hours duration. Slit lamp examination showed lid oedema, circumferential corneal congestion and chemosis (Figure 6). An epithelial defect of size 8.5mm x 5 mm was noticed in the central cornea (Figure 7). Corneal haze due to corneal oedema and numerous Descemet's Membrane folds were present. Fine KPs +. Anterior chamber showed 3+ cells and moderate flare. The visual acuity was CF 5m in the affected eye. The patient was treated with topical 1% prednisolone acetate eye drops, 2% homatropine eye drops and 0.5% moxifloxacin eye drops. After a period of one week, cornea cleared and the visual acuity improved to 6/12 (immature senile cortical cataract present).



Fig. 3:

3. Discussion

There are about 12 families, 20 genera and above 5000 species of plants were known to have milky sap worldwide. They are used in various fields like decoration, food, or medicine, and have industrial value. The components of the plant sap are not yet known, but the toxic constituents have been identified, which include essential oil, alkaloids, amino acids, cyanogenic glycerides, cardioactive glycerides, furanocoumarins, plant acids, poly-acetylene compounds, proteins, peptides, saponins and terpenes.⁶

The most common plants whose sap are known to cause keratitis are: *Calotropis*, *Euphorbia*^{7–10} *Dieffenbachia*,¹¹ *Hippomane*¹², *Asclepias*.¹³

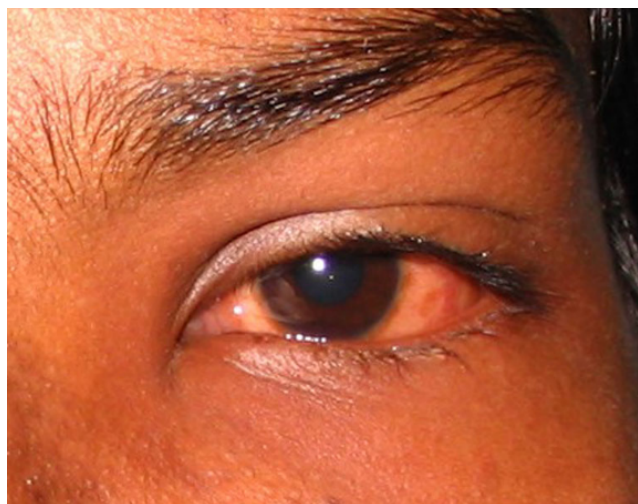

Fig. 4:



Fig. 5:

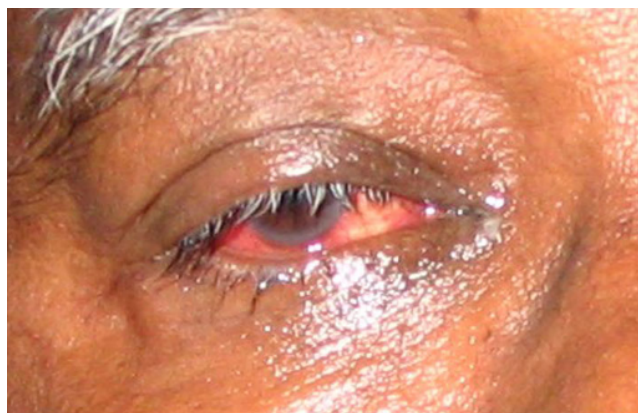

Fig. 6:

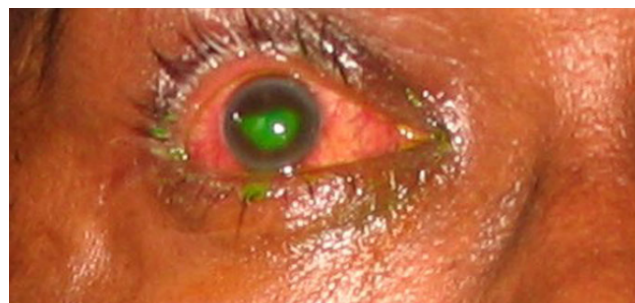


Fig. 7:

1. Common name: erukku

Family: Apocynaceae

Standard plant name: Calotropis procera

2. Common name: Pencil tree

Family: Euphorbiaceae

Standard plant name: Euphorbia tirucalli

The latex is a caustic milky white juice produced when damaged, like other Euphorbia species. Euphorbiaceae plants are known to store large amounts of latex in their organ called the laticifer¹⁴ The major constituents of the plant sap are isomers of triterpenes with the molecular formula C₃₀H₅₀O (MW: 426), such as euphol, tirucallol, glut-5-en-3-b -ol, cycloeuphordenol, euphorginol, aamyrin, lanosterol, cycloartenol etc.^{15–18}

3. Common name: Candelabra cactus

Family name: Euphorbiaceae

Standard plant name: Euphorbia lactea

4. Common name: creeping fig

Family: Moraceae

Standard plant name: Ficus pumila

F. pumila contains numerous sesquiterpenoid glucosides as well as triterpenes^{19,20} Two compounds (bergapten and oxypeucedaninhydrate) have previously been isolated from this plant²¹

4. Common name: Manchineel

Standard plant name : Hippomane manchinella

Milky white sap contains phorbol. Burning these plants may cause ocular injuries if it's smoke reaches the eye.

5. Common name: madder

Family : Rubiaceae

Standard plant name: Rubia sp.

6. Common name :Dumb canes

Family: Dieffenbachia

Standard plant name: Dieffenbachia seguine, Dieffenbachia amoena

Dieffenbachia species contains raphides which are crystalline, needle like structures the plant ejects when cell walls are damaged. The structures are usually found in the sap which also contains oxalic acid and asparagine.

7. Common name: Kakatundi

Family: Apocynaceae

Standard plant name: *Asclepias curassavica*

Asclepain C-II is the minor proteolytic component seen in the latex, but showed higher specific activity than asclepain C-I. Both enzymes showed proteolytic activity at pH 9.4-10.2, but poor thermostability. The activities of asclepain C-II is shown to be inhibited by cysteine protease inhibitors like E-64, but not by any of the other protease inhibitors such as 1, 10-phenantroline, phenyl methane sulfonyl fluoride, and pepstatine.²²

8. Common name: Chulli kandal

Family: Acanthaceae

Standard plant name: *Acanthus ilicifolius*

4. Conclusion

Plant sap keratitis is a major cause of occupational injury to the eyes in people who work with plants which produce milky latex. They should be cautioned to wear gloves and eye protection (goggles) and to wash the exposed areas of their body with soap and water before contact with any individual. Patients who give a history of plant sap entering into their eyes should be immediately irrigated with copious amount of normal saline and be warned that their vision might get worse before it improves over hours or days. Close follow up is important in the first few days to control inflammation and to prevent secondary infection and complications.

5. Source of Funding

None.

6. Conflict of Interest

None.

References

1. Eke T, Al-Husainy S, Raynor MK. The spectrum of ocular inflammation caused by Euphorbia plant sap. *Arch Ophthalmol*. 2000;118:13–16.
2. Scott IU, Karp CL. Euphorbia sap keratopathy: four cases and a possible pathogenic mechanism. *Br J Ophthalmol*. 1996;80:823–826.
3. Seet B, Chan WK, Ang CL. Crystalline keratopathy from Diffenbachia plant sap. *Br J Ophthalmol*. 1995;79:98–99.
4. Ellis W, Barfort P, Mastman GJ. Keratoconjunctivitis with corneal crystals caused by the Dieffenbachia plant. *Am J Ophthalmol*. 1973;76:143–147.
5. Fochtman FW, Manno JE, Winek CL, Cooper JA. Toxicity of the genus Dieffenbachia. *Toxicol appl Pharmacol*. 1969;15:38–45.
6. MICROMEDEX Inc. 1974-2000. POISINDEX® & IDENTIDEX® Systems <http://lib.vgtp.e.gov.tw/cgi-bin/mdxcgi/mdxhtml.exe?&tmpl=pdfsrch.tml&SCRNAME=pdfsrch&CTL=/ovid/mdx/mdxcgi/megat.sys;>
7. Hsueh KF, Lin PY, Lee SM, Hsieh CF. Ocular Injuries from Plant Sap of Genera Euphorbia and Dieffenbachia. *J Chin Med Assoc*. 2004;67:93–98.
8. Eke T, AH, Raynor S, MK. The spectrum of ocular inflammation caused by Euphorbia plant sap. *Arch Ophthalmol*. 2000;118:13–16.
9. Scott IU, Karp CL. Euphorbia sap keratopathy: four cases and a possible pathogenic mechanism. *Br J Ophthalmol*. 1996;80:823–826.
10. Biedner BZ, Sachs U, Witzum A. Euphorbia peplus latex keratoconjunctivitis. *Ann Ophthalmol*. 1981;13:739–740.
11. Seet B, Chan WK, Ang CL. Crystalline keratopathy from Diffenbachia plant sap. *Br J Ophthalmol*. 1995;79:98–99.
12. Pitts JF, Barker NH, Gibbons DC, Jay JL. Manchineeel keratoconjunctivitis. *Br J Ophthalmol*. 1993;77:284–288.
13. Chakraborty S, Siegenthaler J, Bchi ER. Corneal edema due to *Asclepias curassavica*. *Arch Ophthalmol*. 1995;113:974–975.
14. Tirucalli LSSGE, In. -. *Biblioteca Agraria Coloniale Istituto Agricolo Coloniale Italiano, Firenze*. 1916;p. 1–87.
15. McDonald AD, Warren FL, Williams JM. The Euphorbiaresins. *J Chem Soc* ;1949:155–157.
16. Nemethy EK, Otvos JW, Calvin M. Analysis of extractables from one Euphorbia. *J Am Oil Chem Soc*. 1979;56:957–960.
17. Nemethy EK, Calvin M. Terpenoid biosynthesis in Euphorbia latex. In: Thomson WW, Mudd JB, Bibbs M (eds) *Biosynthesis and Function of Plant Lipids: Proceedings of The Sixth Annual Symposium in Botany* ; 1983., p. 216–228.
18. Nielsen PE, Nishimura H, Otvos JW, Calvin M. Plant crops as a source of fuel and hydrocarbon-like materials. *Sci*. 1977;198:942–944.
19. Kitajima J, Kimizuka K, Tanaka Y. Three new sesquiterpenoid glucosides of *Ficus pumila* fruit. *Chem Pharm Bull(Tokyo)*. 2000;48:77–80.
20. Ragasa CY, Rideout JE, *Ficus pumila* JAT. A triterpene from *Ficus pumila*. *J Asian Nat Prod Res*. 1999;1:269–275.
21. Juan EA, Rideout JA, Ragasa CY. Bioactive furanocoumarin derivatives from *Ficus pumila*. *Philipp J Sci*. 1997;126:143–153.
22. Liggieri C, Obregon W, Trejo S, Priolo N. Biochemical analysis of a papain-like protease isolated from the latex of *Asclepias curassavica* L. *Acta Biochim Biophys Sin (Shanghai)*. 2009;41(2):154–162.

Author biography

Vasantha N Assistant Professor

Theertha Rajesh Post Graduate Resident

Mohammed Haneef Professor and HOD

Haleema A Assistant Professor

Parvathy P S Senior Resident

Cite this article: Vasantha N , Rajesh T, Haneef M, Haleema A , Parvathy P S . Plant sap keratouveitis. *Indian J Clin Exp Ophthalmol* 2019;5(4):589-592.