



Original Research Article

A comparative study on oblique stab incision sics and phacoemulsification

G. Srinivasan¹, Sheetal^{1,*}¹Dept. of Ophthalmology, Saveetha Medical College Hospital, Chennai, Tamil Nadu, India

ARTICLE INFO

Article history:

Received 31-08-2019

Accepted 18-10-2019

Available online 27-11-2019

Keywords:

Oblique stab incision Small incision
cataract surgery
Phacoemulsification
Modified SICS

ABSTRACT

Aim: To study the effectiveness of oblique limbal stab incision in manual SICS in self-sealing, visual outcome and degree of surgically induced astigmatism when compared to phacoemulsification surgery. Surgical steps like superior rectus suture, conjunctival flap and cautery are eliminated in limbal stab incision SICS.

Materials and Methods: A Study sample of 100 patients were included. The technique of limbal stab incision SICS was carried out on one eye of 50 patients and was compared with 50 age and sex matched patients undergoing phacoemulsification. A standard preoperative and post-operative care and medications was given to both groups. The patients were subjected to preoperative evaluation such as visual acuity, slit lamp examination, IOP recording, fundus, keratometry and biometry. Periodic follow up was done till 12 weeks postoperatively. Visual acuity by Snellen chart, keratometry to know amount of astigmatism at the end of 12 weeks was compared in both the procedures.

Results: The post op visual acuity, SIA in both the groups were found to be equally comparable stating that the modified SICS can be an alternative for phacoemulsification.

Conclusion: The modified version of SICS can achieve the following. It can be done less surgical duration. It can be done under topical anaesthesia. Rigid IOL can be placed thereby making the procedure available for patients not affordable for phacoemulsification. No suture is required thereby it causes less astigmatism.

© 2019 Published by Innovative Publication. This is an open access article under the CC BY-NC-ND license (<https://creativecommons.org/licenses/by/4.0/>)

1. Introduction

The aim of cataract surgery in the recent era is to achieve visual enhancement and not just attaining visual restoration. Both Small incision cataract surgery and phacoemulsification achieve good results in terms of visual outcome and have less complication rates. But Phacoemulsification is always preferred over Small incision cataract surgery in standard situations but because of its high cost due to the machines, foldable IOL, long training curves makes the surgery unaffordable for the poor patients. This study was done to establish a cheaper as well as effective alternative to original SICS the results of which are comparable to the results achieved by phacoemulsification. The site of incision is purely scleral in SICS and clear corneal in phacoemulsification. There is better anterior

chamber approach in clear cornea but the incision cannot be extended for the need of implantation of rigid Intraocular lens or in complicated cataract surgery where suture is required which can cause high degree of astigmatism. In another aspect the sclera incision can be extended until needed for the rigid IOL implantation. In spite of the large incision, it produces less degree of astigmatism and less chance of acquiring infection. But the surgery becomes difficult in hard cataract, deep set eyes and small pupils. Therefore, the sclerocorneal tunnel incision has the advantage of better anterior chamber approach and less incision induced astigmatism. A newer site of incision, limbal incision will have a faster healing and it can resist deformation pressure than corneal incision. The technique of SICS is less expensive and less dependent on machines when compared to phacoemulsification. Thereby tunnel construction with direct limbal stab incision was

* Corresponding author.

E-mail address: sheetaljkmr@gmail.com (Sheetal).

studied. The results of this incision was compared to phacoemulsification in terms of effectiveness of self-sealing, nucleus delivery, visual outcomes and surgically induced astigmatism.

2. Materials and Methods

A total of 100 patients were included in the study, 50 of them underwent phacoemulsification and the rest 50 underwent SICS with the modified direct oblique limbal stab incision. A thorough pre-operative evaluation including visual acuity, grading of cataract, fundus examination, calculation of IOL power, intraocular pressure measurement were all done. Patients were selected according to the inclusion and exclusion criteria.

2.1. Inclusion criteria

All grades of cataract in patients above 35 years were included.

2.2. Exclusion criteria

Patients below 35 years of age were excluded.

Patients with glaucoma, squint, corneal and retinal pathology ruled out.

2.3. Technique of direct oblique limbal incision

Incision: Under sterile aseptic precaution the wire speculum is applied. With 3.2mm keratome a direct stab incision is made through the limbal conjunctiva. After entering the cornea of about 1-2mm, a sharp entry is made into the anterior chamber. The shape of external incision is straight or can be curved while the shape of the internal incision is straight. The incision is placed superotemporally in the right eye and superonasally in the left eye for the convenience of right handed surgeons.

2.4. Self sealing tunnel

The tunnel is extended for the needed length based on the size of nucleus. The length can vary from 6-6.5 mm.

2.5. Capsular opening

The capsule can be opened by either can opener technique or continuous curvilinear capsulorhexis with or without the relaxing cuts for larger nuclei is made with the tip of 26 G needle.

2.6. Nucleus delivery

After performing hydrodissection, the nucleus is delivered by sandwich technique.

A thorough cortex was is done and the Rigid IOL is placed in the posterior bag.

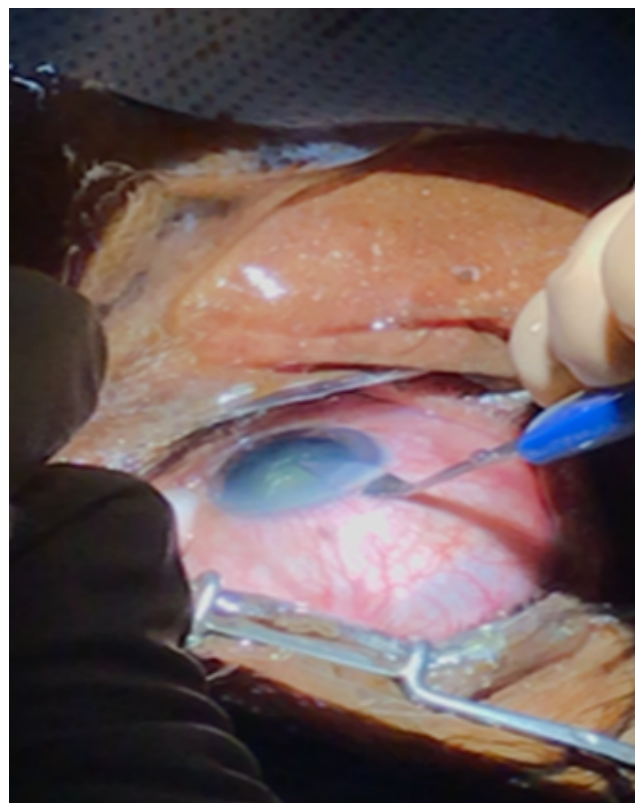


Fig. 1: Oblique limbal stab incision

2.7. Lens placement

Rigid IOL is placed in the bag.

2.8. Wound closure

Subconjunctival dexamethasone and gentamycin is given at the incision site.

3. Results

The study was carried out on 100 patients, 50 of them underwent phacoemulsification and 50 others underwent direct stab incision SICS. The SICS patients were categorised as group A and phacoemulsification patients were categorised as group B. These groups were further subdivided into A1 and B1 for the right eyes and A2 and B2 for the left eyes. The results were compared in terms of visual outcome, surgically induced astigmatism and complications. The patients were followed up for a period of about 6 weeks. The preoperative and postoperative Keratometry values are tabulated as in Tables 1 and 2.

Mean Surgically induced astigmatism was measured at the end of 6 weeks as showed in the table 3 concluded that the astigmatism was less in patients who underwent phacoemulsification as they had small incision and this difference was statistically significant with a p value of

Table 1:

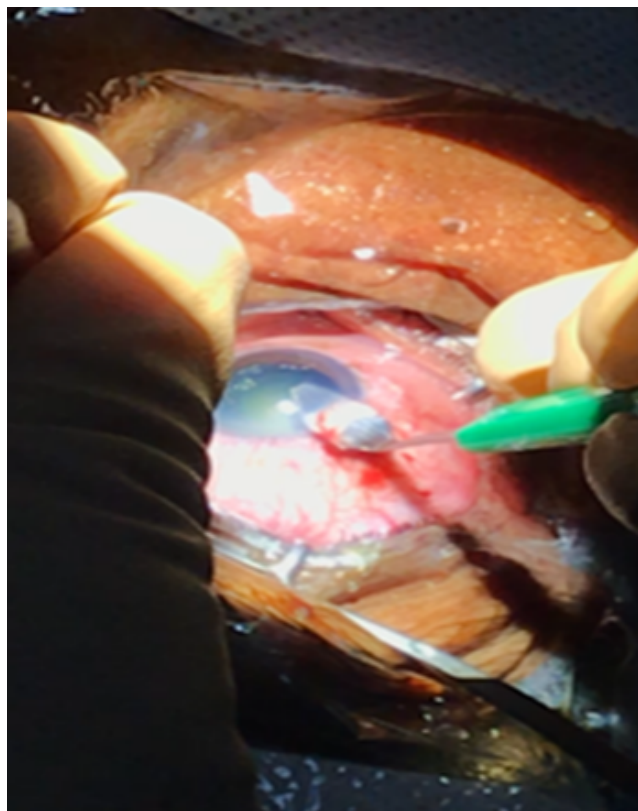
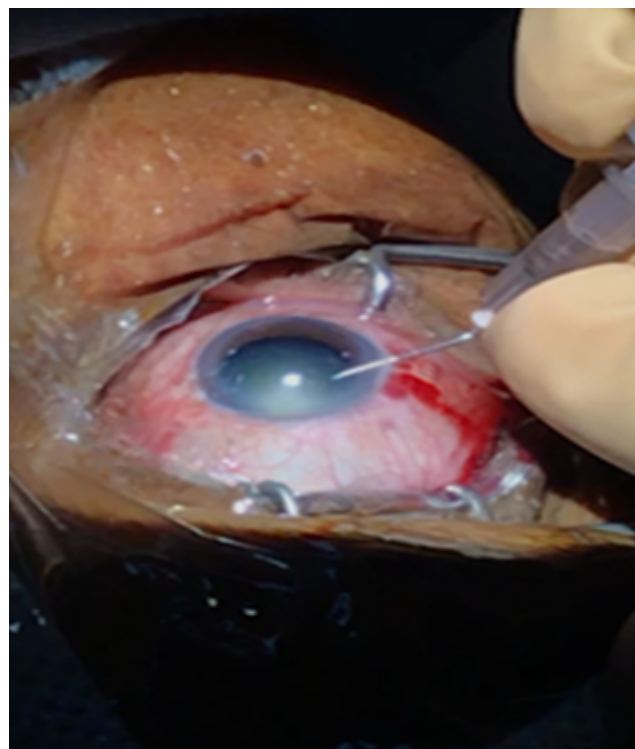Keratometry	Sics Right	Left	Phaco Right	Left	Total
<0.25	4	1	3	4	12
0.25 – 1.0	2	2	1	3	8
1 – 1.5	16	21	19	14	70
>1.5	3	1	2	4	10
Total	25	25	25	25	100

Table 2:

Keratometry	Sics Right	Left	Phaco Right	Left	Total
<0.25	0	0	0	1	1(1%)
0.25 – 1.0	12	6	10	8	36(36%)
1 – 1.5	13	17	12	15	57(57%)
>1.5	0	2	3	1	6(6%)
Total	25	25	25	25	100

Table 3:

SIA	SICS	PHACO	Total
NIL	6	12	18(18%)
<0.25	0	2	2(2%)
0.25 – 1.0	35	32	67(67%)
1 – 2	9	4	13(13%)
Total	50	50	100(100%)

**Fig. 2:** Tunnel extension**Fig. 3:** Can opener capsulotomy

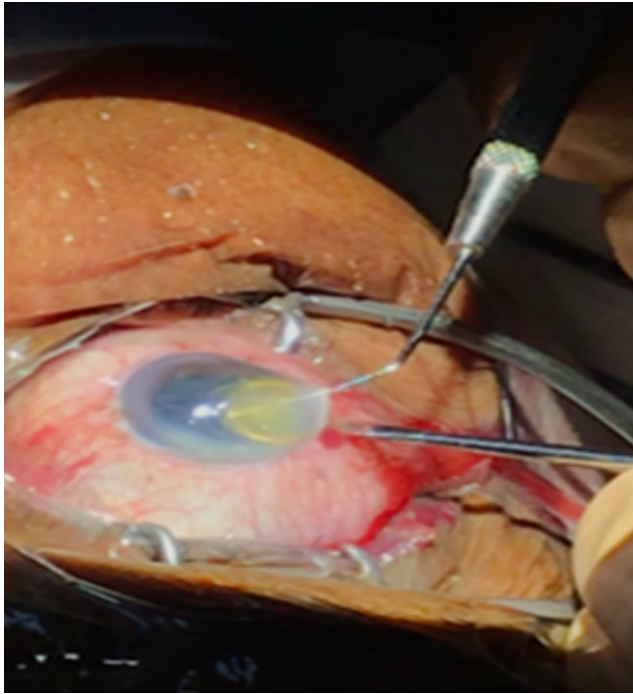


Fig. 4: Nucleus delivery by sandwich technique

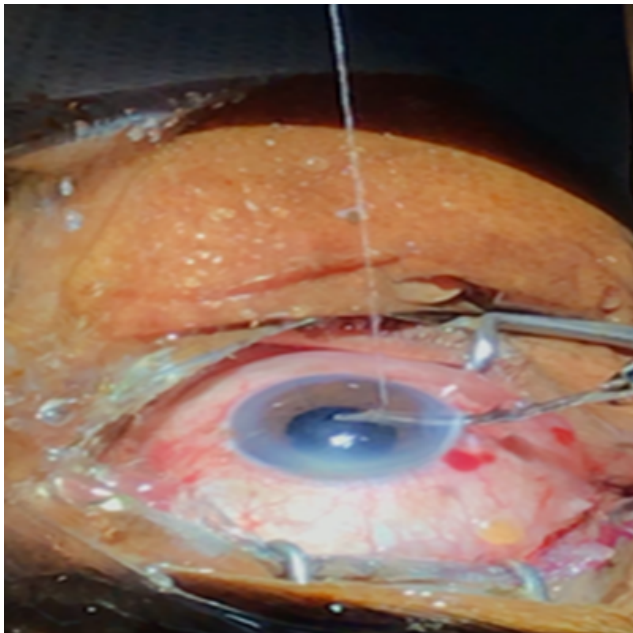


Fig. 5: Cortical wash

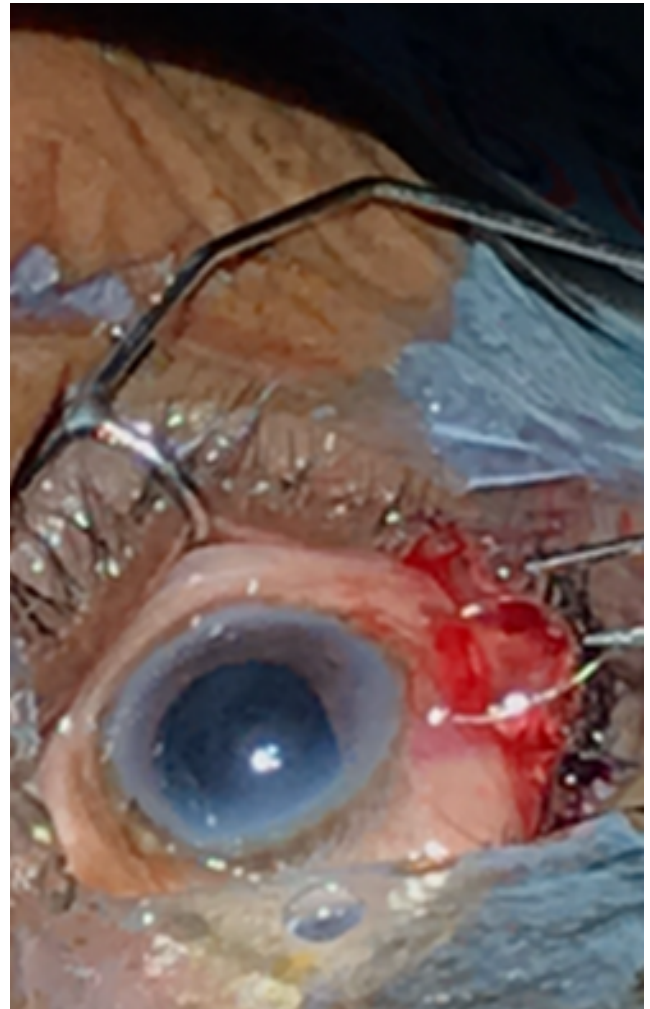


Fig. 6: IOL placement

<0.005.

Most common complication in oblique stab incision SICS was Subconjunctival haemorrhage accounting for about 30% compared to 8% in phacoemulsification. The second most complication was striate keratopathy accounting for 12% in SICS as compared to 18% in phacoemulsification. One case had posterior capsular rent in phacoemulsification. Residual cortex was more in phacoemulsification accounting 6% as to 2% in Modified SICS.

4. Discussion

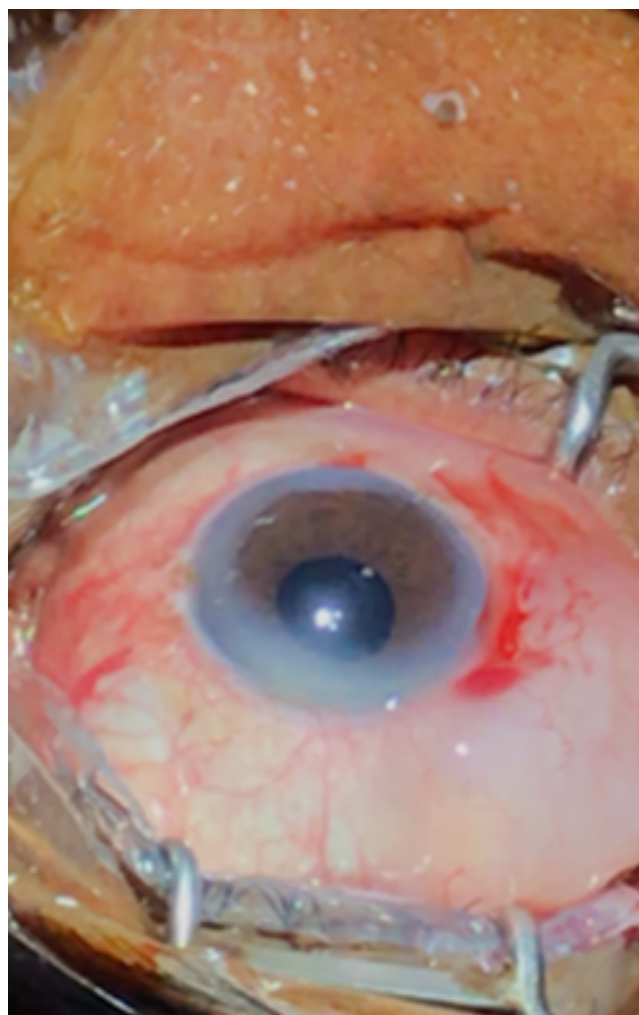
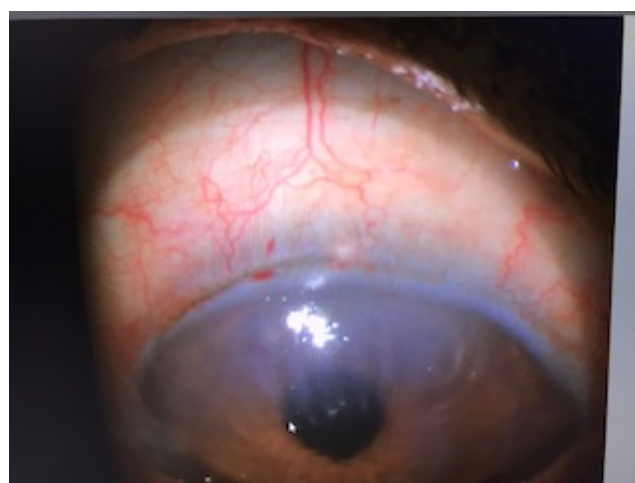The cataract surgery techniques have been evolving since its first description by Sushruta. The older technique ICCE (Intracapsular cataract extraction) is rarely performed nowadays. Nowadays phacoemulsification is done worldwide. SICS (Small incision cataract surgery) is an age-old technique that is simple, effective, cost effective and has easier learning curve. It has very good postoperative

Table 4:

Complications	SICS	PHACO
Sch	15	4
Striate keratopathy	6	9
Posterior capsule rent	0	1
Residual cortex	1	2
Total	22	16

Table 5:

Visual Aquity	6/6	6/9	6/12	6/18	6/24	Total
Group A (SICS)	13	28	4	3	2	50
Group B (PHACO)	34	8	5	2	1	50
Total	47	36	9	5	3	100

**Fig. 7:** Wound closure**Fig. 8:** Striate keratitis at the incision site.

results when done by well trained hands. This study shows a modified SICS where steps like superior rectus, lifting the conjunctival flap and cautery. It has the following advantages.

4.1. Lesser astigmatism

The temporal incision in stab incision SICS has less surgically induced astigmatism than with the original SICS where the incision is superior. In this study it was less than 1D in 83% of cases. The reason for it being the part of the tunnel is scleral, and lack of cautery reduces the fibroblastic reaction and scarring. Flexible incisions can be made to deliver large nucleus. Also, these are self-sealing tunnels not requiring any sutures. Comparatively incision can't be extended in clear corneal complicated phaco.

4.2. Site of incision

The site of the incision is placed superotemporally in the right eye and superonasally in the left eye. The plane of the incision helps in better intraocular manipulation. The tunnel

created is smooth favouring better apposition as it is created by one step incision and second step during extension and the opposing surfaces are smooth as in image 8. The placement of tunnel close to the limbus facilitates easier nucleus delivery.




Fig. 9: Wound construction

4.3. Rigid IOL implantation without suture

A large corneal incision will need suturing and it increases the astigmatism. Whereas RIGID IOL can be planned when limbal incision is made which does not require suturing. It has the advantage of having near equal phaco results with rigid IOL implantation for those with hard cataracts and who can't afford foldable IOL.

4.4. Less bleeding

Bleeding from the limbal vessels is minimal and it does not interfere in surgery as the blood does not enter through the self-sealing tunnel and there is less risk of postoperative hyphema.

5. Conclusion

This modified oblique stab incision SICS can eliminate steps of superior rectus bridle suture, conjunctival flap, cauterisation and their resulting complications. The incision in original SICS is done with the help of four instruments (incision blade, crescent, keratome, extension blade) whereas it requires only a 3.2mm keratome to make a limbal incision and a 5.5 mm extension blade to make the limbal tunnel. This technique is easy and less time

consuming. Although the clear corneal incision provides the benefits of short tunnel length, shorter operative time, better anterior chamber approach, it has the disadvantages of more astigmatism, high chance of infection, if the incision is larger then it requires suture. All this can be eliminated by a direct oblique posterior limbal stab incision where the tunnel length is shorter for better Anterior chamber approach and easy nucleus delivery, shorter surgical duration, and placement of RIGID IOL without sutures. Thereby concluding that this is an easier technique of SICS with equally good results as compared to phacoemulsification.

6. Source of Funding

None.

7. Conflict of Interest

None.

8. References

1. Gogate PM, Kulkarni SR, Krishnaiah S, Deshpande RD, Joshi SA, Palimkar A et al, Safety and efficacy of phacoemulsification compared with manual small-incision cataract surgery by a randomized controlled clinical trial: sixweek results. *Ophthalmol* 2005;112(5):864-869.
2. Ruit S, Tabin G, Chang D, Bajracharya L, Kline DC, Richheimer W et al, A prospective randomized clinical trial of phacoemulsification vs manual sutureless small-incision extra capsular cataract surgery in Nepal. *Am J Ophthalmol* 2007;143(1):32-38.
3. Kimura H, Kuroda S, Mizoguchi N, Terauchi H, Matsumura M, Nagata M et al. Extracapsular cataract extraction with a sutureless incision for dense cataracts. *J Cataract Refract Surg* 1999;25:1275-1279.
4. Bayramlar H, Cekic O, Totan Y. Manual tunnel incision extra capsular cataract extraction using the sandwich technique. *J Cataract Refract Surg* 1999;25:312-315.
5. Sharma RL, and Praveen P. Minimal Duration Cataract Surgery (MDCS)-Small Incision Cataract Surgery (SICS) without superior rectus stitch, no conjunctival flap and no cauterization. *Delhi J Ophthalmol* 2012; 275-278.
6. Oshika T, Sugita G, Tanabe T, Tomidokoro A, Amano S. Regular and irregular astigmatism after superior versus temporal scleral incision cataract surgery. *Ophthalmology*
7. Ozkurt Y, Erdo an G, Güveli AK, Oral Y, Ozba M, Cömez AT et al, Do an OK. Astigmatism after superonasal and superotemporal clear corneal incisions in phacoemulsification. *Int Ophthalmol* 2008;28(5):329-332.

8. SS Haldipurkar, Hasanain T Shikari, and Vishwanath Gokhale. Wound construction in manual small incision cataract surgery. *Indian J Ophthalmol* 2009;57(1):9-13.
9. Ermi SS, Inan UU, Oztürk F. Surgically induced astigmatism after supero-temporal and superonasal clear corneal incisions in phacoemulsification. *J Cataract Refract Surg* 2004;30(6):1316-1319.
10. Earnest P, Tipperman R, Eagle R. Is there a difference in incision healing based on locations. *J Cataract Refractive Surg* 1998;24:482-486.
11. Gokhale NS, Sawhney S. Reduction in astigmatism in manual MSICS through change in astigmatism site. *Indian J Ophthalmol* 2005;53:201-203.
12. Hepsen IF, Cekic O, Bayramlar H, Totan Y. Small incision extracapsular cataract surgery with manual phaco trisection. *J Cataract Refract Surg* 2000;26:1048-1051.
13. Duch Mestres F, Mathieu A, Torres F, Lillo J, Castilla M. Intra-operative complications of planned extra capsular cataract extraction versus manual nucleofragmentation. *J Cataract Refract Surg* 1996; 22: 1113-1115.
14. Sharma RL, Mahajan D, Sharma K. SICS Tunnel Construction with Oblique Limbal Stab Incision and its Effectiveness in Self-Sealing, Nucleus Delivery and Astigmatism-Minimal Duration Cataract Surgery. *J Ocular Dis Ther* 2014;2:55-63.
15. Jaggernath J, Gogate P, Moodley V, Naidoo KS. Comparison of cataract surgery techniques: safety, efficacy, and cost-effectiveness. *Eur J Ophthalmol* 2014 Jul;24(4):520-526.

Author biography

G. Srinivasan Assistant Professor

Sheetal Junior Resident

Cite this article: G. Srinivasan , Sheetal . A comparative study on oblique stab incision sics and phacoemulsification. *Indian J Clin Exp Ophthalmol* 2019;5(4):552-558.