



Original Research Article

Clinical profile of vernal keratoconjunctivitis in a tertiary care hospital

Kishan Makvana^{1,*}¹Department of Ophthalmology, C U Shah Medical College, Surendranagar, Gujarat, India

ARTICLE INFO

Article history:

Received 05-07-2019

Accepted 03-08-2019

Available online 27-11-2019

Keywords:

Allergic eye disease

Vernal keratoconjunctivitis

Gujarat

ABSTRACT

Introduction: This study was carried out to evaluate the clinical profile and epidemiological variants of vernal keratoconjunctivitis in a dry humid region of Gujarat state which is more prone to vernal keratoconjunctivitis.

Materials and Methods: Vernal keratoconjunctivitis is a non-infectious allergic reaction of conjunctiva, also called as spring catarrh, is characterised by bulbar and palpebral conjunctival involvement with characteristic signs and symptoms like redness, itching, burning, ropy discharge. It is more common in pre-pubertal males in spring and summer season. This study was carried out for duration of 12 months at outpatient department, C U Shah medical college, Surendranagar. The patient data were recorded with a specially prepared proforma. Age and gender of the patients were noted. The clinical diagnosis was based upon history and characteristic signs and symptoms of vernal keratoconjunctivitis. Special emphasis was given upon age, first age of presentation, family history of rhinitis, atopy and eczema. An analysis of 112 patients was done.

Results: More than 80% of the examined patients were male, among these 75% of the patients were among the age group of 5 to 10 years of age. More than 80 % patients were from rural areas. Almost half of the patients (50%) were from lower socio economical class. 60% of the patients were having the disease presentation for the first time while the rest were having a recurrent disease. Almost all the patients were having papillae upon bulbar conjunctive while 50% patients were having limbal gelatinization. Characteristic Horner Tranta's spots were present in less than 10% patients. 70 % patients were having perennial presentation and mixed form was the most common disease (75%). Itching and ropy discharge were the most common symptoms (93% and 88% respectively).

Conclusion: The geographical pattern seen in this region is mostly similar to rest of Indian climate with few distinct features like less association with atopy and rhinitis and higher incidence of new cases.

© 2019 Published by Innovative Publication. This is an open access article under the CC BY-NC-ND license (<https://creativecommons.org/licenses/by/4.0/>)

1. Introduction

The allergic reactions of conjunctiva may assume several forms like (1) Seasonal allergic hay fever conjunctivitis (2) Perennial allergic conjunctivitis (3) Vernal keratoconjunctivitis (4) Atopic conjunctivitis (5) Giant papillary conjunctivitis (6) Contact dermatitis-keratoconjunctivitis and (7) Phlyctenular keratoconjunctivitis.^{1,2}

Vernal keratoconjunctivitis is a recurrent bilateral allergic disease of conjunctiva and cornea that is IgE mediated.² It is also called as spring catarrh. The word

vernal stands for the Greek word meaning "occurring in spring".^{2,3} It is a misnomer because it is present throughout the year and more common in summer months.¹⁻³ Duke Elder also suggested the occurrence is more common in summer months rather than spring season.³ This condition is more common in warm and dry climatic conditions. VKC is more common in boys until puberty thereafter the occurrence is equal in both the genders.^[3,4] Some young adults develop more severe manifestation of the disease, sometimes with indefinite recurrences.⁴ About 2/3 of the patients have some form of allergic history and they are more commonly associated with childhood asthma and

* Corresponding author.

E-mail address: kishan_makvana@hotmail.com (K. Makvana).

atopic conditions.⁴ The onset is usually after 5 years of age and it subsides usually after 25 years of age.²⁻⁴

There are three forms of this disease.

1. Bulbar form
2. Palpebral form
3. Mixed form.⁴⁻⁶

The palpebral form shows flat, red, raised polygonal papillae like a cobblestone appearance with bluish white colour. They are hard and made up of dense fibrous tissue with thickened conjunctival epithelium. The limbal form shows opacification, nodules and gelatinous thickening (cupid bow appearance) of the limbus. Characteristic white coloured Horner Tranta's spots made up of eosinophilic and epithelial debris can also be seen at limbus.^{2-4,7} The disease can have a mixed form complicated by appearance of superficial punctate keratitis. The prognosis of the disease is usually good with some individuals developing recurrent disease. The complications/sequel include dry eyes, corneal ulcers (shield ulcers). Thickening and discoloration of the conjunctiva may persist sometimes.⁷⁻¹⁰

The diagnosis of vernal keratoconjunctivitis is usually based upon clinical signs and symptoms mostly but it can be aided by investigations like conjunctival scrapings and presence of eosinophilic infiltrates in it.⁷ Various therapeutic managements are suggested but most of them are for symptomatic relief, the curative therapies are often inadequate.^{8,11,12}

We undertook this study to understand and stress upon the importance of clinical manifestations, to understand geographical variations of the disease and to know about the sequel of the disease and those of long-term medications related complications.

2. Materials and Methods

This is a hospital based prospective cohort descriptive study conducted upon the patients visiting outpatient department of a tertiary care hospital at Surendranagar district, Gujarat. Proper ethical approvals were granted from the institutional ethics committee (human research) before commencing this study. A total of 134 patients were identified during the period of 12 months among of them 22 patients were lost on follow up. A total 112 patients were followed up. The relevant history and clinical examination data were noted on a specially designed proforma. The diagnosis was based upon history, clinical signs and symptoms and slit lamp examination. The chief complaints were itching, ropy mucoid discharge, photophobia and foreign body sensation. Active disease was defined as presence of papillae, cobblestone appearance of palpebral conjunctiva, limbal gelatinization and corneal involvement. Quiescent form was defined as absence of current ocular symptomatology at present.^{2-4,7} Three forms of the diseases

were identified and noted as (A) Bulbar (B) Palpebral (C) Mixed.⁷⁻⁹ The severity of the disease was noted as:

1. Mild
2. Moderate
3. Severe⁷⁻⁹

Complete ocular examinations including visual acuity, subjective correction, slit lamp examination, examination of conjunctiva especially for the signs of VKC like papillae, Horner Trantas spots at limbus with thickening of the conjunctiva and gelatinization of the limbus were done. Cornea was examined for epitheliopathies and shield ulcers. Staining and scraping of corneas were taken where required. Complete cycloplegic refraction was carried out where required. The patients were prescribed medications depending upon the severity of the disease and were followed up at one week interval for a month.

The inclusion criteria were all the patients attending outpatient department with signs and symptoms of vernal keratoconjunctivitis and consenting to the study. Those who do not consent were excluded from the study.

3. Results

This study was carried out at a tertiary care hospital catering mostly rural population in Gujarat state. Total 112 patients were identified and examined among them 94(83%) were male and 18 (16%) were female. The male to female ratio was 5:1. The patients were divided into three categories based upon age. In the first category, age group 5-10 years there were 83 (75%) patients, the second age group was 11-19 years which had 18 (16%) patients while the third age group containing patients older than 20 years of age had 11 (9%) of patients. Among these patients, 83 patients (75%) were from rural areas while 29 patients (25%) were from urban areas. Majority of the patients (47%) were presenting from lower socio-economical class, 36% from middle socio-economical class and 17% were belonging to upper socio-economical class. 65 patients (58%) were having the disease presentation for the first time and 47 patients (42 %) were having a history of previous occurrence of the same disease.

On clinical examination almost all patients (100%) were having papillae on palpebral conjunctiva. Macropapillae were present in 30 % of population. 46 patients (41%) had cobblestone appearance. Horner Tranta's spots were present in 10% patients. Limbal gelatinization was observed in more than half (>50%) of patients. The spring and summer season in total encountered for 31% of the cases compared to the rest of the year (69%). The mixed form was the most common encounter (72%), followed by palpebral form (16%). The frequency of bulbar form was 11%. Symptoms like itching and ropy discharge was present in 93% and 88 % patients respectively. 34% patients complained about foreign body sensation and 25%

patients had photophobia. The occurrence of VKC related complications were asTable 1 .

Majority of the patients had mild disease (63 patients; 56 %) while 32 patients (28%) had severe disease. Associated allergic conditions like eczema (14%), rhinitis (17%), childhood history of asthma (32%) and family history of atopy (35 %) were observed. The most common complication/sequel was corneal scarring (20%). It was followed by corneal neovascularization (17 %). Chronic medication related steroid induced pressure elevation was observed in less than 5% patients.

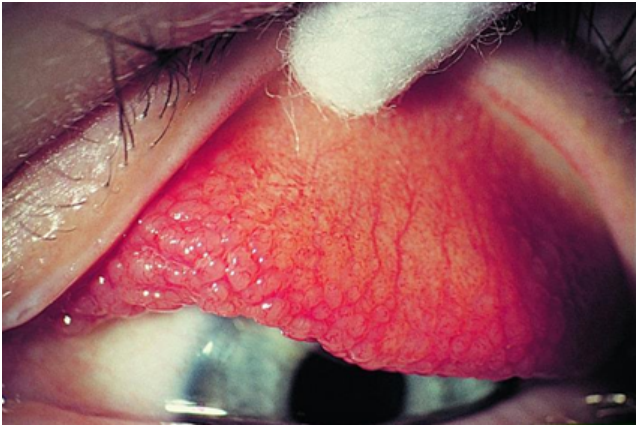

Fig. 1: Palpebral form of vernal keratoconjunctivitis

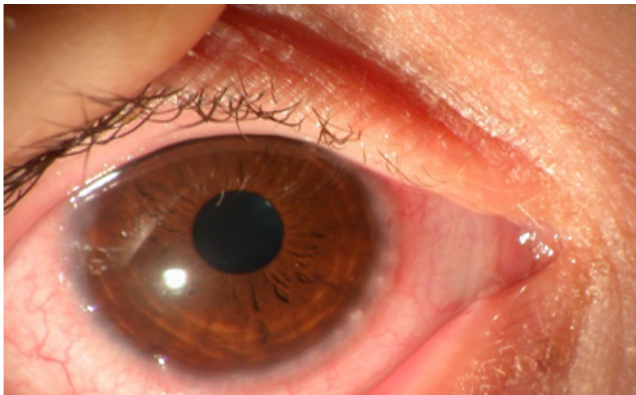
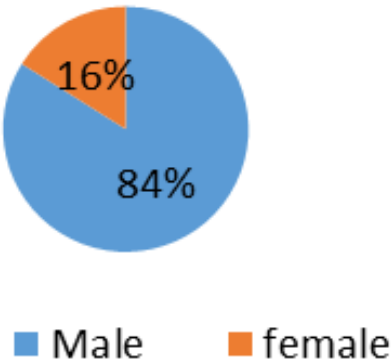


Fig. 2: Bulbar form of vernal keratoconjunctivitis

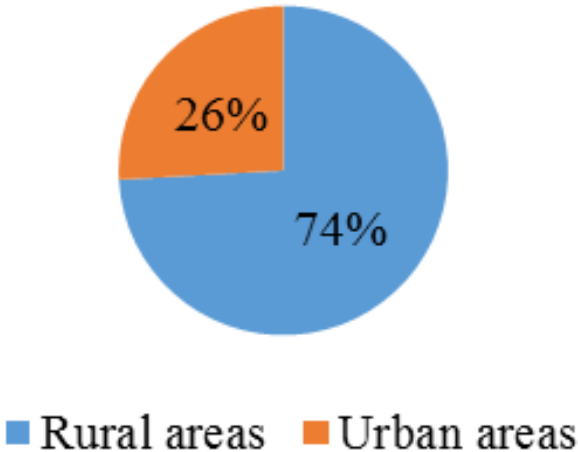
Age group distribution in vernal keratoconjunctivitis
Clinical form distribution

4. Discussion

112 patients were enrolled from outpatient department having clinical signs and symptoms of vernal keratoconjunctivitis. Vernal keratoconjunctivitis is believed to be a childhood disease which is more common in pre-pubertal males and is found to resolve spontaneously at puberty. It is less common below the age of 5 years.^{3,4} This study



Graph 1: Gender distribution in vernal keratoconjunctivitis



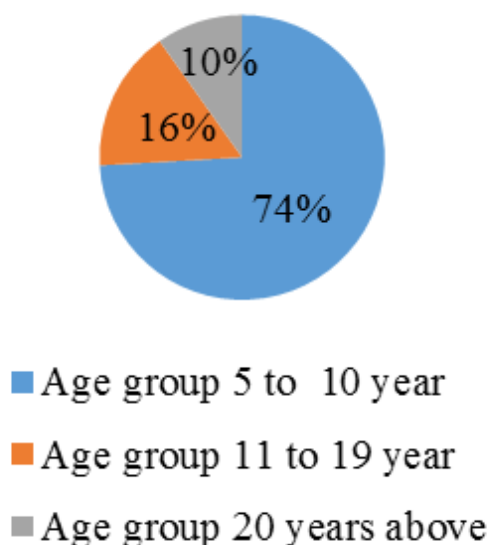
Graph 2: Urban and Rural distribution in vernal keratoconjunctivitis

Table 1: Complications in vernal keratoconjunctivitis

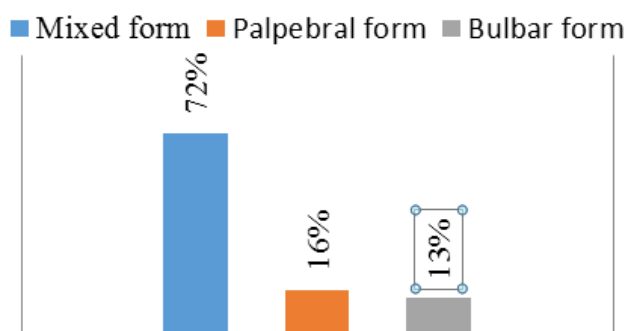
Associated Complication	Percentage of patients
Corneal Scar	20%
Conjunctivization of cornea	17%
Shield Ulcers	10%
Cataract	3%
Glaucoma	5%
Acquired Ptosis	2%
Keratitis	<1%

Table 2: Severity of vernal keratoconjunctivitis

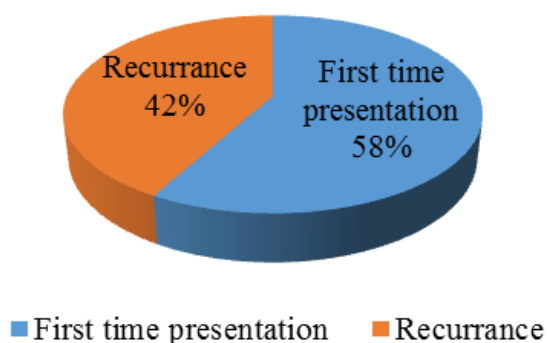
Type of disease	Number of patients
Mild	63(56%)
Moderate	17(16%)
Severe	32(28%)
Total	112



Graph 3: Age wise distribution in vernal keratoconjunctivitis



Graph 4: Clinical Form distribution in vernal keratoconjunctivitis



Graph 5: Recurrence in vernal keratoconjunctivitis

Table 3: Associated Systemic conditions in vernal keratoconjunctivitis

Associated systemic condition	Percentage of patients
Asthma	28%
Rhinitis	15%
Eczema	16%

Table 4: Clinical signs in vernal keratoconjunctivitis

Signs	No of patients
1. Papillae	112(100%)
2. Congested conjunctiva	112(100%)
3. Horner trantas spots	13(11%)
4. Cobble stone appearance	46(41%)
5. Corneal epitheliopathies	9(8%)

Table 5: Symptoms in vernal keratoconjunctivitis

Symptoms	No of Patients
Itching	105 (93 %)
Ropy discharge	98 (88%)
Foreign body sensation	38 (34%)
Photophobia	28 (25%)

shows that the prevalence pattern in tropical areas like Gujarat resembles most of the described Indian subcontinent pattern.

94 patients were male (83%) and 18 patients were female (17%). The youngest patient was of 5 years of age while the oldest patient was of 23 years of age. 9% of patients were above 20 years of age. The male: female ratio was observed to be 5:1. A hospital based study in south India by Saboo et al⁸ found the prevalence in males to be 87 % and the prevalence beyond the age of 20 was 12%, while the male: female ratio was observed to be 6.4:1. An international study by Lambiase and co-workers⁶ found the male: female ratio to be 3.5:1, while another study by Bonini et al^{13–15} measured the male to female ratio as 4:1. An Nigerian study by Ukponmwan and co-workers¹⁶ found the male: female ratio as 1:1.3 whereas Leonardi et al¹⁷ from Italy described it as 3.3:1

An Indian clinical study in Hubli by Jivangi et al¹⁸ and Saboo et al⁸ at South India found to have a mixed disease pattern to be more common (60% and 72% respectively). Whereas a neighbourhood study from Pakistan by Shaikh et al¹⁹ found the palpebral pattern as the most common finding (54%). While an international study series by Bonini et al^{13,14} found out the mixed type to be the most common (48%). This in relation to our study where the mixed pattern is among the most common occurrence (72%), followed by palpebral form and lastly the bulbar form.

Most of the patients were from lower socio economical class (53 %), whereas (17%) patients were from higher socioeconomic class, this is in contrast to Saboo et al⁸ which had higher incidence in higher socioeconomic class

(67%).

Most of the patients presented in the summer months, presenting a chronic perennial form (75%), this is in contrast to the classical name vernal “occurring in spring”. This is in collaboration with the findings suggested by Saboo et al⁸ from south India and Sofi et al¹⁰ at Kashmir where perennial keratoconjunctivitis is more common (36% and 75% respectively). International studies by Lambiase et al^{6,13} suggested the incidence to be higher in summer months rather than spring season (60%).

Majority of the chief clinical presentations were papillae on tarsal conjunctiva (100%), photophobia (25%) and foreign body sensation (34%). Whereas a major Indian clinical study by Saboo et al⁸ measured the incidence of papillae (86%), photophobia (29%) and foreign body sensation (45%).

Family history of asthma was present in 28% patients, whereas family history of rhinitis and eczema was present in 15% and 14 % patients respectively. A study by Shaikh et al⁹ from Pakistan had the same outcomes (Family history of asthma 24% patients, history of rhinitis 25%), this is in contrast with a study by Saboo et al⁸ which showed 5% incidence of family history of allergic diseases which might be due to high temperate zone of our region.

Significant complications due to disease were corneal scarring (20%) and conjunctivization of cornea (17%) that is in line with the data reported by Saboo et al⁸ and Shaikh et al.⁹

Treatment related complication like cataract and steroid induced glaucoma was seen in 3% and 5% patients respectively. Saboo et al⁸ reported the incidence of cataract and steroid induced glaucoma to be 6 % & 3 % patients respectively.

In summary, typical clinical features of vernal keratoconjunctivitis were observed in this study like typical pre pubertal incidence and relevance after puberty with typical male to female ratio. The disease is self-limiting after puberty. Mixed pattern was the most common occurrence and patients with history of allergy/atopy are more prone to develop vernal keratoconjunctivitis.

5. Source of Funding

Not applicable.

6. Conflict of Interest

None.

References

1. Albert DM, Jakobiec FA, Abelson MB, Duell IJ, Mathea RA, Raizmain MB. Allergic and toxic reactions. Principles and practice of ophthalmology, Philadelphia; WB Saunders ; 1994.
2. Sihota R, Tandon R, Parsons J. Parsons' diseases of the eye. Elsevier India ; 2011,. 21st edition.
3. Duke-elder S. Diseases of the outer eye, part 1, Duke-elder, System of ophthalmology. London. 1965: p 476 ;. .
4. Kanski JJ. Disorders of the conjunctiva: Vernal keratoconjunctivitis. Clinical Ophthalmology. 1999, 4th edition, p 66-71.;
5. Power WJ, Tugal-Tutkun I, Foster CS. Long-term follow-up of patients with atopic keratoconjunctivitis. *Ophthalmol.* 1998;105(4):637–642.
6. Lambiase A, Bonini S, Marchi S, Pasqualetti P, Zuccaro O, Rama P. Vernal keratoconjunctivitis revisited: a case series of 195 patients with long term follow up. *Ophthalmol.* 2000;107(6):1157–1163.
7. Bisht A, Singh G, Sharma V, Sharma T. Clinico immunological aspects of vernal catarrh in hilly terrains of himanchal Pradesh. *Indian J Ophthalmol.* 1992;40:79–82.
8. Saboo US, Maniash J, J R, Sangwan VS. Demographic and clinical profile of vernal keratoconjunctivitis at a tertiary eye care center in India. *Indian J Ophthalmol.* 2013;61(9):486–489.
9. Shafiq I, Z S. Clinical presentation of vernal keratoconjunctivitis (VKC): A hospital based study. *J Liaquat Univ Med Health Sci.* 2009;8:50–54.
10. Sofi RA, Mufti A. Vernal keratoconjunctivitis in Kashmir: A temperate zone. *Int Ophthalmol.* 2016;36:875.
11. Smith JS. Diseases of conjunctiva: Eye diseases in hot climates. Oxford; Butterworth Hieneman, 2001, 3rd edition, p 83-104 ;. .
12. Gormaz A, Eggers C. Vernal keratoconjunctivitis and keratoconus. *Am J Ophthalmol.* 1984;96(4):555–556.
13. Bonini S, Cosssin M, Aronni S, Lambiase A. Vernal Keratoconjunctivitis. *Eye(Lond).* 2004;18(4):345–351.
14. Bonini S, Sacchetti M, Mantelli F, Lambiase A. Clinical grading of vernal keratoconjunctivitis. *Curr Opin Allergy Clin Immunol.* 2007;7(5):436–441.
15. Bonini S, Lambiase A, Sgrulletta R ; 1993,.
16. Ukponmwan CU. Vernal Keratoconjunctivitis in Nigerians: 109 Consecutive Cases. *Tropical Doctor.* 2003;33(4):242.
17. Leonardi A, Busca F, Motterle L, Cavarzeran F, Fregona I, et al. Case series of 406 vernal keratoconjunctivitis patients: a demographic and epidemiological study. *Acta Ophthalmol Scand.* 2006;84:406–410.
18. Jivangi V, Raikar H, Khatib Z, Abhilasha MN, Suhana A. Clinical profile of patients with vernal keratoconjunctivitis. *Int J Res Med Sci.* 2015;3(10):2831–2834.
19. Shaikh A, Ovais SM. The morbidity of vernal keratoconjunctivitis. *Pak J Ophthalmol.* 2001;3:86–89.

Author biography

Kishan Makvana Assistant Professor

Cite this article: Makvana K. Clinical profile of vernal keratoconjunctivitis in a tertiary care hospital. *Indian J Clin Exp Ophthalmol* 2019;5(4):496-500.