



## Original Research Article

# Comparative study of pterygium surgery by conjunctival advancement flap with sutures versus graft on autologous serum

Mukaram Khan<sup>1</sup>, Deepali Gawai<sup>1</sup>, Smita Taur<sup>1,\*</sup>, Ketaki Shah<sup>1</sup>

<sup>1</sup>Dept. of Ophthalmology, Shri Bhausaheb Hire Government Medical College, Dhule, Maharashtra, India



## ARTICLE INFO

## Article history:

Received 06-09-2019

Accepted 17-09-2019

Available online 27-11-2019

## Keywords:

Conjunctival advancement flap

Autologous graft

Pterygium

## ABSTRACT

**Aim:** To compare the surgical outcomes of pterygium by conjunctival advancement flap with sutures versus graft on autologous serum in terms of graft stability, post operative inflammation and recurrence.

**Materials and Methods:** A prospective study to compare and analyze 114 cases of pterygium surgery, a conjunctival advancement flap with sutures was done in 47 cases, while graft on autologous serum done on 60 cases, in 7 cases bare sclera kept.

**Results:** Good stability of conjunctival flap and minimal inflammation was seen in advancement flap with sutures. While no inflammation, good acceptance but few cases of graft instability was seen in graft on autologous serum, and the recurrence was comparable in both the studies.

**Conclusion:** Efficacy, safety and cost effectiveness is good with both the procedures but the stability is better with advancement flap with sutures and better acceptance of graft with least inflammation in graft on autologous serum group. However recurrence rate is comparable in both the procedures.

© 2019 Published by Innovative Publication. This is an open access article under the CC BY-NC-ND license (<https://creativecommons.org/licenses/by/4.0/>)

## 1. Introduction

Pterygium is a growth onto the cornea, usually nasally, of fibrovascular tissue that is continuous with the conjunctiva. It occurs in the palpebral fissure area, much more often nasally than temporally, although either or both ("double" pterygium) occur.<sup>1</sup> Pterygium is associated with ultraviolet light exposure. It occurs at highest prevalence and most severely in tropical areas near the equator and to a lesser and milder degrees in cooler climates.<sup>2,3</sup> Both blue and ultraviolet light have been implicated in its causation, as demonstrated in watermen.<sup>2</sup> Pterygium needs to be treated when they encroach upon the visual axis, induce significant regular or irregular astigmatism, or become cosmetically bothersome. The primary aim of pterygium surgery is to excise the pterygium and prevent its recurrence. For small pterygium simple excision of the pterygium on the cornea and sclera is sufficient but for the large pterygium the goal of treatment is to prevent

recurrence. Surgeries such as autologous conjunctival graft, amniotic membrane or the advancement flap are well established but the recurrence remains to be the problem. Recurrence after simple excision with bare sclera is high and that of with graft is minimal so several studies showed minimal recurrence with autoconjunctival graft and amniotic membrane graft but amniotic membrane is not cost effective and autoconjunctival graft done at the cost of excision and grafting of a considerable portion of normal healthy conjunctiva and limbal cells which is retrieved usually from the superior part of bulbar conjunctiva which is the preferred site of glaucoma filtration surgery like trabeculectomy and the presence of a normal superior conjunctiva is a very important factor determining the success of a glaucoma filtration surgery.<sup>4</sup> There were radical surgeries with a purported recurrence rate near 0 %, such as "Pterygium Extended Removal Followed by Extended Conjunctival Transplant" (PERFECT), have recently been introduced.<sup>5,6</sup> However, these radical procedures have not been popularized due to the extensive labor involved and the complexity of

\* Corresponding author.

E-mail address: [smitataur@gmail.com](mailto:smitataur@gmail.com) (S. Taur).

the technique.<sup>5,6</sup> The aim of our study is to find the effectiveness of the conjunctival advancement flap with sutures, a technique to treat the Pterygium, saving the normal conjunctiva for the future glaucoma surgery if needed and compare the surgical outcome with graft on autologous serum.

## 2. Aim

1. To study the stability, recurrence rate and inflammation of the extended conjunctiva following subconjunctival excision of pterygium by conjunctival advancement flap with sutures technique and compare these results with conjunctival graft on autologous serum.
2. To compare the results of above 2 techniques, in terms of efficacy, cost effectiveness and structural stability.

## 3. Materials and Methods

This was a prospective study to compare and analyse 114 cases of nasal pterygium at the Department of Ophthalmology of Shri Bhausaheb Hire Government Medical College Dhule, during a period of June 2018 to June 2019.

Approval from the institutional ethical committee was obtained prior to study. Patients with primary progressive nasal pterygium from grade 1 to 4 were included and patients with Conjunctival masses mimicking pterygium such as ocular surface squamous neoplasia (OSSN), pseudopterygium and recurrent pterygium were excluded from our study. The clinical characteristics of the pterygium were classified using a modified classification system<sup>7</sup>. It considers the length of corneal involvement (stage), vascularity and tissue thickness (corneal and conjunctival part) of pterygium.

Patients were explained about the procedure and an informed written consent was obtained from the patients. After a thorough history examination was done, which included visual acuity (BCVA), slit lamp examination of pterygium along with grading and remaining anterior segment, posterior segment, measurement of intraocular tension. Base line investigations such as Hemogram, random blood sugar, HIV, HBsAg, ECG were done and a fitness for surgery was obtained. All surgeries were performed with specific technique.

In advancement flap procedure local subconjunctival infiltration anesthesia was given. The eye was painted, draped and eye speculum inserted. The body of Pterygium was meticulously excised taking care of the underlying medial rectus muscle. The pterygium head was meticulously separated from the underlying cornea using a Crescent blade or No. 15 Bard-Parker blade. After the entire pterygium was freed from the ocular surface, the pterygium body and conjunctiva were excised. Haemostasis

**Table 1:** Clinical classification of pterygium

### Stage (S)

1. Corneal invasion less than 1 mm
2. Corneal invasion 1–2 mm
3. Corneal invasion 2–3 mm
4. Corneal invasion more than 3 mm

### Vascularity (V)

1. Minimal visible vessel equal to conjunctiva
2. Moderate vascularity more dense than conjunctiva
3. Severe vascularity with vessel congestion

### Conjunctival tissue thickness (C)

1. Flat tissue
2. Minimally elevated tissue
3. Tissue elevation up to 1 mm
4. Tissue elevation over 1 mm

### Corneal tissue thickness (K)

1. Flat tissue
2. Minimally elevated tissue
3. Tissue elevation up to 1 mm
4. Tissue elevation over 1 mm

was obtained. The overlying conjunctiva was then dragged over the bare sclera and was secured at the limbus with preferably single 10-0 nylon suture, double sutures if needed. Following the procedure, patients were advised to administer antibiotic and prednisolone eye drop 6 times daily in the first week tapered gradually over 4 weeks. Lubricating eye drops (Hydroxypropyl methylcellulose) 4 times daily and Lubricating eye ointment two times a day for 1 month.

In conjunctival graft on autologous serum the peribulbar block given, graft was taken from superior or superotemporal quadrant of conjunctiva, limbus to limbus graft placement was done, graft is then secured with the help of autologous serum and blood. Post operative medication and follow up was same as that of advancement flap with suture.

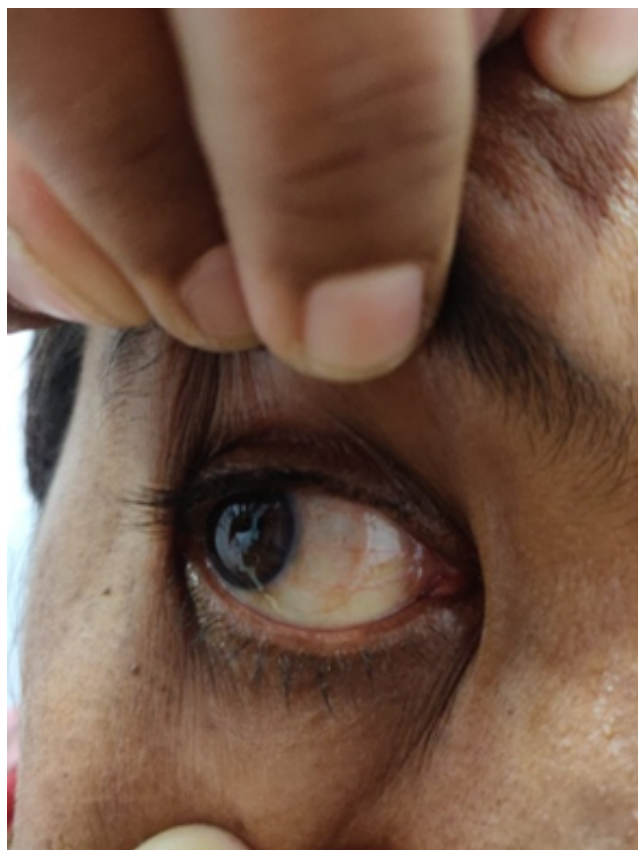
Patient was followed up at 1 week, 1 month, 3 months and 6 months, during follow up visits, Stability of overlying conjunctiva, inflammation and evidence of recurrence were recorded. Recurrence of pterygium was monitored, Grade 1 to 3 (Table 1) were considered as “no-recurrence” and grade 4 (Table 1) was considered as “recurrence”.

## 4. Results

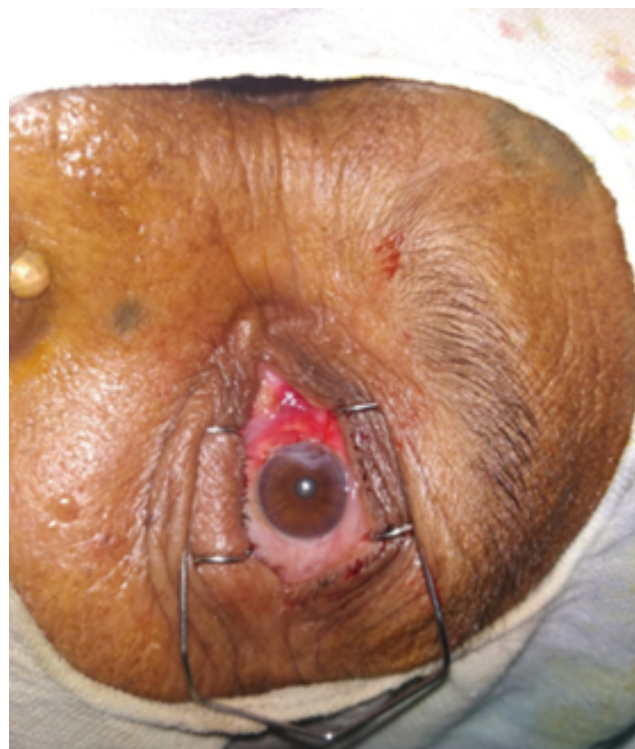Out of 114 patients, 47 patients undergone advancement flap with sutures, 60 patients undergone conjunctival graft on autologous serum while 7 patients had undergone bare sclera technique.

Out of 114 patients no significant difference in sex distribution 61 were females, 53 were males, as shown in figure 2.

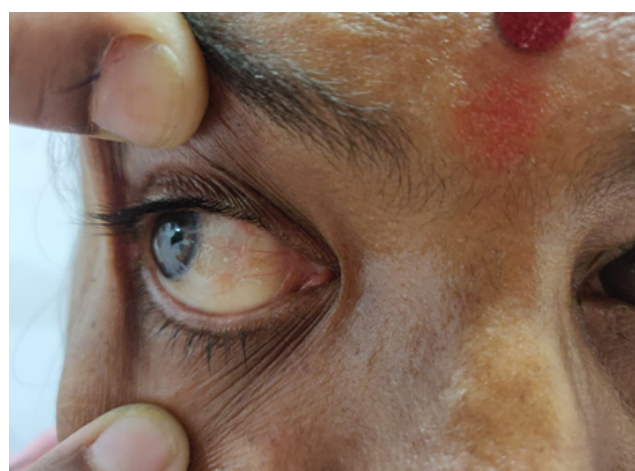Maximum number of the patients belonged to 40 to 60 years of age group that is 80 patients (70%), 15 patients were between 20- 40 years age group (13.15%)



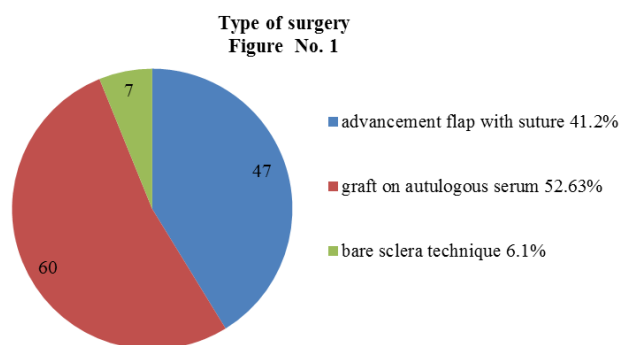
**Fig. 1:** Showing graft oautologous serum – good acceptance of graft



**Fig. 2:** Showing advancement flap with suture.



**Fig. 3:** Showing 3 month follow up of advancement flap, good acceptance



**Graph 1:** Showing type of pterygium surgery patient had undergone

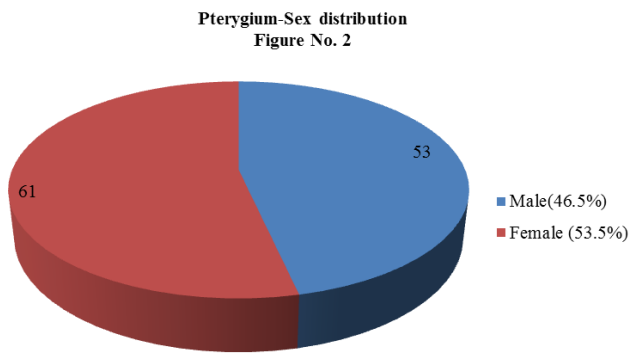
and 19 patients were between 60 years and above age group(16.6%). None of the patient was less than 20 years old (0%)

**Extent of corneal involvement-** Among 114 patients 12cases(10.52%) had less than 2mm corneal involvement 40 cases (35.08%) had 2mm to 3mm corneal involvement 53 cases (46.5%) had 3mm to 4mm corneal involvement 9 cases (7.9%) has more than 4mm corneal involvement

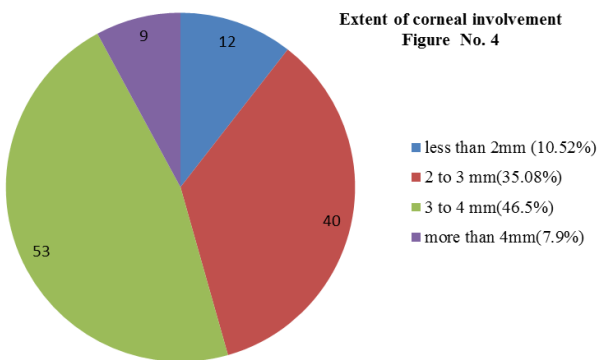
During 6 month follow up of all 114 patients

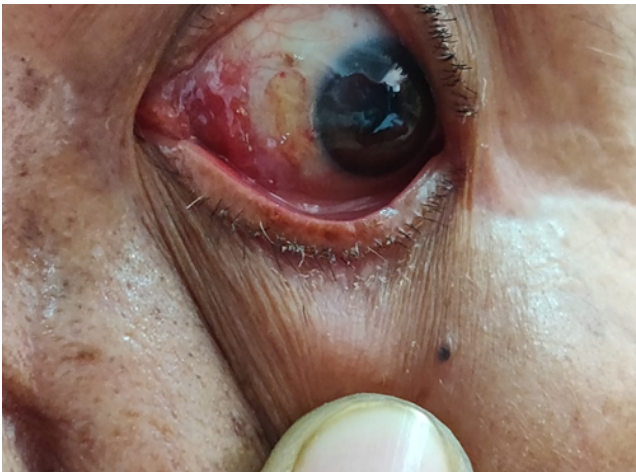

Fig. 4: Showing graft displacement in autologous serum.



Graph 2: Showing sex distribution of pterygium



Graph 3: Showing extent of corneal involvement

Among 47 patients of advancement flap with sutures – None of the patient had displacement of the flap so the post operative stability was very good with this group of patients. Post operative Suture sight inflammation and irritation was found in 9(19.14%) patients of this group which was significant as compared to the other group and one patient (2.12%) had recurrence of pterygium following this procedure.

**Table 2:** Showing comparison between two types of pterygium surgery

S. No	Findings	Advancement flap	Grafton Autologous Serum
1	Graft Instability	0(0%)	7 (11.6%)
2	Postoperative inflammation	9(19.14%)	2(3.33%)
3	Recurrence	1(2.12%)	1(1.66%)

Among 60 patients of graft on autologous serum – Graft displacement was found in 7(11.60%) cases ,stability is lesser with this group. One patient had tenons cyst/granuloma fo rmation at the site from where graft was taken and one patient had recurrence (1.66%). Post operative inflammation and irritation was found in only 2 cases out of 60

Among 7 patients who had undergone bare sclera technique- 3 patients had recurrence. None had post operative inflammation and irritation

5. Discussion

According to our study pterygium is most common in age group of 40 to 60 years that is 80 patients (70%) and majority of patients were females-61(53.5%), While 53(46.5%) patients were males this results are comparable with the study conducted by Chen CL et al<sup>8</sup> in their study, incidence was higher in the age group of more than 40 years and the risk increases as the age increases along with female preponderance of 64%.

In our study the recurrence rate is very comparable, following conjunctival advancement flap with suture it is 2.12% while that of following conjunctival graft on autologous serum is 1.66%. As stated in Toker E et al, none of the surgical technique is best without the risk of recurrence. Soo Hyun Kwon et al<sup>9</sup> in their study describes the recurrence pattern of pterygium after excision with conjunctival autografting as of 12.1% with 3 different mor phologic patterns as regrowth over the epithelial defect, transformation of the conjunctival graft into the pterygial tissue, regrowth from remaining pterygial tissue. Pterygium consist of epithelium which shows minimal abnormality except at the head of pterygium where there can be stratified squamous change, the main pathology is at the level of stroma where the connective tissue shows



fibrinoid changes.<sup>10</sup> Hence to preserve the epithelium over the pterygium doesn't contribute to recurrence as it is histologically normal and a meticulous removal of the subepithelial connective tissue and stroma almost eliminates the pathology. Similarly we suggest that the thorough dissection and excision of subconjunctival tissue will reduce the recurrence rate. Post operative suture sight inflammation and irritation was found in our study which can be eliminated with the use of soft bandage contact lens es as it was done in Kim et al<sup>11</sup>

In conjunctival autografting mainly superior conjunctival graft is harvested which is the site for glaucoma filtration surgery if needed in future. It is a major disadvantage, so in glaucoma suspected patients advancement flap can be a choice of surgery. Shrestha A et al<sup>12</sup> and Syam PP et al.<sup>9</sup> also suggested the same findings as of our study.

However the other drawback of obtaining healthy conjunctiva from elsewhere can lead to conjunctival scarring, risk of symblepharon, tenons cyst formation, granuloma formation at the site of removal of normal conjunctiva etc. subconjunctival excision of pterygium with conjunctival advancement flap prevents such donor site related complications and moreover the superior conjunctiva is left intact so as to preserve the glaucoma filtration site. In our study graft instability was found in graft on autologous serum of 7 cases (11.6%) and it was comparable with the study performed by Sumita Karandikar et al, they have three cases (15%) of graft on autologous serum, showing graft retraction and needed secondary intervention, also they stated that. graft stability was least in autologous serum group.<sup>13</sup>

## 6. Conclusion

Pterygium excision by Conjunctival advancement flap with sutures is indicated in glaucoma patients and glaucoma suspects, it is cost effective and less time consuming technique to treat pterygium. Technical ly it is easier as compared to graft on autologous serum. It is a good technique where incidence of pteygium is more. However persistent redness, inflammation, itching following surgery are limitations of the study. It saves the normal superior conjunctiva for glaucoma filtration surgery. The recurrence rates are comparable to the current management methods like conjunctival autografting. Post operative stability is good, no graft displacement seen.

## 7. Conflict of Interest

None

## References

1. Conjunctival Degenerations Qais A. Farjo and Alan Sugar. Yanoff ;.
2. Taylor HR, West S, Munoz B. The long-term effects of visible light on the eye. *Arch Ophthalmol*. 1992;110:99–104.
3. Mackenzie FB, Hirst LW, Battistutta D, Green A. Risk analysis in the development of pterygia. *Ophthalmol*. 1992;99:1056–1061.
4. Acharya P, Parvathy PS, Kavitha CV, Renuka SK. Pterygium excision with conjunctival advancement technique: A clinical study. *Indian J Clin Exp Ophthalmol*. 2019;5(2):232–235.
5. Recurrence and complications after 1000 surgeries using pterygium extended removal followed by extended conjunctival transplant. *Ophthalmol*. 2012;119(11):2205–2210.
6. Cornelius CR. Recurrence rate and complications of Pterygium extendedremoval followed by extended Conjunctival transplant. *Cornea*. 2017;36:101–103.
7. Park CY, Choi JS, Lee SJ, Hwang SW, Kim EJ, Chuck RS. Cyclooxygenase-2 expressing macrophages in human pterygium co-express vascular endothelial growth factor. *Mol Vis*. 2011;17:3468–3480.
8. Chen CL, Lai CH, Wu PL, Wu PC, Chou TH, et al. Recurrence after Primary Pterygium Excision: Amniotic Membrane Transplantation with Fibrin Glue versus Conjunctival Autograft with Fibrin Glue. *Curr Eye Res*. 2015;41:1–8.
9. Kwon SH. Analysis of Recurrence Patterns Following Pterygium Surgery With Conjunctival Autografts ; 2015,.
10. Shrestha A, Shrestha A, Bhandari S. Inferior conjunctival autografting for pterygium surgery: an alternative way of preserving the glaucoma filtration site in far western Nepal. *Clin Ophthalmol*. 2012;6:315–324. (NZ).
11. Kim. *BMC Ophthalmology* . 2017;17. Available from: [187DOI10.1186/s12886-017-0587-z](https://doi.org/10.1186/s12886-017-0587-z).
12. Syam PP, Eleftheriadis H, Liu CS. Inferior conjunctival autograft for primary pterygia. *Ophthalmol*. 2003;110(4):806.
13. Karandikar S, Shanbhag N, Bhatt N, Chen L. Comparison of three different techniques for fixation of conjunctival autograft in pterygium surgery. *Indian J Clin Exp Ophthalmol*. 2016;2(4):350–355.

## Author biography

**Mukaram Khan** Associate Professor

**Deepali Gawai** Associate Professor

**Smita Taur** Senior Resident

**Ketaki Shah** Assistant Professor

**Cite this article:** Khan M, Gawai D, Taur S, Shah K. Comparative study of pterygium surgery by conjunctival advancement flap with sutures versus graft on autologous serum. *Indian J Clin Exp Ophthalmol* 2019;5(4):477–481.