



Original Research Article

One year study of complications of cataract surgery in pseudoexfoliation syndrome in rural area (Eye camps)

Punit Singh^{1,*}, Deepak Patel¹

¹Dept. of Ophthalmology, SBKS Medical Institute & Research Center, Gujarat, India



ARTICLE INFO

Article history:

Received 29-11-2018

Accepted 09-09-2019

Available online 27-11-2019

Keywords:

Pseudoexfoliation

Cataract

Secondary glaucoma

ABSTRACT

Pseudoexfoliation is a ubiquitous syndrome which is of multifactorial origin affecting elderly people by increasing the risk of cataract and secondary glaucoma development. Despite modern techniques and technologies for cataract surgery, pseudoexfoliation syndrome represents a challenge for surgeons because of the increased weakness of the zonular apparatus and limited pupil dilation. Due to the inherent difficulties during surgery, there is the risk of vitreous loss in these patients which is several times higher than in cataract patients without pseudoexfoliation. Using currently available surgical devices like ophthalmic viscosurgical device, iris retractors and ring dilators, capsular tension ring, etc., the risk of intraoperative complications may be much reduced, allowing the surgeon to handle difficult cases with greater confidence and safety. This review analyzes the methodologic approach to the patient with zonular laxity with the aim of providing useful advices to limit the risks of intraoperative and postoperative complications. From the preoperative planning, to the intraoperative management of the small pupil and phacodonesis, and to the postoperative correction of capsule phimosis and intraocular lens dislocation, a step approach to the surgical management of pseudoexfoliation patients is illustrated.

© 2019 Published by Innovative Publication. This is an open access article under the CC BY-NC-ND license (<https://creativecommons.org/licenses/by/4.0/>)

1. Introduction

Pseudoexfoliation disorder is a turmoil which is multifactorial, hereditarily decided, age-related and ecologically impacted. It is of elastic fiber structure, described by extreme generation and collection of an elastotic material inside a multitude of intra and extraocular tissues.¹ Pseudoexfoliation disorder is a diffuse disease with visual and fundamental signs dependent on the age of the patient.

Later hereditary examinations have shown the lysyl oxidase-like 1 (LOXL1) quality, in charge of a chemical that blends and keeps up versatile strands, is a noteworthy supporter of the danger of creating pseudoexfoliation syndrome.² Hazard factors for creating pseudoexfoliation disorder include:

1. Age
2. Family history

3. Female gender

4. Geographic areas of residence³

Inside the eye, PXF material is found on lens capsule, iris pigment epithelium, iris stroma, iris blood vessels, pupillary margin, zonular fibres, ciliary processes, trabecular meshwork, and the corneal epithelium.^{4,5} Pseudoexfoliation disorder can display singularly and additionally reciprocally and is related with open and restricted point glaucomas and furthermore development of cataracts.^{6,7}

It is likewise viewed as that modifications in the iris vasculature and blood-fluid obstruction could influence the arrangement of watery, which could in this way influence focal point digestion, bringing about prior waterfall formation.^{8,9}

Pseudoexfoliation (PXF) disorder is a turmoil portrayed by the affidavit of unmistakable fibrillar material in the front fragment of the eye.

Not exclusively is PXF related with the arrangement of thick atomic waterfalls, it is additionally observed that those

* Corresponding author.

E-mail address: punitsinghdr@yahoo.com (P. Singh).

giving PXF have a higher danger of creating difficulties amid, and even after, waterfall surgery.^{10,11}

Complications related to cataract surgery in PXF can occur from:

1. Poor pupillary dilation,
2. Zonular weakness followed by intraoperative or postoperative lens dislocation and vitreous loss,
3. Postoperative intraocular pressure (IOP) causing glaucomatous damage,
4. Capsular phimosis,
5. Prolonged inflammation,
6. Postoperative corneal decompensation.^{12,13}

Alongside age, pseudoexfoliation disorder (PXF) speaks to an autonomous extra danger for the improvement of atonic sclerosis and sign for waterfall surgery.^{14,15}

PXF disorder is a multifactorial, hereditarily decided, age-related and naturally impacted turmoil of the flexible fiber structure, described by exorbitant creation and gathering of an elastotic material inside a large number of intra and extraocular tissues.

Hence, PXF is a diffuse infection with visual and foundational signs.^{16,17}

Pseudoexfoliation is analyzed by the statement of white, "dandruff-like", soft material, practically in every one of the structures of the human eye, including the foremost fragment: corneal endothelium, front case, focal point zonules, iris, and trabecular meshwork.

The material is comprised of amyloid, laminin, versatile filaments, collagen, and storm cellar film. A similar material found in the visual tissue has been found in different parts of the human body, for example, heart, lung, liver, kidney, cerebral meninges, and veins, indicating the way that PXF is a multiorgan malady.

This gives clarification that why patients with visual PXF may exhibit a background marked by foundational hypertension, stomach aorta aneurysm, angina, cardiovascular illness, and stroke. Yet at the same time, future does not vary between people with and without PXF.^{18,19}

The foundational root of the infection demonstrate that why patients with one-sided contribution show PXF signs in the typical individual eye at a later time, showing that PXF is a summed up, two-sided clutter with a uniquely hilted clinical introduction at beginning. Patients with one-sided indications of the ailment are typically observed to be more youthful than those with reciprocal inclusion.

The analysis of PXF is of vital hugeness as this illness is a noteworthy hazard factor for entanglements amid waterfall medical procedure and the most regular reason for optional glaucoma.¹⁸

Intraoperative and postoperative entanglements may emerge from the debilitated case and zonular mechanical assembly (zonulopathy because of the dynamic proteolytic breaking down of the suspensory tendon, that is in

charge of the shakiness of the crystalline focal point amid medical procedure, capsular burst, zonular dialysis, vitreous misfortune, atonic luxation, decentration or separation of the intraocular focal point (IOL) with time.

Further challenges amid medical procedure are caused because of poor or lacking understudy enlargement (iridopathy), as a sequelae to atrophic changes of the iris sphincter and stroma described by transillumination surrenders.

Postoperative foremost chamber aggravation and fibrous response watched ordinarily in PXF patients because of an obtained debilitated blood-watery obstruction.

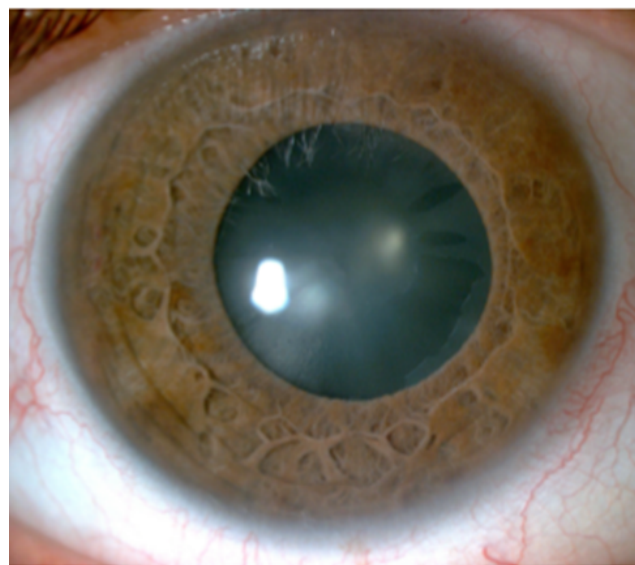


Fig. 1: Site lamp photograph showing signs of cataract and pseudexfoliation.

Note: The lens surface shows sign of exfoliating fibrillar material with accumulation of whitish flakes at the pupillary margin. The pupil is only moderately dilated after pharmacological mydriasis.

Corneal endothelial morphological and practical changes (endotheliopathy) are seen in eyes influenced with PXF, portraying the more prominent powerlessness of these eyes to careful injury, prompting brief and perpetual corneal decompensation.¹⁹ These days, because of current machines and careful methods, there is a huge increment in the certainty toward the careful methodology and agent the board of PXF cases; be that as it may, the higher risk of entanglements with medical procedure still proposes the requirement for more prominent ability and careful aptitude for these patients.²⁰

2. Objectives

1. To study the complications of cataract surgery in pseudoexfoliation syndrome in rural area (eye camps)
2. Preventive measures during cataract surgery.

3. Materials and Methods

3.1. Source of data

Patients admitted with cataract and pseudoexfoliation at R.L.J. Hospital And Research Centre, Tamaka, Kolar Attached To Sri Devraj Urs Medical College between July 2009 and July 2010. After satisfying all inclusion and exclusion criteria of the study and after giving voluntary written consent to participate in the study, there were total 50 cases of acquired cataract has been enrolled in the study.

All patients underwent manual small incision cataract surgery after detailed investigation under peribulbar anaesthesia and PCIOL implanted. Intraoperative complications were noted during surgery.

Preventive measures (large capsulorhexis, minimum hydroprocedure and rotation of nucleus, meticulous wash, careful implantation of lens with minimum dialing) were taken during cataract surgery.

3.2. Inclusion criteria

1. Both Gender with age between of 40 – 80 years
2. Patients with pseudoexfoliation syndrome.
3. Patients of senile cataract.

3.3. Exclusion criteria

1. Other types of acquired cataract like metabolic, traumatic, complicated cataract etc.
2. Patients of pseudoexfoliation syndrome with previous ocular surgery.

4. Discussion

Pseudoexfoliation and large-incision extracapsular cataract extraction

Vast entry point extracapsular waterfall extraction has been connected with numerous difficulties amid medical procedure in PXF eyes. One planned investigation including Portuguese patients found that PXF eyes had an altogether littler student measurement after pharmacologic widening (48.4% versus 9.7%, $p=0.001$) and furthermore an expanded danger of phacodonesis (16.1% versus 0%, $p=0.05$) when contrasted with non-PXF eyes.^{21,22}

In PXF eyes experiencing extracapsular waterfall extraction medical procedure, proof that underpins the finding that anomalous blood-fluid boundary can be found in a few investigations demonstrating the postoperative pupillary fibrin films were more oftentimes present in PXF eyes than in controls.²³

These equivalent examinations depict an expansion in provocative reaction in PXF eyes experiencing extracapsular waterfall extraction. A few examinations looking at intricacy rates between extracapsular waterfall extraction and phacoemulsification in PXF eyes, demonstrate a lower

difficulty rate in those eyes experiencing phacoemulsification versus extracapsular waterfall extraction.^{23,24}

In any case, phacoemulsification has been related with an expanded rate of vitreous misfortune and capsular and zonular tears in PXF eyes in contrast with non-PXF eyes. PXF waterfalls are harder and require more phacoemulsification time. Besides, while there are a few examinations identified with this however these investigations do bar instances of stamped preoperative phacodonesis and focal point subluxation.²⁵

Pseudoexfoliation and poor pupillary dilation

Intraoperative mydriasis can be restricted in PXF by methods for a few instruments. PXF material amassed inside the iris stroma can prompt iris decay, store inside iris blood vessels, or penetrate the iris stroma prompting mechanical block obstructing mydriasis.^{26,27}

Grip of shedding material to the iris color epithelium and front focal point container will prompt mechanical confinement of pupillary developments. These components relate to the formation of a littler than wanted constant curvilinear capsulorhexis, leaving officially debilitated zonules increasingly vulnerable to awful powers of intraocular control while amid surgeries.^{28,29}

The expansion of preoperative topical nonsteroidal calming medications to topical mydriatics have appeared to be of incredible help to limit intraoperative miosis.

4.1. Bimanual extending finished with:

Y-snare, iris retractor snares, and student dilator rings can likewise be utilized to keep up satisfactory mydriasis amid phacoemulsification.³⁰

Viscomydriasis is another procedure used to increment pupillary distance across amid waterfall medical procedure. Despite the fact that any strategy is utilized, in any case, care ought to be taken to not overstretch the student, as this may prompt a sporadic atonic understudy postoperatively.^{31,32}

Pseudoexfoliation and zonular weakness

The statement of the fibrillar material in the turmoil of PXF, can prompt proteolytic breaking down of the zonules, which can prompt shortcoming and their unconstrained fracture.

Clinical signs demonstrates zonular shortcoming incorporate focal point subluxation, phacodonesis, slender iridocorneal edge, and foremost chamber asymmetry. Another method includes evaluating front chamber profundity and looking at chamber profundities between a patient's two eyes recommending an unpretentious focal point disengagement, as hindered zonular dependability can prompt front or back separation, bringing about a progressively shallow or profound chamber, respectively. In an investigation, Kuchle et al. demonstrated that patients with PXF who had a focal front chamber profundity of under 2.5 millimeters had a four-times higher hazard (13.4% versus 2.8%) of intraoperative difficulties, for example,

zonular dialysis and vitreous misfortune ($p=0.013$).

Concentrates likewise demonstrate that over the top focal point development or capsular wrinkling amid the capsulorhexis can show zonular shortcoming too. A very much focused capsulorhexis of about 5.0 – 5.5 millimeters is fundamental within the sight of zonular shortcoming, which might be hard to accomplish within the sight of PXF, as zonular insecurity can prompt restricted countertraction.

Late advances demonstrate that a strong ophthalmic viscosurgical gadget can help keep up a framed front chamber intraoperatively, while container recoloring gadgets can help with representation. It is likewise found that Capsular pressure rings (CTR) or portions can be utilized to oversee intraoperative zonular precariousness.^{33,34}

In the event that a CTR is utilized, most extreme consideration must be taken amid cortex expulsion as the cortex can wind up caught behind the capsular strain gadget amid the medical procedure. Care ought to likewise be taken to limit descending weight on zonules amid hydrodissection, however a decent hydrodissection enhances focal point motility and can limit weight on zonules; viscodissection can be utilized also to isolate the cortex from the container to encourage evacuation.

A few strategies incorporate that packing the front chamber amid hydrodissection ought to likewise be maintained a strategic distance from to avoid further over the top zonular push. Preoperatively, ultrasonic biomicroscopy should be possible to show the testimony of PXF material on zonules and in addition zonular fracture, in this way controlling the specialist's strategies for waterfall extraction. And furthermore, there is likewise a complexity identified with zonular shortcoming which is confusion of water system liquid. Water system liquid misled through a zonular dialysis can prompt expanded vitreous pressure.^{35,36}

New systems like bringing down water system rates, putting a dispersive ophthalmic viscosurgical gadget around the site of zonular misfortune, and capsular pressure rings would all be able to help limit this liquid confusion.

4.2. Pseudoexfoliation and lens dislocation

Focal point disengagement can likewise be expected of PXF and is thought to happen optional to proteolytic components of the pseudoexfoliative material on zonules bringing about friability and modified elasticity of the zonular fibers.^{37,38}

Consistently, PXF is viewed as the most widely recognized reason for unconstrained intraocular focal point (IOL) subluxation and a deferred IOL disengagement isn't unprecedented in PXF patients. Intraoperatively or precipitously postoperatively focal point subluxation is seen commonly.

The pathology behind the component of separation is thought to happen at three dimensions of PXF material affidavit: at the birthplace of the ciliary body where zonules

are moored, in the standards plicata where zonules go close by ciliary process, and at the zonular connection of the front focal point case. The occurrence of phacodonesis or potentially subluxation of the focal point in PXF eyes has been accounted for to be somewhere in the range of 8.4% and 10.6%.^{39,40}

The late IOL disengagement was viewed as due to zonular precariousness alongside compression of the front focal point case, as PXF eyes are known to have increasingly articulated foremost focal point container constriction. Capsular pressure rings or sections have demonstrated to offer help and roundabout form to the capsular pack and uniformly circulate powers among the staying unblemished zonules.

In instances of finish focal point separation or extreme zonular shortcoming, IOLs may be fixated transclerally, put in the front chamber, or maybe even put in the ciliary sulcus. Studies demonstrate that care must be taken with foremost chamber IOL situation, given the high occurrence of glaucoma seen in PXF patients.

In the examination by Jehan et al., the procedure demonstrated that six out of the eight eyes with late unconstrained separation were treated with IOL trade with front chamber IOL position, one out of eight with IOL trade and scleral obsession of a back chamber IOL, and one out of eight with scleral obsession of the disengaged IOL itself.⁴¹

4.3. Pseudoexfoliation and increased postoperative complications

Corneal decompensation, IOP spikes, foremost capsular phimosis, and even back capsular opacification are the different postoperative intricacies of PXF patients. Corneal decompensation can result from an assortment of variables. Diminished endothelial cell checks and polymorphism might be found in a few patients with PXF, accordingly inclining these eyes to postoperative corneal decompensation.

Eyes with PXF have been believed to require longer working occasions, additionally setting the cornea at a higher hazard for postoperative decompensation. Systems like utilizing Dispersive ophthalmic viscosurgical gadgets intraoperatively can encourage coat and ensure the cornea. It is seen that early postoperative intraocular weight spikes are more typical in PXF eyes than in non-PXF eyes, but patients with PXF have additionally been appeared to have a long haul supported IOP decrease following phacoemulsification.⁴²

Studies demonstrate that careful evacuation of all viscoelastic amid medical procedure ought to be performed given PXF eyes are at a more serious danger of building up a quick height of IOP, which could potentiate glaucomatous harm in eyes that are now powerless to creating glaucoma. Acetazolamide sedate when utilized in the prompt postoperative period, alongside topical

glaucoma meds, can help gruff the intense ascent in intraocular pressure.⁴³

Foremost capsular withdrawal and phimosis are believed to be more typical in PXF than in non-PXF eyes. While CTRs uniformly disperse pressure from the debilitated zonules to the rest of the zonules, they have likewise been appeared to diminish postoperative IOL decentration and tilt, factors critical in eyes with PXF.

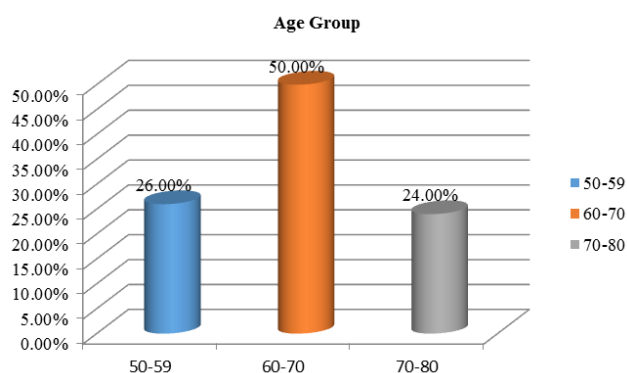
A capsulorhexis of at any rate 5.5 millimeters can help in lessening zonular worry in foremost capsular phimosis. The rate of back capsular opacification is expanded in PXF patients as per a few investigations. It is additionally observed that breakdown of the blood-fluid hindrance has been proposed to be in charge of the expanded danger of back capsular opacification in PXF eyes.

Moreover, postoperative aggravation will in general be higher in patients with PXF, intensifying corneal decompensation and postoperative IOP spikes. Legal utilization of topical nonsteroidal mitigating medications and steroids can help in controlling the postoperative inflammation.⁴⁴

5. Results

Table 1: Age distribution in patients with pseudoexfoliation syndrome

Age	No. of patients	Percentage
50-59	13	26.00%
60-70	25	50.00%
70-80	12	24.00%



Graph 1: Age distribution in patients with pseudoexfoliation syndrome

6. Discussion

Patients with pseudoexfoliation syndrome with cataract posted for manual small incision cataract surgery have to be carefully looked for insufficient mydriasis, IOP, subluxation

Table 2: Pupillary dilatation (insufficient mydriasis) in pseudoexfoliation syndrome

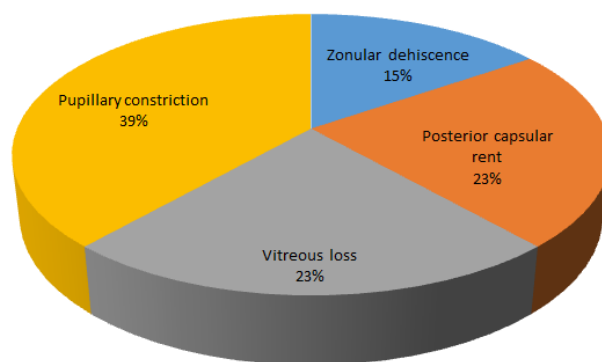
Pupillary dilatation	Number of patients	Percentage
Sufficient(> 6mm)	30	60%
Insufficient(<6mm)	20	40%
Total	50	100%

Table 3: Intraoperative complications in pseudoexfoliation syndrome

Complications	Number of patients	Percentage	P value
Occured	13	26.00%	0.002
Not occured	37	74.00%	
Total	50	100.00%	

Table 4: Individual types of intraoperative complications in patients with pseudoexfoliation syndrome

Complications	Number of patients	Percentage
Zonular dehiscence	2	4.00%
Posterior capsular rent	3	6.00%
Vitreous loss	3	6.00%
Pupillary constriction	5	10.00%



Graph 2: Complication

Table 5: Surgical outcome in patients with pseudoexfoliation syndrome

Outcome	Number of patients	Percentage
Intraocular lens implantaion	45	90.00%
Aphakic lens with secondary iol implantation	5	10.00%
Total	50	100.00%

or dislocation of cataract lens, because these preoperative factors have bearing on the intraoperative complications.

Insufficient mydriasis is one of the major pre operative complications in the eye with pseudoexfoliation syndrome which has a bearing on major preoperative complications like vitreous loss and posterior capsular rent.

This study consisted of 50 eyes of 50 patients with pseudoexfoliation syndrome who underwent manual small incision cataract surgery at R.L.J. Hospital and Research Centre, Tamaka, Kolar attached to Sri Devraj Urs Medical College between July 2009 and July 2010

As shown in table there were total 50 patients were enrolled between age of 50 years to 80 years and out of 50 patients. Furthermore we have found that half of total enrolled patients had age between 60 years to 70 years whereas 26% of patients had age between 50 years to 59 years and remaining 24% of patients had age between 71 years to 80 years.

In the present study as shown in table 2 we have found that 60% of the patients had sufficient mydriasis (> 6mm) whereas 40% of the them had insufficient mydriasis (< 6mm).

In present study Intraoperative complication has been observed in 26.00% of patients whereas on 74.00% patients we did not observed any Intraoperative complications. This result we have found statistically significant with p value of 0.002. It has been concluded that percentage of Intraoperative complication is significantly less.

According to table 4, in 10% of the patients pupillary constriction has been observed followed by 6.00% of the patients posterior capsular rent, 6.00% of the patients have vitreous loss and 4.00% of the patients had Zonular dehiscence has been observed respectively during surgery.

90% of the patients were implanted with intraocular lens after employment of various surgical modifications like with iris hooks, Sphincterotomy, Synechiolysis and manual anterior vitrectomy and 10% of the patients were left aphakic due to the above mentioned complications who underwent secondary IOL implantation latter.

7. Conclusions

All though cataract surgery in pseudoexfoliation syndrome is challenging, if the surgeon is aware of the condition preoperatively and pay meticulous attention to the surgical technique during manual small incision cataract surgery, the intraoperative complication can be managed and a good outcome is expected in eye camps surgery.

8. Source of Funding

None.

9. Conflict of Interest

None.

References

1. Pseudoexfoliation syndrome: the puzzle continues. *J Ophthalmic Vis Res.* 2012;7(3):187–189.
2. Kastelan S, Tomic M, Kordic R. Cataract surgery in eyes with pseudoexfoliation (PEX) syndrome. *J Clin Exp Ophthalmol.* 2013;1:9.
3. Kang JH, Loomis S, Wiggs JL. Demographic and geographic features of exfoliation glaucoma in two United States based prospective cohorts. *Ophthalmol.* 2012;119:27–35.
4. Pasquale LR, Wiggs JL, Willett WC, Kang JH. The relationship between caffeine and coffee consumption and exfoliation glaucoma or glaucoma suspect: A prospective study in two cohorts. *IOVS.* 2012;53(10):6427–6433.
5. Schlotzer-Schrehardt U, Naumann G. Ocular and systemic pseudoexfoliation syndrome. *Am J Ophthalmol.* 2006;141:921–937.
6. Bartholomew RS. Pseudoexfoliation and angle-closure glaucoma. *Glaucoma.* 1981;3:213–216.
7. Ritch R. Exfoliation syndrome and occludable angles. *Trans Am Ophthalmol Soc.* 1994;92:845–944.
8. Kanthan GL, Mitchell P, Burlutsky G. Pseudoexfoliation Syndrome and the long-term incidence of cataract and cataract surgery: The Blue Mountain Eye Study. *Am J Ophthalmol.* 2013;155:83–88.
9. Kuchle M, Vinore SA, Mahlow J, Green WR. Blood aqueous barrier in pseudoexfoliation syndrome: Evaluation by immunohistochemical staining of endogenous albumin. *Graefes Arch Clin Exp Ophthalmol.* 1996;234(1):12–18.
10. Belovay G, Varma D, Ahmed I. Cataract surgery in pseudoexfoliation syndrome. *Curr Opin Ophthalmol.* 2010;21:25–34.
11. Shingleton BJ, Heltzer J, W ODM. Outcomes of phacemulsification in patients with and without pseudoexfoliation syndrome. *J Cataract Refract Surg.* 2003;29:1080–1086.
12. Venkatesh R, Tan CS, Veena K. Severe anterior capsular phimosis following acrylic intraocular lens implantation in a patient with pseudoexfoliation. *Ophthalmic Surg Lasers Imaging.* 2008;39:228–229.
13. Davison JA. Capsule contraction syndrome. *J Cataract Refract Surg.* 1993;19:582–589.
14. Eferences, Bourne RR, Stevens GA, White RA. Causes of vision loss worldwide, 1990–2010: a systematic analysis. *Lancet.* 2013;15:339–349.
15. Kanthan GL, Mitchell P, Burlutsky G, Rohtchina E, Wang JJ. Pseudoexfoliation syndrome and the long-term incidence of cataract surgery: the Blue Mountains eye study. *Am J Ophthalmol.* 2013;155(1):83–88. e1.
16. Ekström C, A BT, Botling Taube A. Pseudoexfoliation and cataract surgery: a population-based 30-year follow-up study. *Acta Ophthalmol.* 2015;93(8):774–777.
17. Pseudoexfoliation syndrome: the puzzle continues. *J Ophthalmic Vis Res.* 2012;7(3):187–189.
18. Walinder PE, Olivious EO, Nordell SI, Thoburn WE. Fibrinoid reaction after extracapsular cataract extraction and relationship to exfoliation syndrome. *J Cataract Refract Surg.* 1989;15(5):526–530.
19. Wirbelauer C, N A, Pham DT, Wollensak J. Corneal endothelial cell changes in pseudoexfoliation syndrome after cataract surgery. *Arch Ophthalmol.* 1998;116(2):145–149.
20. Moreno J, Duch S, Lajara J. Pseudoexfoliation syndrome: clinical factors related to capsular rupture in cataract surgery. *Acta Ophthalmol (Copenh).* 1993;71(2):181–184.
21. Tanhehco T, Chen SH. Pseudoexfoliation syndrome and cataract surgery. *Int Ophthalmol Clin.* 2010;50(1):81–93.
22. Alfaiate M, Leite E, Mira J. Prevalence and surgical complications of pseudoexfoliation syndrome in Portuguese patients with senile cataract. *J Cataract Refract Surg.* 1996;22:972–976.
23. Drosium L, Haaskjold E, Davanger M. Results and complications after extracapsular cataract extraction in eyes with pseudoexfoliation syndrome. *Acta Ophthalmol (Copenh).* 1993;73:771–776.
24. Drosium L, Davanger M, Haaskjold E. Risk factors for an inflammatory response after extracapsular cataract extraction and

- posterior chamber IOL. *Acta Ophthalmol (Copenh)*. 1994;72:21-26.
25. Alfaiate M, Leite E, Mira J. Prevalence and surgical complications of pseudoexfoliation syndrome in Portuguese patients with senile cataract. *J Cataract Refract Surg*. 1996;22:972-976.
 26. Drolsum L, Haaskjold E, Davanger M. Results and complications after extracapsular cataract extraction in eyes with pseudoexfoliation syndrome. *Acta Ophthalmol (Copenh)*. 1993;73:771-776.
 27. Drolsum L, Davanger M, Haaskjold E. Risk factors for an inflammatory response after extracapsular cataract extraction and posterior chamber IOL. *Acta Ophthalmol (Copenh)*. 1994;72:21-26.
 28. Olivius E, Nordell SI, Walinder PE. Fibrinoid reaction after extracapsular cataract extraction and its relations to exfoliation syndrome - a prospective study. *Eur J Implant Refract Surg*. 1989;1:5-8.
 29. Kuchle M, Viestenz A, Martus P. Anterior chamber depth and complications during cataract surgery in eyes with pseudoexfoliation syndrome. *Am J Ophthalmol*. 2000;129:281-285.
 30. Scorolli L, Scorolli L, Campos EC. Pseudoexfoliation syndrome: A cohort on intraoperative complications in cataract surgery. *Ophthalmol*. 1998;212:278-280.
 31. Drolsum L, Hasskjold E, Sandvig K. Phacoemulsification in eyes with pseudoexfoliation. *J Cataract Refract Surg*. 1998;24:787-792.
 32. Hyams M, Mathalone N, Herskovitz M. Intraoperative complications of phacoemulsification in eyes with and without pseudoexfoliation. *J Cataract Refract Surg*. 2005;31:1002-1005.
 33. Kastelan S, Busic M. Pseudoexfoliation syndrome and cataract surgery. *Ophthalmol Croatica*. 2003;11:37-40.
 34. Busic M, Kastelan S. Pseudoexfoliation syndrome and cataract surgery by phacoemulsification. *Coll Antropol*. 2005;1:163-166.
 35. Hovding G. The association between fibrilopathy and posterior capsular/zonular breaks during extracapsular cataract extraction and posterior chamber IOL implantation. *Acta Ophthalmol (Copenh)*. 1988;66:662-666.
 36. Pouliquen P, Colin RA, J. Syndrome exfoliatif et chirurgie de la cataracte. *J Fr Ophthalmol*. 1992;15:171-176.
 37. Kuchle M, Schonherr U, Dieckmann U, Augenblatter-Gruppe E. Risk factors for capsular breaks and vitreous loss in extracapsular cataract surgery. *Fortschr Ophthalmol*. 1989;86:417-421.
 38. Jehan FS, Mamalis N, Crandall AS. Spontaneous late dislocation of intraocular lens within the capsular bag in pseudoexfoliation patients. *Ophthalmol*. 2001;108:1727-1731.
 39. RCJ EJ, Lens WHS. Ophthalmic Pathology: At Atlas and Textbook. H SW, ed Philadelphia: WB Saunders , editors ; 1996.. 4th ed. pp 394.Pseudoexfoliation Syndrome.
 40. Schlotzer-Schrehardt U, Naumann GOH. A histopathologic study of zonular instability in pseudoexfoliation syndrome. *Am J Ophthalmol*. 1994;118:730-743.
 41. Gimbel HV, Condon GP, Kohnen T. Late in-the-bag intraocular lens dislocation: Incidence, prevention, and management. *J Cataract Refract Surg*. 2005;31:2193-2204.
 42. Naumann GO, Kuchle M, Schonherr U. Pseudoexfoliation syndrome as a risk factor for vitreous loss in extra-capsular cataract extraction. *Fortschr Ophthalmol*. 1989;86:543-545.
 43. Hayashi H, Hayashi K, Nakao F, Hayashi F. Anterior capsule contraction and intraocular lens dislocation in eyes with pseudoexfoliation syndrome. *Br J Ophthalmol*. 1998;82:1429-1432.
 44. Fine IH, Hoffman RS. Phacoemulsification in the presence of pseudoexfoliation: Challenges and options. *J Cataract Refract Surg*. 1997;23:160-165.

Author biography

Punit Singh Associate Professor

Deepak Patel Professor

Cite this article: Singh P, Patel D. One year study of complications of cataract surgery in pseudoexfoliation syndrome in rural area (Eye camps). *Indian J Clin Exp Ophthalmol* 2019;5(4):470-476.