

Content available at: <https://www.ipinnovative.com/open-access-journals>

Indian Journal of Clinical and Experimental Ophthalmology

Journal homepage: [www.ijceo.org](http://www.ijceo.org)

## Case Report

# Schnyders corneal dystrophy: A case report

Keerti Wali<sup>1</sup>, Mervin Jonathan Israel<sup>1\*</sup>

<sup>1</sup>Dept. of Ophthalmology, Shri B M Patil Medical College, Hospital & Research Centre



## ARTICLE INFO

### Article history:

Received 08-06-2023

Accepted 24-06-2023

Available online 29-12-2023

### Keywords:

Arcus lipoides

Intrastromal deposits

Schnyders corneal dystrophy

## ABSTRACT

Schnyder corneal dystrophy (SCD) is a rare, autosomal dominant inherited dystrophy affecting the anterior stroma of the cornea. It is caused by a local metabolic defect mapped on the UBIAD1 gene chromosome 1p36. It is known to cause progressive bilateral opacification of the cornea due to an abnormal accumulation of phospholipids and cholesterol in the cornea. In our case a 22-year-old male with vision loss and ocular discomfort revealed multiple grey, infiltrates or disc like opacities in both eyes arranged in a circinate manner on slit-lamp, involving the sub-epithelium and stroma. On anterior segment OCT, involvement of the entire stroma was noted with increased deposits seen in the anterior 1/3rd of the stroma. Central corneal thickness was also increased in the areas of depositions, while systemic evaluation showed dyslipidemia. Clinical as well as anterior segment OCT findings suggest of intrastromal deposits in a ring like pattern, suggestive of Schnyder's corneal dystrophy. AS-OCT is vital in such cases to help differentiate epithelial involvement from stromal, thus altering the therapeutic approach. Patients can be planned for penetrating keratoplasty if visual acuity is affected.

This is an Open Access (OA) journal, and articles are distributed under the terms of the [Creative Commons Attribution-NonCommercial-ShareAlike 4.0 License](https://creativecommons.org/licenses/by-nc-sa/4.0/), which allows others to remix, tweak, and build upon the work non-commercially, as long as appropriate credit is given and the new creations are licensed under the identical terms.

For reprints contact: [reprint@ipinnovative.com](mailto:reprint@ipinnovative.com)

## 1. Introduction

Schnyder's corneal dystrophy is a rare, autosomal dominant, inherited corneal dystrophy.<sup>1,2</sup> That leads to an abnormal accumulation of phospholipids and cholesterol molecules in the cornea.<sup>3,4</sup> This abnormal accumulation is mainly known to affect the anterior corneal stroma, leading to progressive bilateral opacification and vision loss.<sup>5</sup>

## 2. Case Report

A male patient in mid twenty presented with bilateral gradual painless vision loss in both eyes for five years along with watering, burning and pricking sensations for two months. There is no family history of similar complaints and no history of comorbidities. On examination, the Best corrected visual acuity was 20/40 in the right eye and 20/30

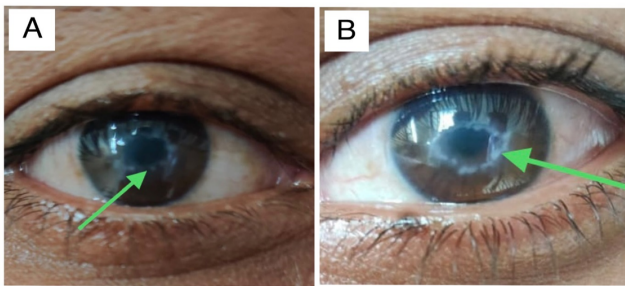
in the left eye.

On Slit-lamp examination, multiple greyish plaque-like opacities were seen measuring 2x2mm each in both eyes (Figure 1 A,B). They are arranged in a circinate manner forming an arcus like pattern involving a 3-6mm zone of the cornea with a slight diffuse haze in the pupillary area (Figure 2 A,B). Oblique illumination showed the involvement of the sub-epithelial and anterior stromal regions. A sharp distinctive demarcation is noted from the transparent, unaffected corneal epithelium. No conjunctival congestion was noted, and fluorescein staining was negative.

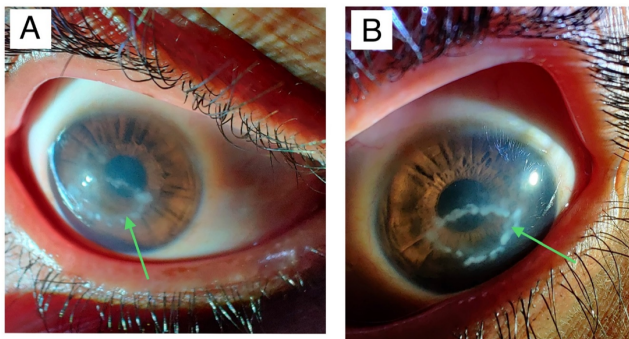
On the anterior segment, optical coherence tomography, involvement of the entire stroma is noted with an increased deposition in the anterior 1/3rd (Figure 3A). Extensions were also seen in the sub-epithelium, corresponding to the ring-like deposits visible on the slit lamp (Figure 3 B). Central corneal thickness was 535  $\mu$ m and 540  $\mu$ m in the right and left eyes, respectively. Thickness was increased in

\* Corresponding author.

E-mail address: [mervinisrael@yahoo.co.in](mailto:mervinisrael@yahoo.co.in) (M. J. Israel).

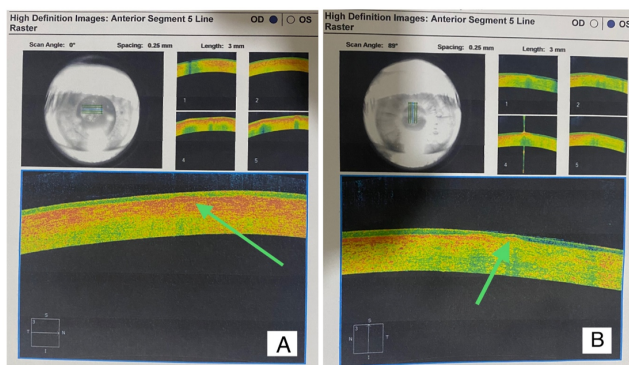


**Figure 1:** Image showing multiple greyish plaque-like opacities arranged in a circinate pattern an arcus (green arrow) in the right eye (A) and left eye (B)



**Figure 2:** Showing involvement of 3-6mm zone of the cornea with slight diffuse haze in the pupillary area (green arrow) in the right eye (A) and left eye (B)

the areas of deposits to  $585\mu\text{m}$  in the right eye and  $615\mu\text{m}$  in the left eye. On systemic evaluation, dyslipidemia is noted with an increased blood cholesterol level of  $246\text{mg/dl}$ .



**Figure 3:** Anterior segment optical coherence tomography showing the involvement of the entire stroma with Increased deposition in the anterior 1/3rd (green arrow) in the right eye (A) and extensions into the subepithelium (green arrow) in left eye (B)

Symptomatic relief was achieved with lubricant eye drops four times a day, along with spectacle correction for Visual rehabilitation. The patient was counselled about the nature and prognosis of the disease, and possible

need for corneal transplantation in the future. A routine three-monthly follow up was advised. Oral lipid-lowering medication was started and titrated for adequate control. Subsequent lipid profiling for all his siblings and children was advised.

### 3. Discussion

Clinical and anterior segment optical coherence tomography findings of intrastromal deposits along with dyslipidemia are suggestive of Schnyder corneal dystrophy. The deposits appear limited to the superficial stroma, making phototherapeutic keratomileusis [PTK] a viable option. However, OCT showed involvement of the entire stroma, thus ruling out the possibility of the same. In this case, diagnosis by OCT paved the way in deciding further management.

Schnyder corneal dystrophy is an autosomal dominant trait with high penetrance, as stated by Lisch W et al., it is a local defect mapped on the UBIAD1 gene chromosome 1p36. Hypercholesterolemia is a known associated systemic feature seen in about one-third of cases. The incidence of hypercholesterolemia may also be seen in unaffected members of Schnyder's pedigrees, as stated by Lisch W et al.<sup>1</sup> Similar crystalline deposits may also be seen in other conditions as stated by Kurtul BE et al, wherein side effects of certain drugs like fluoroquinolones, chlorpromazine, chloroquine, clofazimine and gold in chrysiasis are known to cause similar depositions. They also mentioned lymphoproliferative diseases such as monoclonal gammopathy and multiple myeloma as probable causes of similar crystalline deposits.<sup>5</sup>

There is no available treatment to stop the progression of Schnyder's, However Rittenbach TL et al. mentioned modalities such as phototherapeutic keratectomy<sup>6,7</sup> that can be used to remove the superficially located cholesterol crystals, and penetrating keratoplasty (PKP)<sup>8</sup> or a deep anterior lamellar keratoplasty (DALK) can also be performed.<sup>7</sup>

### 4. Conclusion

Anterior segment optical coherence tomography is vital in such cases to help differentiate the involvement of anterior epithelium from that of stroma, thus altering the therapeutic approach. Schnyder's corneal dystrophy may be an ocular presentation of systemic hyperlipidemia; thus, an early diagnosis aids in the management of the systemic derangement and their complications.

### 5. Source of Funding

None.

## 6. Conflict of Interest


None.

## References

1. Weiss JS, Khemichian AJ. Differential diagnosis of schnyder corneal dystrophy. *Dev Ophthalmol*. 2011;48:67–96.
2. Weiss JS. Schnyder's dystrophy of the cornea. A Swede-Finn connection. *Cornea*. 1992;11(2):93–101.
3. Rodrigues MM, Kruth HS, Krachmer JH, Vrabec MP, Blanchette-Mackie J. Cholesterol localization in ultrathin frozen sections in Schnyder's corneal crystalline dystrophy. *Am J Ophthalmol*. 1990;110(5):513–7.
4. Weller RO, Rodger FC. Crystalline stromal dystrophy: histochemistry and ultrastructure of the cornea. *Br J Ophthalmol*. 1980;64(1):46–52.
5. Kurtul BE, Elbeyli A, Ozcan DO, Ozcan SC, Karaaslan A. Schnyder Corneal Dystrophy: A Rare Case Report. *Nepal J Ophthalmol*. 2020;12(1):110–3.
6. Köksal M, Kargi S, Gürelik G, Akata F. Phototherapeutic keratectomy in Schnyder crystalline corneal dystrophy. *Cornea*. 2004;23(3):311–3.
7. Rittenbach TL. A case of schnyder corneal dystrophy with crystals. *Optom Vis Sci*. 2013;90(12):301–4.
8. Chen C, Tung HF, Liu YL, Lin C. Deep phototherapeutic keratectomy for Schnyder corneal dystrophy. *Taiwan J Ophthalmol*. 2023;3(2):238–41.

## Author biography

**Keerti Wali**, Assistant Professor  <https://orcid.org/0000-0002-6727-524X>

**Mervin Jonathan Israel**, Junior Resident  <https://orcid.org/0000-0003-4651-8588>

**Cite this article:** Wali K, Israel MJ. Schnyders corneal dystrophy: A case report. *Indian J Clin Exp Ophthalmol* 2023;9(4):650-652.