

Content available at: <https://www.ipinnovative.com/open-access-journals>

Indian Journal of Clinical and Experimental Ophthalmology

Journal homepage: www.ijceo.org

Original Research Article

Lens induced glaucoma – Clinical profile and prognosis in tertiary care centre

Vinuta Mohan Kulkarni^{1*}, Nishat Sultana², Abdul Rauf Abid³¹Dept. of Ophthalmology, Kempegowda Institute of Medical Science, Bengaluru, Karnataka, India²Dept. of Ophthalmology, Bangalore Medical College and Research Institute, Bengaluru, Karnataka, India³Dept. of Ophthalmology, Gulbarga Institute of Medical Sciences, Kalaburagi, Karnataka, India

ARTICLE INFO

Article history:

Received 03-07-2023

Accepted 04-08-2023

Available online 29-12-2023

Keywords:

Lens induced glaucoma

Phacomorphic

Phacolytic

SICS

ABSTRACT

Background: Conditions in which cataractous lens and abnormalities of lens leads to elevated intra ocular pressure have been termed as Lens induced glaucoma (LIG). Objective of our study was to know the clinical profile of patients, describe management and visual outcome in lens induced glaucoma.

Materials and Methods: Hospital based prospective study conducted on 40 patients of LIG from November 2016 to October 2018 attending the outpatient department of Ophthalmology at Minto Ophthalmic Hospital, Bangalore Medical College and Research Institute. After taking informed consent, detail history, detailed examination, IOP by Applanation tonometry, Gonioscopy, examination of posterior segment, patients diagnosed as lens induced glaucoma admitted and managed with medical and surgical treatment. Post operative day 1 visual acuity and IOP recorded and followed up on day 8 and 6 weeks for above. Data analyzed with descriptive statistics and chi square test.

Results: In our study mean age of presentation in phacomorphic glaucoma is 67.25 ± 6.58 years and phacolytic glaucoma mean age was $64.10 \text{ years} \pm 9.78$. Female to male ratio being 1.8 : 1. Phacomorphic glaucoma was found in 57% and phacolytic glaucoma in 43%. Mean IOP at presentation was $42.6 \text{ mmHg} \pm 5.36$. Most of them underwent SICS + PCIOL (52.5%). Study showed that most of them had better visual acuity at the end of 6 weeks. Final IOP was $15.8 \text{ mmHg} \pm 1.78$.

Conclusion: Our study demonstrated that lens induced glaucoma is still a challenging complication of cataract which can be prevented by early treatment of cataract. SICS is still gold standard that effectively controls IOP and gives better visual outcome.

This is an Open Access (OA) journal, and articles are distributed under the terms of the [Creative Commons Attribution-NonCommercial-ShareAlike 4.0 License](https://creativecommons.org/licenses/by-nc-sa/4.0/), which allows others to remix, tweak, and build upon the work non-commercially, as long as appropriate credit is given and the new creations are licensed under the identical terms.

For reprints contact: reprint@ipinnovative.com

1. Introduction

Conditions in which cataractous lens and abnormalities of lens leads to elevated intra ocular pressure have been termed as Lens induced glaucoma.^{1–3} Cataract forms the major cause of blindness all over the world. In developing countries like India, where awareness and public health facilities suffer lot of drawbacks, treatment for cataract is not sought early, leading to complications such as lens induced glaucoma.^{4–6} Early cataract treatment will prevent

secondary glaucoma such as lens induced glaucoma that can be blinding disease. Cataractous lens can lead to increase in intra ocular pressure by various mechanisms. Mature or hypermature cataractous lens can lead to obstruction of aqueous out flow by either blocking the trabecular meshwork or opposition of angle of anterior chamber leading to either open angle or closed angle glaucomas. Lens induced glaucoma is one of the type of secondary glaucoma, causing irreversible damage to optic nerve because of raised intra ocular pressure. Removal of cataract can prevent this type of glaucoma. Much studies have been done on visual outcome in lens induced glaucoma and have

* Corresponding author.

E-mail address: vin.mk91@gmail.com (V. M. Kulkarni).

shown that cataract extraction done as early as possible in such cases can give better visual prognosis. Our hospital being a tertiary care centre covers large population, and hence gets referral from various primary health centres. Our study intends to know the clinical profile of patients with lens induced glaucoma in detail and describe management and visual outcome in such cases.

2. Materials and Methods

The hospital based prospective study was conducted over a period of 2 years, from November 2016 to October 2018. 40 patients attending ophthalmology department of Minto Ophthalmic Hospital, Regional Institute of Ophthalmology and Bowring hospital allied to Bangalore Medical College and Research Institute with symptoms and signs of the disease were included in the study. Ethical committee clearance was taken from the institute for the study proposed.

Based on the previous study conducted by Pradhan D, Hennig A, Kumar J, Foster A.⁵ Sample size $n=4pq/d^2$, where $p=72$, $q=28$ and $d=20\%$ (allowable error)

2.1. Inclusion criteria

All cases of LIG with Senile immature cataract, Senile mature cataract, Senile hypermature cataract, above the age of 40 years willing to give written informed consent.

2.2. Exclusion criteria

1. Traumatic cataract with Lens particle glaucoma.
2. Primary narrow angle glaucoma.
3. Patient less than 40 yrs.
4. Secondary glaucoma due to other causes.
5. LIG due to subluxation, dislocation of lens.
6. Non-compliant patients
7. Primary open angle glaucoma

After detailed evaluation, diagnosis of the lens induced glaucoma based on the clinical features. Phacomorphic glaucoma was diagnosed in cases of sudden painful diminution of vision with shallow anterior chamber and closed angles. Other features include circumcorneal congestion, dilated or fixed pupil with intumescent cataract and IOP more than 21mmHg. Phacolytic glaucoma was diagnosed in the setting of sudden painful diminution of vision with deep anterior chamber. Other features include severe uveitis, hypopyon, morgagnian cataract, open angles, corneal edema and IOP more than 21mmHg. Other types of lens induced glaucoma such lens particle glaucoma and phaco anaphylaxis glaucoma also diagnosed based on the clinical features. Diagnosed cases of lens induced glaucoma admitted and Intra ocular pressure controlled with medical management.

After getting basic blood investigations, consent taken for cataract extraction and IOL implantation under guarded vision prognosis. All the cases underwent cataract extraction (SICS) under peribulbar anesthesia. 6 cases were found to have posterior capsular tear on table. In one of the cases, lens was placed in the sulcus, remaining cases were left aphakic. Remaining cases underwent rigid PCIOL implantation. Post operatively, visual acuity testing, detailed slit lamp examination, IOP measurement was done on all the patients. Patients were started on antibiotic steroid hourly with cycloplegics. Oral steroids were started in cases of severe reaction and hypopyon. Patients discharged on next day and called for follow up. Post op day 8 visual acuity, IOP noted on follow up and fundus was evaluated in operated eye. 6 patients who had disc suspect in other eye were evaluated for glaucoma in detail and baseline visual fields was done and regularly followed up. All the data collected and tabulated in Microsoft excel spreadsheet and analysed using various statistical tests.

2.2.1. Method of statistical analysis

The following methods of statistical analysis have been used in this study.

The results for each parameter (numbers and percentages) for discrete data and averaged (mean + standard deviation) for each parameter were presented in tables and figures. Proportions were compared using Chi-square test of significance.

Rows	Columns			Total
	1	2.....c	c	
1	a_1	a_2	a_c	t_1
2	b_1	b_2	b_c	t_2
.
.
r	h_1	h_2	h_c	t_r
Total	n_1	n_2	n_c	N

a, b, ..., h are the observed numbers.
N is the grand total

$$X^2 = N \left[\frac{1}{t_1} \sum_1^c \frac{a_1^2}{n_1} + \frac{1}{t_2} \sum_1^c \frac{b_1^2}{n_1} + \dots + \frac{1}{t_r} \sum_1^c \frac{h_1^2}{n_1} - 1 \right]$$

DF = (r-1)*(c-1), where r = rows and c = columns

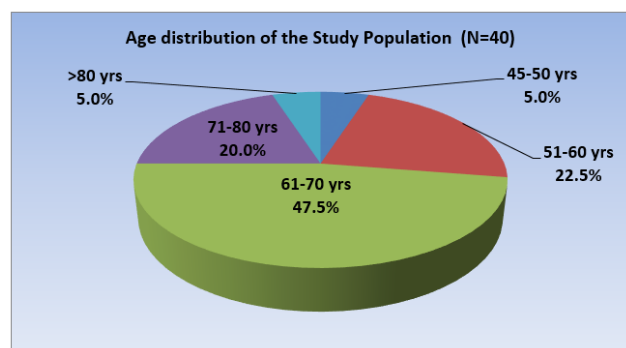
DF = Degrees of Freedom (Number of observation that are free to vary after certain/Restriction have been placed on the data).

In the above test P value less than 0.05 was taken to be statistically significant. The data was analyzed using SPSS package (Ver 18.0).

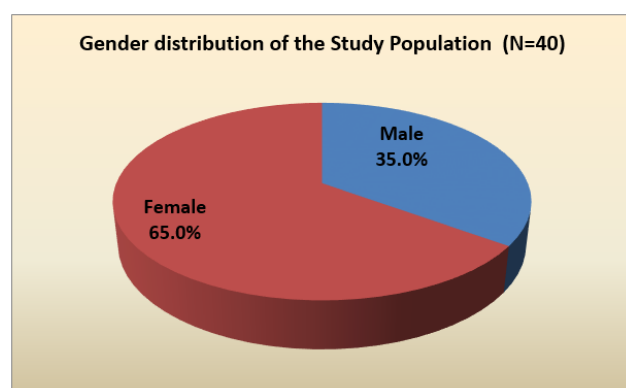
3. Results

In our study mean age of presentation in phacomorphic glaucoma is 67.25 ± 6.58 years. In phacolytic glaucoma

mean age was 64.10years \pm 9.78.(Graph 1) Most frequent age group was 61 to 70 years. In our study females constituted 65% while males were 35%. (Graph 2). Female to male ratio being 1.8 : 1.



Graph 1: Age distribution



Graph 2: Gender distribution

In our study phacomorphic glaucoma was found in 57% of cases and phacolytic glaucoma in 43% of cases.(Table 1).

Table 1: Distribution based on type of Lens induced glaucoma

Type	Number	Percentage
Phacomorphic glaucoma	23	57.5
Phacolytic glaucoma	17	42.5

In the study vision at presentation in affected eye was Hand movement in 32 (80%) of cases and only perception of light in 8 (20%) of the cases. In our study mean duration of acute symptoms of pain, redness, headache was 2.81 days with minimum of 1 day and maximum of 7 days.(Table 2)

This was similar to both the types of Lens induced glaucoma seen in the study. In the study, mean duration of diminution of vision in affected eye was 6 months in phacomorphic glaucoma and 8months in cases of phacolytic glaucoma. Most of them reported diminution of vision in period of 5months to 8 months. In the study, mean IOP at

Table 2: Distribution of cases according to duration of acute symptoms

Duration (days)	Phacomorphic		Phacolytic		Total	
	No	%	No	%	No	%
1-2	11	47.82	11	64.70	21	52.5
3-4	9	39.13	6	35.29	15	40
5-6	2	8.69	1	5.88	2	5
>6	1	4.34	0	0	1	2.5
Total	23	100	17	100	40	100

presentation was 42.6mmHg \pm 5.36with the minimum value of 30mmHg and maximum of 52mmHg (Table 3).

Table 3: Distribution of cases according to Intra ocular pressure at presentation

IOP (mmHg)	Number	Percentage
30-35	2	5
36-40	13	32.5
41-45	6	15
46-50	15	37.5
>50	4	10

Most frequent IOP was in the range of 46 – 50mmHg. In the study, most of them underwent SICS + PCIOL (52.5%). In 30% of cases SICS +PCIOL+ PI was done and in 7 (17.5%) of cases plain lens extraction was done and was later planned for SFIOL implantation.(Table 4)

Table 4: Distribution according to surgical procedure cases underwent

Procedure	Number	Percentage
SICS + PCIOL	27	67.5
SICS+PCIOL+PI	8	20
SICS	5	12.5

In our study, post-operative BCVA at the end of 6 weeks was 6/18 to 6/6 in 13 (32.5%) cases, 6/24 to 6/60 in 22 cases (55%) and less than 6/60 in 5 (12.5%) cases (Table 5).

Table 5: Distribution of cases according to BCVA at last follow up and IOP at presentation

BCVA	IOP at presentation		IOP at Presentation	
	<40	mmHg	>40	mmHg
	No	%	No	%
6/6-6/18(0-0.5)	6	42.85	7	26.92
6/24-6/60(0.5-1)	8	57.25	14	53.08
<6/60(>1)	0	0	5	19.23

Most of them had better visual acuity at the end of 6 weeks. In the study, examination of fundus was done post-operatively to look for glaucomatous optic disc changes. Most of them 30 cases (75%) had normal fundus. About

5 cases (12.5%) had CDR of 0.5 – 0.7 and 5 (12.5%) cases had CDR of 0.8-1, who were followed up and treated later. (Table 6)

Table 6: Distribution according to optic disc changes at the last follow up

CDR	Number	Percentage
Normal	29	72.5
0.5- 0.7	6	15
0.8-1	5	12.5

In the study, it was observed that about 21 cases (52.5%) were pseudophakic in the other eye. About 19 cases (47.5%) had cataractous lens in other eye. In the study, 12 of 13 cases with post op BCVA of 6/18 to 6/16 had normal fundus. 3 (60%) cases out of 5 with BCVA less than 6/60 had severe to advanced optic disc changes. ($\chi^2 = 15.34$, $p = 0.004$). In the study, BCVA post-operatively was better than 6/60 in 11 cases who presented with IOP less 40mmHg and none of them had BCVA less than 6/60. In cases who presented with IOP of more than 40 mmHg, poor vision of less than 6/60 was seen in 5 cases, which was clinically significant but not statistically.

4. Discussion

Cataract has been documented to be the most common cause of bilateral blindness in India.^{7–11} Lens induced glaucoma is one of the main important cause of vision loss in developing country, mainly due to lack of awareness regarding treatment of cataract and inaccessibility to the health care of village population. It mostly affects the lower socio economic class and people living in remote area. In spite of easy availability of surgical facilities with effect of the National Programme for Control of Blindness (NPCB), NGOs, government agencies, and private practitioners, cataract surgery being a very cost effective and rewarding surgery, still many people are becoming blind due to lack of awareness about significance of early management.

In the study, mean age of presentation in phacomorphic glaucoma was 67.25 ± 6.58 years, ranging from 48 years to 75 years. In phacolytic glaucoma mean age was 64.10 ± 9.78 ranging from 45 years to 84 years. Most frequent age group was 61 to 70 years. In a study conducted by Pradhan et al. on 413 patients in Nepal showed mean age of presentation was under 60 years of age.⁵ Another study conducted in Eastern Nepal also showed mean age as 63 ± 10 years.¹⁵ This is similar to a study conducted in South Indian population by Ramakrishna et al.¹² and another study conducted on North- eastern India by Vidyanani Rajkumari et al.¹⁶ Another study conducted in Maharashtra rural population by Raghunandan et al. showed mean age of 68.84 years.⁸ In the study, mean IOP at presentation was $42.6 \text{ mmHg} \pm 5.36$ with the minimum value of 30 mmHg and maximum of 52 mmHg. Most frequent IOP was in the range

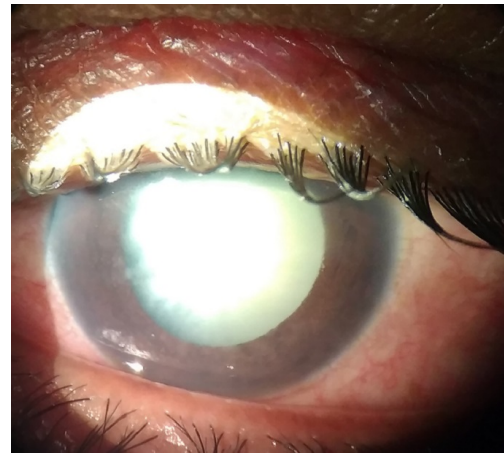

Figure 1: Phacomorphic glaucoma

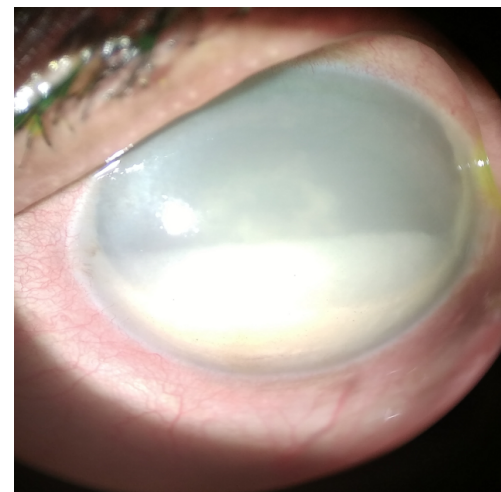


Figure 2: Phacolytic glaucoma

of 46 – 50 mmHg. Intra ocular pressure was controlled in our patients with intravenous mannitol and oral acetazolamide. In a study done by Sitoula RP et al,¹⁵ mean IOP at the presentation was $39 \text{ mmHg} \pm 10$. Similarly study done by Pradhan et al⁵ showed that more than 30 mmHg of IOP was seen in 79% of patients. Most of the study showed that IOP at presentation was more than 30 mmHg. This shows that patients develop acute symptoms after IOP is more than 30 mmHg in such cases. 67.5% (27) cases successfully underwent SICS with PCIOL implantation and in 20% (8) cases surgical peripheral iridectomy was done to augment IOP control. 5 cases out of 40 had posterior capsular rent and vitreous loss, among them, 2 patients received PCIOL implantation in sulcus, while other 3 cases were taken up for SFIOL implantation later date. In one of the study done by Moraru et al, phaco emulsification was tried in all the 25 cases of the study, but in 13 cases they converted it into SICS due to hard nucleus and intra operative difficulties.¹⁷ In one more study done by Senthil et al, found that though

Table 7: Comparison with other studies

BCVA	Pradhan et al ⁷	Ramakrishnan et al ¹²	Rajkumari et al ¹	JMY Lee et al ¹³	Yaakub A et al ¹⁴
6/6- 6/18	33%	68%	70.77%	16%	63.9%
6/24-6/60	39%	20%	25.61%	66%	15.7%
<6/60	33%	12%	4.62%	18%	24.6%

cataract surgery alone and combined procedure of cataract surgery with trabeculectomy showed similar IOP control, however cataract surgery alone gave a better and faster visual recovery.¹⁸

Visual outcome in our study was studied at the end of 6 weeks of follow up. Visual acuity, IOP and optic disc changes were noted for all the patients. In our study, BCVA was better than 6/18 in 32.5% of patients, 6/24 – 6/60 in 55% of patients and 12.5% had BCVA less than 6/60. 5 patients who presented to us with IOP more than 40Hg had BCVA less than 6/60 and these patients had glaucomatous optic disc changes of CDR 0.8 to 1. Following table shows the comparison of various studies with respect to visual outcome (Table 7).^{13,14} IOP was controlled in almost all the patients post-operatively. Similar results have been shown in studies done by McKibbin et al.,¹⁹ Gurudeep Singh et al.²⁰ In a study done by Sitoula et al., they also found that 90% of cases had IOP less than 21mmHg post-operatively.^{15,21}

5. Conclusion

Our study demonstrated that lens induced glaucoma is still a challenging complication of cataract which can be prevented by early treatment of cataract. Study showed that condition is more common in females and pseudophakics. Patients presenting with high IOP at presentation and patients with advanced glaucomatous optic disc changes significantly affect the final visual outcome post-operatively. Proper evaluation for glaucoma is required in all the cases of lens induced glaucoma after cataract surgery. Most of the cases had better visual acuity after SICS in lens induced glaucoma and IOP came to control immediately after surgery. This shows that, SICS is still gold standard that effectively controls IOP and gives better visual outcome.

6. Source of Funding

None.

7. Conflict of Interest

None.

References

- Bartholomew RS, Rebello PF. Calcium oxalate crystals in the aqueous. *Am J Ophthalmol*. 1979;88(6):1026–8.
- Brooks A, Grant G, Gillies WE. Comparison of specular microscopy and examination of aspirate in phacolytic glaucoma. *Ophthalmology*. 1990;97(1):85–9.
- Brooks AM, Drewe RH, Grant GB, Billington T, Gillies WE. Crystalline nature of the iridescent particles in hypermature cataracts. *Br J Ophthalmol*. 1994;78(7):581–2.
- Angra SK, Pradhan R, Garg SP. Cataract induced glaucoma- an insight into management. *Indian J Ophthalmol*. 1991;39(3):97–101.
- Pradhan D, Hennig A, Kumar J, Foster A. A prospective study of 413 cases of lens-induced glaucoma in Nepal. *Indian J Ophthalmol*. 2001;49(2):103–7.
- Kusack JR, Brown HG. Embryology and anatomy of the lens. In: Albert DM, Jakobiec FA, editors. Principles and practice of ophthalmology. Saunders: Philadelphia; 1994. p. 82.
- Murthy G, Gupta SK, John N, Vashist P. Current status of cataract blindness and Vision 2020: the right to sight initiative in India. *Indian J Ophthalmol*. 2008;56(6):489–94.
- Thulasiraj RD, Nirmalan PK, Ramakrishnan R, Krishandas R, Manimekalai TK, Baburajan NP, et al. Blindness and vision impairment in a rural south Indian population: the Aravind Comprehensive Eye Survey. *Ophthalmology*. 2003;110(8):1491–8.
- Murthy GV, Gupta SK, Bachani D, Jose R, John N. Current estimates of blindness in India. *Br J Ophthalmol*. 2005;89(3):257–60.
- Thulasiraj RD, Rahamathulla R, Saraswati A, Selvaraj S, Ellwein LB. The Sivaganga eye survey: Blindness and cataract surgery. *Ophthalmic Epidemiol*. 2002;9(5):299–312.
- Murthy RP. Burden of cataract in developing countries. *Indian J Clin Exp Ophthalmol*. 2018;4(1):1.
- Ramakrishnan R, Maheshwari D, Kader MA, Singh R, Pawar N, Bharathi MJ. Visual prognosis, intraocular pressure control and complications in phacomorphic glaucoma following manual small incision cataract surgery. *Indian J Ophthalmol*. 2010;58(4):303–306.
- Lee JW, Lai JS, Yick DW, Tse RK. Retrospective case series on the long-term visual and intraocular pressure outcomes of phacomorphic glaucoma. *Eye (Lond)*. 2010;24(11):1675–80.
- Yaakub A, Abdullah N. Lens-induced glaucoma in a tertiary centre in northeast of Malaysia. *Malays Fam Physician*. 2014;9(2):48–52.
- Sitoula RP, Sarkar I, Nayak D, Singh SK. Lens induced glaucoma: An experience in tertiary eye care center in eastern Nepal. *Nepal J Ophthalmol*. 2016;8(16):161–6.
- Rajkumari V, Kaminibabu KS, Bhabanisana RD, Victor R. Manual Small Incision Cataract Surgery in Phacomorphic Glaucoma: Surgical Technique and Outcome in North-eastern India. *J Curr Glaucoma Pract*. 2013;7(2):43–8.
- Moraru A, Pinzaru G, Moțoc A, Costin D. Functional results of cataract surgery in the treatment of phacomorphic glaucoma. *Rom J Ophthalmol*. 2017;61(3):202–6.
- Senthil S, Chinta S, Rao HL, Choudhari NS, Pathak-Ray V, Mandal AK, et al. Comparison of Cataract Surgery Alone Versus Cataract Surgery Combined With Trabeculectomy in the Management of Phacomorphic Glaucoma. *J Glaucoma*. 2016;25(3):e209–13.
- McKibbin M, Gupta A, Atkins AD. Cataract extraction and intraocular lens implantation in eyes with phacomorphic or phacolytic glaucoma. *J Cataract Refract Surg*. 1996;22(5):630–6.
- Singh G, Kaur J, Mall S. Phacolytic glaucoma - Its treatment by planned extracapsular cataract extraction with posterior chamber intra ocular lens implantation. *Indian J Ophthalmol*. 1994;42(3):145–7.
- Zhang J, Guo L, Wang L. A study on the treatment of secondary glaucoma due to intumescent senile cataract. *Zhonghua Yan Ke Za Zhi*. 2001;37(5):359–62.

Author biography

Vinuta Mohan Kulkarni, Senior Resident

Nishat Sultana, Professor

Abdul Rauf Abid, Senior Resident

Cite this article: Kulkarni VM, Sultana N, Abid AR. Lens induced glaucoma – Clinical profile and prognosis in tertiary care centre. *Indian J Clin Exp Ophthalmol* 2023;9(4):587-592.