

Content available at: <https://www.ipinnovative.com/open-access-journals>

Indian Journal of Clinical and Experimental Ophthalmology

Journal homepage: www.ijceo.org

Original Research Article

Post operative opacification of polymethylmethacrylate, hydrophilic and hydrophobic acrylic intraocular lenses: A retrospective observational study

Shivcharan Lal Chandravanshi¹, Divya Ramraika^{2,*}, Pradeep Kumar², Arun Agrawal³¹Dept. of Ophthalmology, Shyam Shah Medical College, Rewa, Madhya Pradesh, India²Dept. of Ophthalmology, Hindu Rao Hospital, New Delhi, India³Private Practitioner, Rewa, Madhya Pradesh, India

ARTICLE INFO

Article history:

Received 30-10-2022

Accepted 26-11-2022

Available online 30-03-2023

Keywords:

Acrylic intraocular lenses

Opacification

Polymethylmethacrylate

ABSTRACT

Aim: To evaluate post-operative opacification of hydrophobic, hydrophilic and polymethylmethacrylate intraocular lenses.**Materials and Methods:** We had performed a retrospective observational study on twenty-one patients in tertiary care hospital of North India and a private clinic from March 2020-January 2021. History of systemic diseases like diabetes mellitus, hypertension, gout, chronic obstructive pulmonary disease was noted. We had also evaluated the patients for ophthalmic conditions like recurrent uveitis, retinal surgery, paracentesis for hyphema, open globe injury repair. The diagnosis of intraocular lens opacification was made on careful slit lamp examination. The patients with severe loss of visual acuity had undergone intraocular lens exchange procedure. The explanted intraocular lenses were sent for light microscopy with special stain and scanning electron microscopy. Statistical analysis was performed using SPSS software, version 21 (SPSS, Inc.)**Results:** We found that mean age of patients with intraocular lens opacification was 62.5±6.82 years. The occurrence was 16(76.19%) in hydrophilic IOL, 4(19.05%) in hydrophobic IOL and only one (4.76%) was PMMA IOL which showed that the occurrence of IOL opacification is more in hydrophilic IOL. Light microscopy and scanning electron microscopy of the explanted IOLs did not show any deposits over IOL surface. Special stains were used and it was noted that Alizarin red was positive while Von Kossa for calcium was negative.**Conclusion:** We concluded that intraocular lens opacification can occur in any type of intraocular lens, but is predominantly seen with hydrophilic acrylic intraocular lenses. Also we came to a conclusion that various ophthalmic pathologies and systemic comorbidities accelerated the process of opacification.This is an Open Access (OA) journal, and articles are distributed under the terms of the [Creative Commons Attribution-NonCommercial-ShareAlike 4.0 License](https://creativecommons.org/licenses/by-nc-sa/4.0/), which allows others to remix, tweak, and build upon the work non-commercially, as long as appropriate credit is given and the new creations are licensed under the identical terms.For reprints contact: reprint@ipinnovative.com

1. Introduction

Sir Harold Ridley used polymethylmethacrylate(PMMA) optic biomaterial in his original intraocular lens which was manufactured by Rayner intraocular lenses limited, London, England and was first implanted in 1949.¹⁻³ PMMA was declared as a safe biomaterial by the late

1980s. Whereas in mid 1990s it was found that PMMA optic biomaterial had some gradual, progressive late postoperative alteration which may sometimes require an IOL explantation 'or' exchange. On examination, snow flake degeneration was noted in the PMMA polymer.⁴ Here we studied the opacification of intraocular lenses. The most common surgical procedure for removal of cataract is phacoemulsification. This phacoemulsification

* Corresponding author.

E-mail address: drdivyaramraika@gmail.com (D. Ramraika).

technique had brought in the use of foldable intraocular lens made of hydrophilic 'or' hydrophobic materials.⁵ Intraocular lens (IOL) opacification is an extremely rare unilateral or sometime bilateral IOL related complication and may be seen on the surfaces (anterior, posterior or both). It maybe related to the material of the optic, haptics, or whole lens.⁵ Leading causes of clinically significant IOL opacification are calcification and snow flake degeneration.⁶ IOL opacification is mainly caused by calcification. Calcification of IOL may be of primary or secondary type. In literature, calcium phosphate is the most common cause of IOL opacification. Calcium phosphate formation is attributed to the material used in manufacture of IOL and local chemical microenvironment of the aqueous humor in contact with the IOL. Primary calcification is associated with the problems of IOL itself without the presence of other significant causes.⁷ Secondary calcification of IOL is seen in diabetics, patients with uveitis and following vitreoretinal or keratorefractive surgeries.⁷ Patients usually present to the ophthalmologist with the complaints of diminution of vision. Intraocular lens exchange is the universally accepted and safe procedure to restore vision for such patients. Snowflake opacification is a slowly progressive opacification of polymethylmethacrylate (PMMA) IOLs due to prolonged exposure of ultraviolet radiation and had been observed in PMMA IOL implanted in 80s and 90s.⁴ Here in this study, we studied the opacification of polymethylmethacrylate (PMMA), hydrophobic and hydrophilic acrylic intraocular lenses, since the opacification is mostly primary, which totally depends on the manufacture of IOL whereas secondary calcification is mainly attributed to the patient's medical and ocular condition. We studied IOL opacification in patients with and without systemic diseases so as to find out whether the opacification is more common in patients with systemic diseases. We also studied IOL opacification in males and females, as environmental factors may also attribute to the opacification, as most males work outside the home.

So we studied the IOL opacification in different types of IOL, associated systemic diseases and different genders.

2. Materials and Methods

A retrospective observational study was conducted in twenty-one eyes of twenty-one patients in a tertiary care hospital of North India and private clinic from March 2020 – January 2021. Written informed consent was taken from all the patients. Ethical clearance was taken from the local ethical committee and protocol adhered to the declaration of Helsinki. Patients with unilateral IOL opacification were included in the study. Data was collected, with an emphasis on associated ocular conditions like recurrent uveitis, retinal surgery with 'or' without silicone oil exchange, paracentesis for hyphema, open globe

injury repair and systemic conditions like diabetes mellitus, hypertension, gout, chronic obstructive pulmonary disease. Also, duration of cataract surgery and duration of symptoms like loss of visual acuity. Preoperative ophthalmologic evaluation included best corrected visual acuity, slit lamp biomicroscopy and fundus evaluation.

The diagnosis of IOL opacification was based on careful slit lamp examination (Figures 1, 2, 3 and 4). The duration between first cataract surgery and symptoms was noted. Evidence of Nd-YAG capsulotomy was also observed during slit lamp examination. The patients with severe loss of visual acuity and opacification of the IOL underwent IOL exchange procedure. Approximately 6 mm of scleral incision was made and opacified IOL was removed after splitting the opacified IOL into two parts with the help of vannas scissor, the capsule was separated from IOL using viscoelastic material and post operative hydrophobic IOL was implanted in most of the patients along with PMMA IOL and PMMA anterior chamber IOL (ACIOL) in few patients. The patients with Nd-YAG capsulotomy underwent anterior vitrectomy as an additional procedure and PMMA ACIOL was implanted as due the rent created as a result of Nd YAG there was vitreous coming after the IOL was explanted. Explanted IOLs (Figure 5) were sent for light microscopy with special stain for calcium and scanning electron microscopy. The explanted IOLs were dried and then dipped in 1% fluorescein dye and observed under microscope. We found that hydrophilic IOLs stain intensively with fluorescein dye. Post-operative period was uneventful. Patients underwent sequential follow-ups and a regular complete post-operative ophthalmologic evaluation was done. The evaluation included best corrected post operative visual acuity, slit lamp biomicroscopy, tonometry and fundus evaluation. Since most of the patients we had included in the study did not have discharge cards the trade name of the IOL implanted cannot be specified. We performed statistical analysis using Statistical Package for Social Sciences (SPSS software, version 21, SPSS, Inc.)

3. Results

The study aimed to find the IOL opacification in different types of IOL, associated systemic diseases and different genders. The mean preoperative visual acuity was 0.88 ± 0.17 and postoperative best corrected distance visual acuity in log MAR was 0.22 ± 0.24 , which showed a drastic improvement in the visual acuity after explantation. The mean age was 62.5 ± 6.82 years. The females whose IOL showed opacification were 6 (28.57%) as compared to males which were 15 (71.43%). The total opacified IOLs included in this study were 21 out of which the occurrence was 16 (76.19%) in hydrophilic IOL, 4 (19.05%) in hydrophobic IOL and only one (4.76%) was PMMA IOL which showed that the occurrence of IOL opacification is more in hydrophilic IOL.

The duration between cataract surgery and symptoms in PMMA IOL was six months and mean duration between cataract surgery and presentation in hydrophilic and hydrophobic IOL is shown in Table 1.

Table 1: Parameters table along with mean and standard deviation

S.No.	Parameters	Mean±SD
1.	Pre operative visual acuity (logMAR)	0.88±0.17
2.	Post operative visual acuity (logMAR)	0.22±0.24
3.	Age (in years)	62.5±6.82
4.	Duration between cataract surgery and presentation in females	10.83±11.49
5.	Duration between cataract surgery and presentation in males	9.60±10.80
6.	Duration between cataract surgery and presentation in hydrophobic IOL (in months)	9.43±10.80
7.	Duration between cataract surgery and presentation in hydrophobic IOL (in months)	13±12.80
8.	Duration between cataract surgery and presentation without systemic disease (in months)	11.42±12.58
9.	Duration between cataract surgery and presentation with systemic disease (in months)	8.50±9.46

Ophthalmic diseases were present in patients, three patients had recurrent uveitis, one had open globe injury repair, one had undergone paracentesis for hyphema, three had undergone retinal surgery with silicone oil exchange. The most common ophthalmic complications were recurrent uveitis and retinal surgery with silicone oil exchange. A positive systemic medical history was present in fourteen (66.67%), most frequently the systemic disease which occurred was systemic hypertension which occurred in 5(23.08%), diabetes mellitus which occurred in 4(19.05%), combined diabetes mellitus and arterial hypertension occurred in three(14.29%), gout in one(4.76%) and chronic obstructive pulmonary disease in one(4.76%). Three patients had no significant medical history nor any ophthalmic pathology.

There were 7(33.33%) patients of IOL opacification who did not have any history of systemic disease whereas 14(66.67%) patients with systemic disease showed the IOL opacification which showed that the occurrence of IOL opacification is more in the patients with systemic diseases as compared to those without any systemic diseases. Light microscopy and scanning electron microscopy of the explanted IOLs did not show any deposits over IOL surface. Special stains, Alizarin red was positive while Von Kossa for calcium was negative for all the lenses.

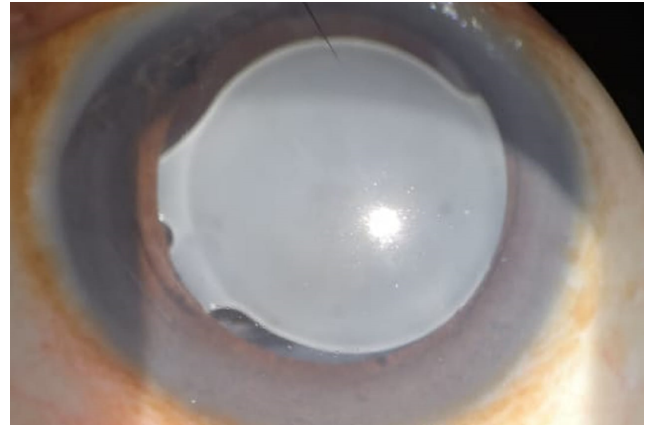


Fig. 1: Slit lamp photograph depicting opacification of hydrophobic intraocular lens




Fig. 2: A): Slit lamp examination showing opacification of polymethylmethacrylate intraocular lens; B): Slit lamp photograph showing anterior and posterior surface opacification of optics of polymethylmethacrylate intraocular lens with clear intermediate area of optics in optical section




Fig. 3: Slit lamp photograph showing total opacification of hydrophilic intraocular lens optics in optical section

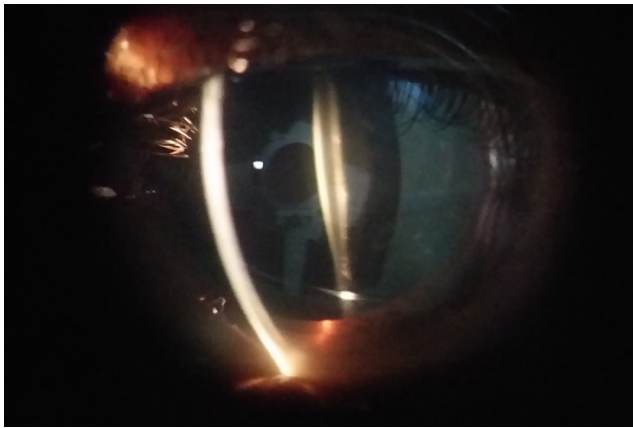

Fig. 4: Slit lamp photograph showing opacification of anterior and posterior surface of optics with clear intermediate area of optics of hydrophilic intraocular lens in optical section

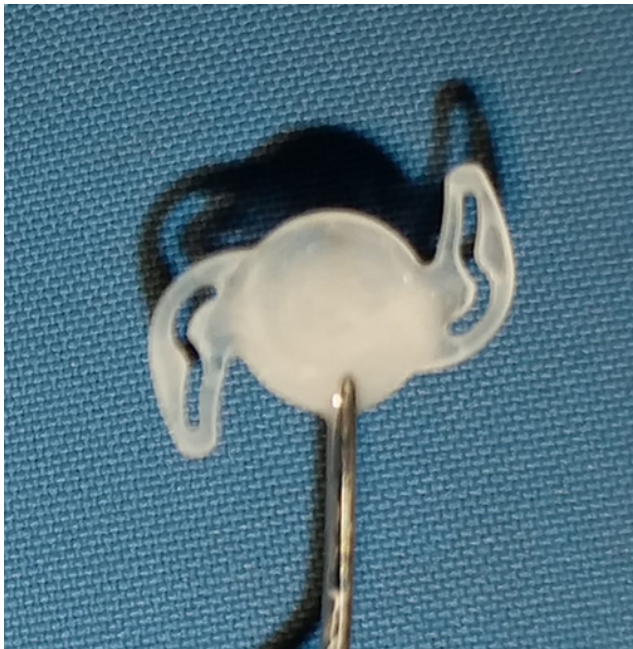

Fig. 5: Explanted intraocular lens showing opacification of hydrophilic intraocular lens

4. Discussion

IOL opacification is an extremely rare late postoperative complication after cataract surgery with IOL implantation. IOL opacification usually occurs in the late postoperative period in hydrophilic IOLs. IOL opacification in Hydroview IOLs after cataract surgery was first reported by Chang et al.⁸ in 1999.

In our study the mean age of patients at the time of cataract surgery with IOL implantation was 62.5 years ± 6.92 and range was 45–72 years whereas in the study by Bompastor-Ramos P et al.⁹ was 73.47 years ± 9.64 i.e.

range of 53 to 91 years. In our study IOLs explanted from six (28.57%) females and 15 (71.43%) males whereas in the study by Bompastor-Ramos P et al.⁹ the IOLs were explanted from 10 (52.63%) females and 9 (43.37%) males.

Our study aimed to find the occurrence of opacification and correlate it with the type of IOL and we found that occurrence of IOL opacification was mostly seen with the hydrophilic acrylic intraocular lenses i.e. 76.19%, which was consistent with the findings of a study done by Bompastor-Ramos P et al.⁹ whereas in hydrophilic acrylic intraocular lenses opacification was 19.05% and it was 4.76% in PMMA IOL. Bompastor-Ramos P et al.⁹ reported the primary calcification in explanted LENTIS ls-502-1 IOLs, which were hydrophilic IOLs with hydrophobic coating which was consistent with our study, where we found the occurrence of calcification mostly in the hydrophilic intraocular lenses. The mean interval between the first cataract surgery and diagnosis of opacification in hydrophilic IOLs was 9.43 ± 10.80 months whereas in hydrophobic IOLs it was 13 ± 12.80 months. The mean interval between first cataract surgery and diagnosis of opacification was lesser than the study done by Bompastor-Ramos P et al.⁹ and Neuhann et al.⁷ in which the mean duration between implantation of IOL and diagnosis of opacification was 29.5 ± 9.5 months and 25.8 ± 11.9 months respectively. In our study the occurrence of calcification was mostly in the patients with systemic diseases which was 14 (66.67%) and it was not consistent with the study done by Bompastor-Ramos P et al.⁹ which showed the IOL opacification in absence of systemic disease whereas calcification in our study occurred in patients with systemic diseases which was secondary IOL opacification. In a study done by Neuhann et al.⁷ the major ophthalmic and medical conditions associated with opacification were glaucoma and diabetes respectively. Tehrani M et al.¹⁰ reported six cases of Memory lens IOLs (Ciba Vision) opacification approximately two years after implantation.

The incidence of IOL opacification ranges from 1.1% to 14.5% depending on risk factors in the patient.¹¹ Duration of IOL opacification ranged from 10 minutes after the surgery to seven years or more.^{12,13}

Silicone, acrylic, and polymethylmethacrylate (PMMA) IOL have been reported to opacify. Hydrophilic IOLs have more tendency of opacification in comparison with hydrophobic IOLs as primary calcification occurs more in hydrophilic IOLs as compared with hydrophobic IOLs. Patients with IOL opacification usually present with complaints of gradual painless loss of vision after cataract surgery with IOL implantation, decreased contrast and glare. Sometimes the patient may also present with leucocoria, poor vision in dim light and hazy or foggy vision.

Three major types of calcification were described by Neuhann et al.⁷ which were primary, secondary and

false positive i.e. pseudocalcification. The calcification that permeates into IOL substance is correlated to the IOL itself 'or' its packaging process is known as primary calcification. When the calcification is on the surface of the IOL and is related to preexisting and surgery related factors which resulted in breakdown of blood aqueous barrier, then it is known as secondary calcification. False positive calcification is defined in those cases in which the other pathology is mistaken for calcification 'or' there is false positive staining for calcium, it occurs because of faulty use of special stains, it also includes the cases in which there were remnants of dried viscoelastic materials, balanced salt solution that were deposited on the surface of IOLs.

Various risk factors for IOL opacification have been described in the literature such as diabetes, uveitis, asteroid hyalosis, breakdown of blood aqueous barrier intraoperatively, plana vitrectomy (PPV), penetrating keratoplasty, Descemet membrane endothelial keratoplasty (DMEK) with intraocular gas or air injection and Descemet stripping (automated) endothelial keratoplasty (DSEK/DSAEK).^{12–17}

The mechanism of IOL opacification is not well-established. In a biological environment, the degradation of a polymer is universal and results from the enzymatic attack or from hydrolysis. Water gets absorbed in aqueous media and induced simple chemical hydrolysis of the hydrostatically unstable polymer bond which results in cleaving 'or' hydrolytic chain scission and the long polymer converted into water-soluble fragments with the polymer dissolution and surface erosion. This produces cracks and pores in the polymer. The chemical stability of the polymer bond, the hydrophilic/hydrophobic balance, morphology, molecular weight, molecular distribution of the polymer and solubility of the low molar mass degradation product determines the rate of erosion.^{18–22} In the IOL polymer, the ultraviolet absorbing compounds, low molecular weight additives, bland 'or' co-monomer were covalently integrated. Electromagnetic wave present in ultraviolet light can degrade the bond and change the property of IOL polymer.^{19,22} Various mechanisms have been proposed by numerous researchers. Different patterns of IOL opacification were noted in different IOL substances such as snowflake opacification in PMMA IOLs, discoloration/clouding in silicone IOLs, calcification (hydroxyapatite, dicalcium phosphate, octacalcium phosphate, or hydroxyapatite deposition) in hydrophilic acrylic IOLs and glistening or subsurface nanoglistenings in hydrophobic acrylic IOLs. Bhattacharjee H et al.²³ described the delayed postoperative opacification of three hydrophobic acrylic intraocular lens using scanning electron microscopic and energy dispersive spectroscopic study which demonstrated primary calcification in hydrophobic acrylic IOLs. This was consistent with our study, as we had demonstrated the opacification in

hydrophilic, hydrophobic and PMMA IOLs. Werner L et al.²¹ reported the postoperative opacification of two hydrophilic acrylic biomaterial and the polymer source was SC60B-SUV design, Vista Optics after which the manufacturer had withdrawn all the IOLs from this polymer. They could not establish a correlation between the opacification and diabetes although few patients were diabetic. The symptoms started around twenty-four months after the initial cataract surgery and most of the lenses were explanted after twenty-four months. The explanted IOLs were examined grossly and microscopically and Alizarin red and Von Kossa stainings were performed for calcium. The granules in the IOL were distributed in a line parallel to the anterior and posterior curvatures of the optics, and they stained positive with Alizarin Red. This was consistent with our study where explanted IOLs stained positive for Alizarin Red, in their study Von Kossa stain was also positive which was negative in our study.

Diagnosis of IOL opacification was easily made by slit-lamp biomicroscopy. Anterior segment optical coherence tomography was helpful in detection of IOL-capsular bag adhesions. Scanning laser electron microscopy and X-ray diffraction examination of an explanted IOL was helpful in understanding the mechanism of IOL opacification. Both techniques showed depositions of calcium over IOL surface. Sometimes it mimicked a lamellar cataract. Von Kossa's stain was useful in IOL surface calcification while Alizarin red was used for whole IOL material calcification.^{17,24–26} Explanation of an opacified IOL and reimplantation of new IOL of different material was the procedure of choice for treatment of opacified IOL at present. However, IOL exchange procedure may become risky in patient who had undergone Nd-YAG laser capsulotomy in the past. In such cases, capsular bag damage, complete dehiscence of bag, vitreous prolapse, zonular dehiscence, IOL drop, IOL decentration are common complications. Scleral fixated IOL, anterior chamber IOL, sutured iris fixated IOL, iris claw IOLs and retro-pupillary iris claw IOL are also other viable options in case of capsular bag damage/dehiscence. From the previous literatures, no other study had demonstrated the opacification in PMMA IOLs to the best of our knowledge, they had described the snowflake opacification of three-piece PMMA IOLs.

The majority of IOL exchange procedures have excellent post-operative visual outcome if posterior segment is healthy.

5. Conclusion

Our study concluded that intraocular lens opacification was a slow procedure which was due to the degradation of the polymer which took place due to the microenvironment of the eye in which the IOL was placed and it was a slow and ongoing procedure and can take place in any of the lens biomaterial whether PMMA, hydrophilic or

hydrophobic. However, it was mostly seen with hydrophilic IOLs. We saw various ocular and systemic comorbidities were correlated with the opacification process by which we came to a conclusion that certain comorbidities may accelerate the procedure of opacification. Nowadays since cataract surgery is the most commonly performed surgery with phacoemulsification being the procedure of choice, the surgeon as well as the manufacturer must be aware that opacification is a possible complication and should report immediately the opacification of the particular batch of lenses which may help the patient as well as the surgeon and also other patients.

6. Source of Funding

None.


7. Conflict of Interest

None.

References

- Ridley H. Intraocular acrylic lens. *Trans Ophthalmol Soc UK*. 1951;71:617–21.
- Ridley NHL. Artificial intraocular lenses after cataract extraction. *St Thomas Hosp Rep*. 1951;7:12–4.
- Apple DJ, Sims J. Harold Ridley and the invention of the intraocular lens. *Surv Ophthalmol*. 1996;40(4):279–92.
- Apple DJ, Peng Q, Arthur SN, Werner L, Merritt JH, Vargas LG, et al. Snowflake degeneration of polymethyl methacrylate posterior chamber intraocular lens optic material: A newly described clinical condition caused by unexpected late opacification of polymethyl methacrylate. *Ophthalmology*. 2002;109(9):1666–75.
- Gartaganis SP, Kanellopoulou DG, Mela EK, Panteli VS, Koutsoukos PG. Opacification of hydrophilic acrylic intraocular lens attributable to calcification: investigation on mechanism. *Am J Ophthalmol*. 2008;146(3):395–403.
- Werner L. Causes of intraocular lens opacification or discoloration. *J Cataract Refract Surg*. 2007;33(4):713–26.
- Neuhann IM, Werner L, Izak AM, Pandey SK, Kleinmann G, Mamalis N, et al. Late postoperative opacification of a hydrophilic acrylic (hydrogel) intraocular lens: a clinicopathological analysis of 106 explants. *Ophthalmology*. 2004;111(11):2094–101.
- Chang BYP, Davey KG, Gupta M, Hutchinson C. Late clouding of an acrylic intraocular lens following routine phacoemulsification. *Eye (Lond)*. 1999;13(Pt 6):807–8.
- Bompastor-Ramos P, Póvoa J, Lobo C, Rodriguez AE, Alió JL, Werner L, et al. Late postoperative opacification of a hydrophilic-hydrophobic acrylic intraocular lens. *J Cataract Refract Surg*. 2016;42(9):1324–31.
- Tehrani M, Mamalis N, Wallin T, Dick HB, Stoffelns BM, Olson R, et al. Late postoperative opacification of MemoryLens hydrophilic acrylic intraocular lenses: case series and review. *J Cataract Refract Surg*. 2004;30(1):115–22.
- Balasubramaniam C, Goodfellow J, Price N, Kirkpatrick N. Opacification of the Hydroview H60M intraocular lens: total patient recall. *J Cataract Refract Surg*. 2006;32(6):944–8.
- Kubaloglu A, Sari ES, Koytak A, Cinar Y, Erol K, Ozerturk Y. Intraocular lens exchange through a 3.2-mm corneal incision for opacified intraocular lenses. *Indian J Ophthalmol*. 2011;59(1):17–21.
- Rahimi M, Azimi A, Hosseinzadeh M. Intraocular Lens Calcification: Clinico-pathological Report of Two Cases and Literature Review. *J Ophthalmic Vis Res*. 2018;13(2):195–9.
- Grzybowski A, Markeviciute A, Zemaitiene R. A narrative review of intraocular lens opacifications: update 2020. *Ann Transl Med*. 2020;8(22):1547.
- Walker NJ, Saldanha MJ, Sharp JA, Porooshani H, McDonald BM, Ferguson DJ, et al. Calcification of hydrophilic acrylic intraocular lenses in combined phacovitrectomy surgery. *J Cataract Refract Surg*. 2010;36(8):1427–31.
- Ma ST, Yang CM, Hou YC, Hou YC. Postoperative intraocular lens opacification. *Taiwan J Ophthalmol*. 2018;8(1):49–51.
- Dhital A, Spalton DJ, Goyal S, Werner L. Calcification in hydrophilic intraocular lenses associated with injection of intraocular gas. *Am J Ophthalmol*. 2012;153(6):1154–60.
- Özyol P, Özyol E, Karel F. Biocompatibility of Intraocular Lenses. *Türk J Ophthalmol*. 2017;47(4):221–5.
- Rydz J, Šišková A, Eckstein AA. Scanning Electron Microscopy and Atomic Force Microscopy: Topographic and Dynamical Surface Studies of Blends, Composites, and Hybrid Functional Materials for Sustainable Future. *Adv Mater Sci Eng*. 2019;doi:10.1155/2019/6871785.
- Pérez-Vives C. Biomaterial influence on intraocular lens performance: An overview. *J Ophthalmol*. 2018;2018:268735. doi:10.1155/2018/2687385.
- Werner L. Biocompatibility of intraocular lens materials. *Curr Opin Ophthalmol*. 2008;19(1):41–9.
- Rydz J. Forensic engineering of advanced polymeric materials. Part 1 -Degradation studies of polylactide blends with atactic Poly. *Chem Biochem Eng Q*. 2015;29:247–59.
- Bhattacharjee H, Buragohain S, Javeri H, Das D, Bhattacharjee K. Delayed postoperative opacification of three hydrophobic acrylic intraocular lens: A scanning electron microscopic and energy dispersive spectroscopic study. *Indian J Ophthalmol*. 2021;69(5):1103–7.
- Purbrick RMJ, Stavarakas P, Porooshani H, Patel CK, Ferguson DJP. Calcification of a Rayner Centerflex 570H hydrophilic acrylic intraocular lens following vitrectomy for retinal detachment: a clinicopathologic report. *Eur J Ophthalmol*. 2010;20(6):1082–5.
- Walker NJ, Saldanha MJ, Sharp JAH, Porooshani H, McDonald BM, Ferguson DJP. Calcification of hydrophilic acrylic intraocular lenses in combined phacovitrectomy surgery. *J Cataract Refract Surg*. 2010;36(8):1427–31.
- Lee SJ, Choi JH, Sun HJ, Choi KS, Jung GY. Surface calcification of hydrophilic acrylic intraocular lens related to inflammatory membrane formation after combined vitrectomy and cataract surgery. *J Cataract Refract Surg*. 2010;36(4):676–81.

Author biography

Shivcharan Lal Chandravanshi, Associate Professor (Designate)  <https://orcid.org/0000-0001-5105-7275>

Divya Ramraika, Senior Resident  <https://orcid.org/0000-0001-5670-2608>

Pradeep Kumar, Senior Resident

Arun Agrawal, Private Practitioner (Ophthalmology)

Cite this article: Chandravanshi SL, Ramraika D, Kumar P, Agrawal A. Post operative opacification of polymethylmethacrylate, hydrophilic and hydrophobic acrylic intraocular lenses: A retrospective observational study. *Indian J Clin Exp Ophthalmol* 2023;9(1):97–102.