

Content available at: <https://www.ipinnovative.com/open-access-journals>

Indian Journal of Clinical and Experimental Ophthalmology

Journal homepage: www.ijceo.org

Original Research Article

Impact of cataract surgery on intraocular pressure

Adipudi Ramya^{1,*}, Usha B R¹¹Dept. of Ophthalmology, Sri Devaraj Urs Medical College, Kolar, Karnataka, India

ARTICLE INFO

Article history:

Received 09-12-2022

Accepted 05-01-2023

Available online 30-03-2023

Keywords:

Manual small incision cataract surgery

Intraocular pressure

ABSTRACT

Aim: To assess the impact of cataract surgery on intraocular pressure.**Materials and Methods:** A study comprising of 60 patients from the district of Kolar, who underwent Manual small incision cataract surgery were examined with Goldmann applanation tonometer for assessment of intraocular pressure before surgery and 1 week, 1 month after surgery along with visual acuity assessment, anterior segment evaluation with slit lamp biomicroscopy, posterior segment evaluation using indirect ophthalmoscopy.**Results:** 60 participants were included in the study, of whom 27 (45%) were female and 33 (55%) were male. The mean age of the patient was 64.2 years, with the maximum number of patients being in the age group of 61-70 (51.7%). The mean of intraocular pressure in pre-operative patients was 15.18 mmHg, after manual small incision cataract surgery at 1 week, it showed 11.96 mmHg and after 1 month showed 12.75 mmHg.**Conclusion:** The intra ocular pressure decreases significantly after manual small incision cataract surgery more so in female patients than male patients.This is an Open Access (OA) journal, and articles are distributed under the terms of the [Creative Commons Attribution-NonCommercial-ShareAlike 4.0 License](https://creativecommons.org/licenses/by-nc-sa/4.0/), which allows others to remix, tweak, and build upon the work non-commercially, as long as appropriate credit is given and the new creations are licensed under the identical terms.For reprints contact: reprint@ipinnovative.com

1. Introduction

According to a research published by the World Health Organization (WHO), cataracts are the most prevalent cause of blindness, accounting for 47.8 percent of cases. Cataract surgery is also the most common type of ocular surgery, accounting for 98 percent of all cases. The preferred procedure is manual small incision cataract surgery (MSICS).¹

The aqueous secretion and outflow, as well as the integrity of the sclera and the cornea, all contribute to the maintenance of intraocular pressure (IOP), which has a typical range of 10 mmHg to 21 mmHg.²

Manual small-incision cataract surgery (MSICS) is thought to be economical, secure, and have a favourable optical outcome.³ The cataractous nucleus is delivered out

and an intraocular lens is inserted during MSICS through a 6 mm scleral incision. This leads to an alteration of scleral stiffness that can influence Intraocular pressure.

The eye might suffer negative repercussions from fluctuations in IOP. There is a substantial risk of retinal and choroidal ischemia if there are high IOP fluctuations or an increase in IOP. Post-operative choroidal effusion or haemorrhage occurs if there is a reduction in IOP.⁴ The objective of this study is to monitor the changes in intraocular pressure (IOP) in individuals who have previously undergone manual small incision cataract surgery.

* Corresponding author.

E-mail address: aramya.2710@gmail.com (A. Ramya).

2. Materials and Methods

2.1. Study design

This is a prospective study which includes 60 patients of either sex and all ages above 40 years admitted in a tertiary care institute in Kolar District between May 2021 to May 2022. All known patients who underwent uneventful manual small incision cataract surgery attending ophthalmology department consecutively recruited for the study.

All consecutive patients attending R L Jalappa Hospital Ophthalmology OPD fulfilling the inclusion criteria were included in the study. Evaluation of the patient with detailed history regarding their complaints was taken. The complete ophthalmic evaluation was done including visual acuity assessment, type of cataract, grading of nuclear sclerosis done by slit lamp biomicroscopy, pupillary reaction, Anterior chamber depth assessment and posterior segment evaluation done using 20D/90D Indirect ophthalmoscopy. Intraocular pressure was recorded using a Goldmann applanation tonometer at pre- operative, post-operative 1 week and 1 month.

2.2. Inclusion and exclusion criteria

Inclusion criteria for the patients were: 1) Patients who underwent uneventful cataract surgery. Exclusion criteria were: 1) Glaucoma 2) ocular infections 3) ocular surgery.

2.3. Goldmann applanation tonometry

Topical 4% xylocaine anaesthesia is applied to the patient, after which fluorescein stain 2% is applied to the patient's eye. The patient is placed in front of the slit lamp and under a cobalt blue filter when the prism touches the apex of the cornea two menisci are formed which is approximated and the reading is taken to assess the intraocular pressure.

2.4. Manual small incision cataract surgery

Pre-operatively ciprofloxacin 0.3% is instilled with flurbiprofen eye drops 4 times per day. The pupil was dilated with tropicamide (0.8%) and phenylephrine (5%) eye drops to facilitate lens removal. The peribulbar anaesthesia with 3 ml of 2% xylocaine infiltrated along with hyaluronidase (1500 IU) and 2 ml of bupivacaine (0.5%) in a 5 ml syringe was administered to the patient. The operating eye is painted with 5% povidone iodine solution, a sterile drape is secured, and eyelids are separated with a Barraquer lid retractor. Superior rectus bridle suture is applied with the help of superior rectus muscle holding forceps, superior conjunctival peritomy was done, and 6 – 7 mm straight scleral incision is made 2-3 mm away from the superior limbus. A sclerocorneal tunnel is made with a crescent blade and extended 0.5 – 1mm into the cornea. A side port was made at 9 o clock position, air was injected and trypan blue dye (0.6%) is injected into

the anterior chamber under the air to stain the anterior capsule of the lens. The anterior chamber was entered with a help of a 3.2 mm keratome, Continuous curvilinear capsulorhexis was performed by Utrata forceps, hydro dissection within the lens matter and hydro delineation to separate the capsule from the cortex was done. The nucleus was prolapsed into the anterior chamber with the help of a lens dialer and delivered out of the anterior chamber by sandwich technique. Thorough cortical wash was given, and a polymethyl methacrylate single piece Intraocular lens was implanted in the capsular bag. The Visco elastic substance hydroxy methyl cellulose was washed out of the anterior chamber and a balanced salt solution (0.9%) was injected into the anterior chamber. Subconjunctival 0.5 ml Gentamycin with dexamethasone was injected. The eye was patched. An Oral Tablet Ciprofloxacin 500mg twice daily was given for three days. On postoperative day 1 Moxifloxacin (0.5%) with dexamethasone (0.1%) 8 times per day for one week, consequently tapering the dosage was advised.

2.5. Statistical analysis

Data was entered into a Microsoft excel data sheet and was analyzed using SPSS 22 version software. Categorical data was represented in the form of Frequencies and proportions. Continuous data was represented as mean and standard deviation.

P value (Probability that the result is true) of <0.05 was considered as statistically significant after assuming all the rules of statistical tests.

2.6. Statistical software

MS Excel, SPSS version 22 (IBM SPSS Statistics, Somers NY, USA) was used to analyze data.

3. Result

60 participants were included in the study, 27(45%) were females and 33 (55%) were males. The mean age of the patient was 64.2 years, with the maximum number of patients being in the age group of 61-70 (51.7%). The mean of intraocular pressure in pre-operative patients was 15.18 mmHg, after manual small incision cataract surgery at 1 week, it showed 11.96 mmHg and after 1 month showed 12.62 mmHg.

Table 1: Mean IOP in different sex

| | Female | Male |
|---|--------|-------|
| Pre operative mean IOP in mmHg | 14.37 | 15.72 |
| Post operative 1 week mean IOP in mmHg | 11.74 | 12.09 |
| Post operative 1 Month mean IOP in mmHg | 12.62 | 12.90 |

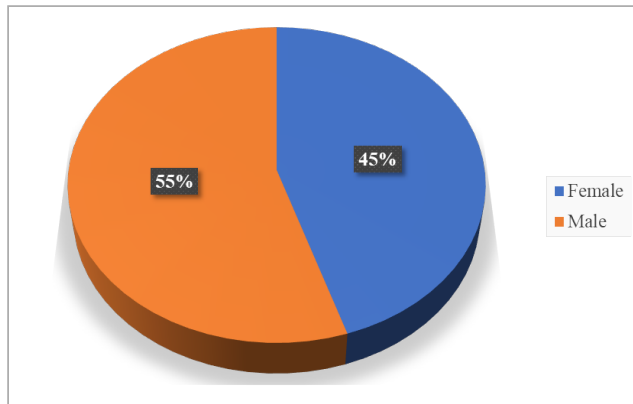


Fig. 1: Graph showing the distribution of subjects according to sex

Table 2: Mean IOP according to age distribution

| Age | Pre operative Mean IOP in mmHg | Post Op 1 week Mean IOP in mmHg | Post Op 1 month Mean IOP in mmHg |
|---------------|--------------------------------|---------------------------------|----------------------------------|
| < 50 years | 16.0 | 11.33 | 12.67 |
| 51- 60 years | 14.41 | 11.83 | 12.50 |
| 61- 70 years | 14.52 | 12.26 | 12.97 |
| 71 – 80 years | 18.89 | 11.56 | 12.56 |
| 81- 90 years | 14.00 | 11.50 | 13.00 |

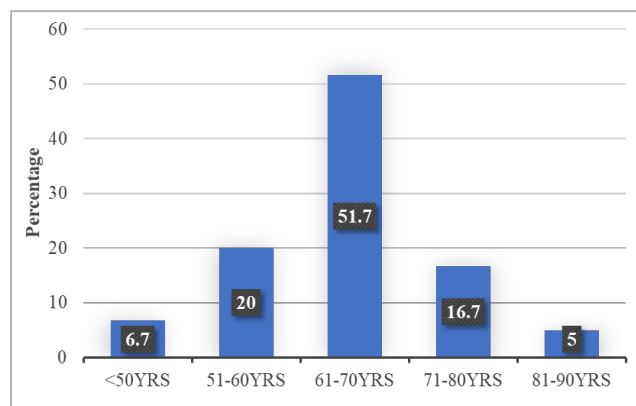


Fig. 2: Graph showing distribution of subjects according to age group

Table 3: Comparison of pre op vs post op - 1 week

| | Mean | Std. Deviation | P value |
|------------------|-------|----------------|---------|
| Pre-op | 15.18 | 2.190 | <0.001 |
| Post op - 1 week | 11.96 | 2.086 | |

There was statistically significant difference found between Pre op and Post op - 1 week.

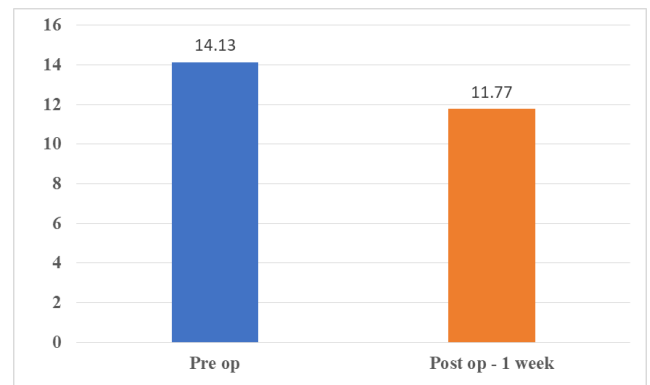


Fig. 3: Graph showing comparison of pre op vs post-op - 1 week

Table 4: Comparison of pre-op vs post-op 1 month

| | Mean | Std. Deviation | P value |
|-----------------|-------|----------------|---------|
| Pre-op | 15.18 | 2.190 | <0.001 |
| Post-op 1 month | 12.75 | 1.444 | |

There was statistically significant difference found between pre op and post-op 1 month.

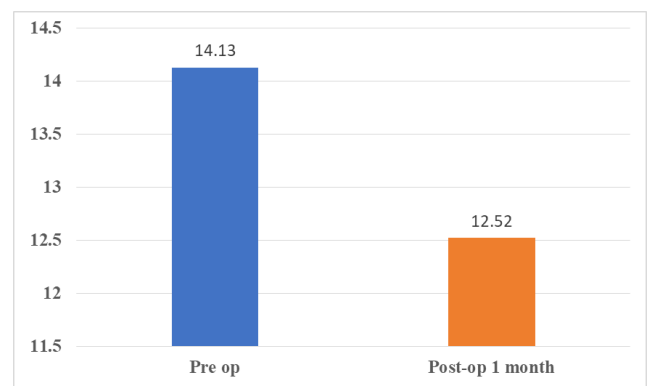


Fig. 4: Graph showing comparison of pre op vs post-op 1 month

4. Discussion

Following cataract surgery, IOP often reduces in patients with or without glaucomatous disease; however, further study is required to identify the degree and duration of this effect. Although their explanation has been less than optimal thus far, angle morphology and other patient-specific traits most likely predict the anticipated postoperative reduction. The mechanisms that cause IOP reduction in patients with open angles following cataract surgery are also largely unexplored. The process by which cataract surgery lowers

intraocular pressure (IOP) is still a topic of discussion, but in recent years, additional explication has been possible. Outflow obstruction is a macroscopic problem that affects patients who have Chronic Angle Closure Glaucoma. This issue is often brought on by a mechanical blockage at the pupil or the angle of the eye.⁵ In Angle Closure Glaucoma patients, the width and depth of the anterior chamber angle considerably widen after cataract removal and IOL implantation, giving the anatomy of these patients the appearance of those without this condition.⁶

During the same time period, Suzuki et al.⁷ revealed that there was no significant change in post-operative versus pre-operative IOP at 10 years for instances in which preoperative IOP was less than 20 mmHg. However, our study it exhibited statistical significance when post-operative IOP was compared to pre-operative IOP at the end of 1 month. However, we have not evaluated the IOP over 6 months or more since the patients were not compliant.

In a study done by Jahn,⁸ the researcher showed that 80% of patients who underwent conventional phacoemulsification saw a consistent reduction in the intraocular pressure of 2 mmHg greater than 5 years after the procedure. This supports our study's finding that the decrease in IOP of 2.43 mmHg at one month was statistically significant.

In a similar manner, Tong and Miller⁹ discovered that patients who underwent cataract removal with either a scleral tunnel or a clear corneal incision saw a drop in intraocular pressure of roughly 2 mmHg between 6 and 8 months after surgery. The pre-operative mean intraocular pressure in our study was 15.18 mmHg, and the post-operative mean was 11.96 mmHg, which indicates that there was a statistically significant change. At 1 month the mean IOP was 12.75 mmHg there is a modest increase in IOP by 0.79 mmHg compared to 1st post-operative week of surgery, nevertheless, there is a drop in mean IOP of 2.43 mmHg at 1 month compared to pre-operative IOP (p-value <0.001)

5. Conclusion

The intra ocular pressure decreases significantly after manual small incision cataract surgery more so in female patients than male patients.

6. Source of Funding

None.


7. Conflict of Interest


Nil.

References

1. Pizzarello L, Abiose A, Ffytche T, Duerksen R, Thulasiraj R, Taylor H, et al. The Right to Sight: a global initiative to eliminate avoidable blindness. *Arch Ophthalmol*. 2004;2020(4):615–20.
2. Bron AJ, Tripathi RC, Tripathi BJ. Wolff's Anatomy of the eye and Orbit. Spain: CRC Press; 1998.
3. Sengupta S, Venkatesh R, Krishnamurthy P, Nath M, Mashruwala A, Ramulu PY, et al. Intraocular pressure reduction after phacoemulsification versus manual small-incision cataract surgery: a randomized controlled trial. *Ophthalmology*. 2016;123(8):1695–1703.
4. Onakpoya OH, Adeoye AO, Adegbehingbe BO, Badmus SA, Adewara BA, Awe OO, et al. Intraocular pressure variation after conventional extracapsular cataract extraction, manual small incision cataract surgery and phacoemulsification in an indigenous black population. *Pan Afr Med J*. 2020;36:119. doi:10.11604/pamj.2020.36.119.16942.
5. Kung JS, Choi DY, Cheema AS, Singh K. Cataract surgery in the glaucoma patient. *Middle East Afr J Ophthalmol*. 2015;22(1):10–7.
6. Hayashi K, Hayashi H, Nakao F, Hayashi F. Changes in anterior chamber angle width and depth after intraocular lens implantation in eyes with glaucoma. *Ophthalmology*. 2000;107(4):698–703.
7. Suzuki R, Kuroki S, Fujiwara N. Ten-year follow-up of intraocular pressure after phacoemulsification and aspiration with intraocular lens implantation performed by the same surgeon. *Ophthalmologica*. 1997;211(2):79–83.
8. Jahn CE. Reduced intraocular pressure after phacoemulsification and posterior chamber intraocular lens implantation. *J Cataract Refract Surg*. 1997;23(8):1260–4.
9. Tong JT, Miller KM. Intraocular pressure change after sutureless phacoemulsification and foldable posterior chamber lens implantation. *J Cataract Refract Surg*. 1998;24(2):256–62.

Author biography

Adipudi Ramya, MBBS, Post Graduate  <https://orcid.org/0000-0002-3411-5733>

Usha B R, Associate Professor  <https://orcid.org/0000-0001-7019-1293>

Cite this article: Ramya A, Usha B R. Impact of cataract surgery on intraocular pressure. *Indian J Clin Exp Ophthalmol* 2023;9(1):75-78.