



Original Research Article

Comparison of change of corneal astigmatism in pre and post operated pterygium excision

Ram Kumar¹, Harish Kumar^{1,*}¹Dept. of Ophthalmology, BRD Medical College, Gorakhpur, Uttar Pradesh, India

ARTICLE INFO

Article history:

Received 04-03-2020

Accepted 08-04-2020

Available online 30-09-2020

Keywords:

Astigmatism

Amniotic membrane

Autograft

Pterygium excision

Vision

Keratometry

ABSTRACT

Background: Pterygium is a wing shaped fibrovascular growth of subconjunctival tissue encroaching upon cornea within interpalpebral fissure area causing significant astigmatism. Surgery for excision of pterygium leads to decrease in astigmatism which significantly improves vision.

Aim: Comparison of change of corneal astigmatism in pre and post operative pterygium excision and visual outcome.

Materials and Methods: The study was carried out on 40 eyes of 40 patients who had primary pterygium, admitted in department of ophthalmology B R D Medical college Gorakhpur; divided in two groups; underwent pterygium excision during period of December 2018 to November 2019. All patients underwent pre operative assessment for visual acuity, refraction, slit lamp examination, keratometry.

Results: It was found that corneal astigmatism decreased progressively in both group after day 1, week 1, week 2, week 4 and after 12 week post operatively.

During follow up at 12 weeks in both groups best corrected visual acuity was found improved and also corneal astigmatism decreased in both group.

Conclusion: Pterygium induces significant corneal astigmatism. Surgery of pterygium leads to significant decrease in corneal astigmatism and increased visual acuity.

© 2020 Published by Innovative Publication. This is an open access article under the CC BY-NC license (<https://creativecommons.org/licenses/by-nc/4.0/>)

1. Introduction

Pterygium is a common disease of the ocular surface. It shows as a wing-shaped fibrovascular proliferation of the bulbar conjunctiva, which encroaches over the cornea. It is located in the interpalpebral area, most common in its nasal part. U. V. radiation has been suggested as a major environmental factor in pterygium formation.¹ The exact pathogenesis is not understood. Many environmental factors, such as sunlight, dry, windy climate, some occupational factors lead to ocular surface inflammation, tear film disturbances and damage of limbal stem cells. These cells are located in the corneoscleral limbus, in the so-called palisades of Vogt, which are responsible for the self-renewal of corneal epithelium and its regeneration after injury. Limbal stem cells act as a

barrier between cornea and conjunctiva and their local deficiency causes conjunctivalization of the corneal surface with vascularization and thus to pterygium formation.² Some authors define pterygium as a stem cell disorder with premalignant features.³ Pterygium causes ocular surface irritation, inflammation, foreign body sensation and cosmetic problems. It affects visual acuity due to induced astigmatism or due to direct invasion of the pupillary area and visual axis. Pterygium causes flattening of the cornea in the horizontal meridian and results in with-the-rule corneal astigmatism. Pterygium leads to reduction of vision not only by causing refractive changes but also by causing a significant increase in corneal aberrations.⁴

Pterygium is treated mainly by surgical excision. The main problem in pterygium surgery is the tendency for recurrence. The standard treatment is conjunctival autografting following pterygium excision, giving less chance of recurrences and complications.

* Corresponding author.

E-mail address: drharishyadav07@gmail.com (H. Kumar).

In the present study, our aim was to evaluate the effect of surgical excision on the changes in visual acuity and corneal astigmatism following pterygium removal with conjunctival autografting.

The exact mechanism for the flattening is not completely understood. Some authors^{5,6} have considered the main role of pooling of tears and formation of meniscus between corneal apex and the head of pterygium. Other investigators like Budack et al.⁷ hypothesized that the flattening of the cornea is because of the mechanical traction caused by the lesion.

1.1. Study design

Prospective study.

1.2. Study period

Dec 2018 to Nov 2019. Nehru Hospital BRD medical College Gorakhpur.

2. Methods

Forty patients with pterygium were selected and divided in two groups the extension of the pterygium was measured using the slit lamp and the corneal astigmatism was measured using keratometry. Correlation of the data is discussed.

3. Materials and Methods

3.1. Inclusion criteria

1. Age more than 18 years.
2. Any type of pterygium with the pterygium classified into either Primary, atrophic or recurrent pterygia.
3. Growing pterygium, which invaded more than 2mm into the cornea.

3.2. Exclusion criteria

1. Recurrent pterygium.
2. Eyes with any corneal pathology.
3. Double pterygium.

4. Methods

All patients underwent preoperative assessment of visual acuity, anterior segment examination with focus on pterygium type morphologically, on the basis of vascularization and progression, posterior segment examination, auto refraction and keratometry. Patient's visual acuity and BCVA were recorded for each eye separately, using Snellen's visual acuity chart with patient sitting at distance of 6 meters. Preoperative horizontal length of pterygium was measured by the slit lamp using the ruler of the slit-lamp from limbus to the advancing edge of pterygium.

4.1. Surgical procedure

4.1.1. Group I

It underwent amniotic membrane grafting. The pterygium head was removed off the cornea by dissection with a crescent. The pterygium was then dissected from the underlying sclera. Fibrous adhesions between the underlying muscle and pterygium were carefully removed before excision of pterygium. Minimal wet field cautery was done to maintain hemostasis. The corneal and limbal surfaces were cleaned by scraping with a BP blade. Then the amniotic membrane was sutured over the sclera to surrounding conjunctiva by 10-0 nylon sutures.

4.1.2. Group II

It underwent conventional conjunctival autograft. The pterygium head was removed off the cornea by blunt dissection with a crescent. The pterygium was then dissected from the underlying sclera.

Fibrous adhesions if any, between the underlying muscle and pterygium were dissected before excision of pterygium.

Minimal wet field cautery was done to maintain hemostasis.

The corneal and limbal surfaces were cleaned by scraping with a BP blade. After pterygium excision, an area of superior bulbar conjunctiva adjacent to limbus, measuring 1 mm greater than the bare sclera was marked. Dissection of the conjunctiva without the Tenon's capsule was done.

The autograft was placed over the bare sclera in its correct anatomical orientation and anchored to the limbus by applying sutures and to surrounding conjunctiva by 10-0 nylon sutures.

Table 1: Pre op. mean horizontal keratometry with postop. Mean horizontal keratometry at 12 week

	Group I with AMG	Group II with autograft
Pre op Mean KH	42.39	42.46
Mean KH at 12 weeks follow up	40.46	41.54

Table 2: Pre op. mean vertical keratometry with post op. with mean vertical keratometry at 12 weeks

	Group I	Group II
Pre op mean KV	43.15	43.49
Mean KV at 12 weeks follow up	40.76	41.91

Post op complications after pterygium excision

5. Results

5.1. Mean pre op astigmatism in

1. Group I: K Vertical-K Horizontal= 43.15-42.39=0.76 (WTR astigmatism).

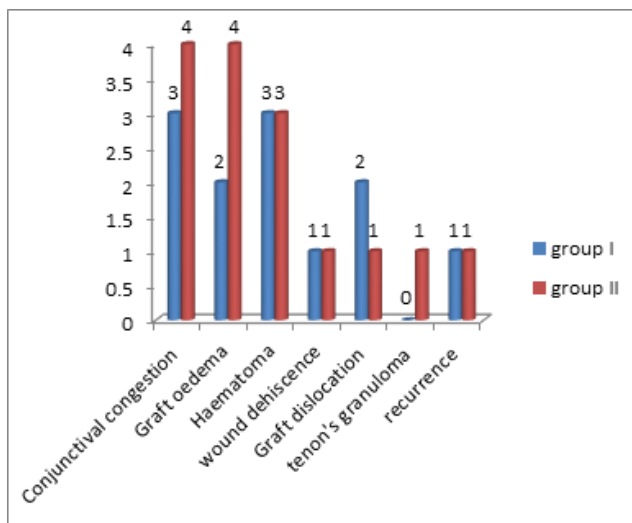


Fig. 1: Postop complication after pterygium excision in both group I with AMG and Group II with autograft

- Group II: K Vertical-K Horizontal= 43.49-42.46=1.03 (WTR astigmatism).

5.2. Mean post operative astigmatism at 12 weeks in

- Group I: K Vertical-K Horizontal= 40.76-40.46=0.30 (WTR astigmatism).
- Group II: K Vertical-K Horizontal= 41.91-41.54=0.37 (WTR astigmatism).

6. Discussion

- Our study was done at Nehru Hospital BRD Medical College Gorakhpur for 1 year duration. We studied the comparison and outcome of pterygium excision with AMG graft and conjunctival autograft surgery.
- In our study we took 40 eyes of 40 patients in which 22 male (55%) and 18 females (45%).
- We divide 40 eyes in two groups with sample size (n=20) eyes in each groups Group 1 with AMG and group 2 with conjunctival autograft.
- In our study age distribution was 60% of (40 – 50) years, 30% (51 – 60) years and 10% (61 – 70) years of age group.
- We use distant vision by snellen's chart and keratometry by Bausch and Lomb keratometry.
- The whole surgery done by single doctor in all patient and will divided in two groups follow up was done on day 1, week 1, week 2, week 4 and after 12 week.
- During follow up at 12 weeks in Group 1 and Group 2 both BCVA was found improved and also corneal astigmatism decreased in both groups.
- In Group 1 Pre-op 2 patient were ATR astigmatism, 18 patients were WTR astigmatism and in post op12 week 5 patients where ATR astigmatism, 15 patients

WTR astigmatism.

- In Group 2 Pre-op 1patient was ATR astigmatism, 19 patients were WTR astigmatism and in post op12 weeks 2 patients where ATR astigmatism, 18 patients were WTR astigmatism.
- Complication in group I with AMG.
After post op 15% patients where with conjunctival congestion, 10% with a oedema, 15% patient with Hematoma, 5% with wound dehiscence, 10% with graft dislocation and 5% with recurrence.
- Complication in group II with a autograft
After post op 20% patient with conjunctival congestion, 10% with oedema, 15% with Hematoma, 5% with wound dehiscence, 5% with graft dislocation 5% tenon's granuloma, and 5% with recurrence.
- Conjunctival congestion was present at day I which was resolved at week2 follow up.
- Graft oedema and Hematoma was present after day 1 follow up which was resolve after follow up week 4.
- Wound dehiscence, tenon's granuloma were corrected after follow up week 1 by surgical division without sequele.
- In group I, 1 patient was with recurrence on follow up at week 4 and in group II, 1 Patient was at week 8.

7. Summary & Conclusion

Pterygium excision causes reduction in Pterygium related corneal flattening.

Significant reduction in astigmatism and improvement in visual acuity is observed post-op 12 weeks.

In the study no significant difference between Pterygium excision with AMG and conjunctival autografting concerning post operative astigmatism were found.

- In 40 patients 55% were male and 45% were female.
- In our study age distribution was 60% of (40 – 50) years, 30% (51 – 60) years and 10% (61 – 70) years of age group.
- All the patients had nasal Pterygium and majority were of the grade T₂.
- In both group complication were present such as conjunctival congestion, hematoma, graft oedema, wound dehiscence, graft dislocations, tenon's granuloma and recurrence was present.
- Conjunctival congestion at week 2, Hematoma and graft oedema were resolve at follow up week 4, 2 patients with graft oedema and 2 patients with tenon's granuloma were surgically corrected after follow up week 1.
- The above findings show that astigmatism has reduced in gr I amniotic membrane transplantation by (0.76-0.30= 0.46) and in group II autograft methods astigmatism has reduced by (1.03- 0.37= 0.66).

7. To conclude our study in both group after Pterygium excision corneal astigmatism decreased and it is observed that decreased more in group I with AMG as compare to group II with autograft.
8. After pterygium excision visual acuity improve more in group I than group II.
9. Complications are less in group I with AMG as compare to group II with autograft.

8. Source of Funding

None.

9. Conflict of Interest

None.

References

1. Moran DJ, Hollands FC. Pterygium and ultraviolet radiation: a positive correlation. *Br J Ophthalmol*. 1984;68(5):343–6.
2. Mahdy MAES, Bhatia J. Treatment of primary pterygium: Role of limbal stem cells and conjunctival autograft transplantation. *Oman J Ophthalmol*. 2009;2(1):23–6.
3. Chui J, Coroneo MT, Tat LT. Ophthalmic pterygium a stem cell disorder with premalignant features. *Am J Pathol*. 2011;178(2):817–27.
4. Razmjoo H, Vaezi MH, Peyman A. The effect of pterygium surgery on wave front analysis. *Adv Biomed Res*. 2014;3:196.
5. Yasar T, Ozdemir M, Cinal A, Demirok A, Ilhan B, Durmus AC. Effects of fibrovascular traction and pooling of tears on corneal topographic changes induced by pterygium. *Eye*. 2003;17(4):492–6.
6. Oldenburg JB, Garbus J, McDonnell JM. Conjunctival pterygia: mechanism of corneal topographic changes. *Cornea*. 1990;9:200–4.
7. Budack K, Khater TT, Friedman NJ. Corneal topographic changes induced by excision of prelimbal lesions. *Ophthalmic Surg Lasers*. 1990;30:458–64.

Author biography

Ram Kumar Professor and HOD

Harish Kumar Resident

Cite this article: Kumar R, Kumar H. Comparison of change of corneal astigmatism in pre and post operated pterygium excision. *Indian J Clin Exp Ophthalmol* 2020;6(3):329-332.