



Original Research Article

Vitreomacular adhesion a risk factor and inducing PVD a treatment option in patients with age related macular degeneration

Krishna Nagaradh^{1,*}, Prarthana Gokarn

¹Sapthagiri Institute of Medical Sciences and Research Centre, Bengaluru, Karnataka, India



ARTICLE INFO

Article history:

Received 07-10-2019

Accepted 19-10-2019

Available online 27-11-2019

Keywords:

Vitreomacular interface

Neovascular membrane

Age related macular degeneration

Optical coherence tomography

Induction of PVD

ABSTRACT

Purpose: To compare the state of posterior vitreous in the aetiology of exudative age related macular degeneration (wet AMD) with non-exudative age related macular degeneration (dry AMD) and controls.

Materials and Methods: We did a Prospective comparative study of 200 eyes of patients aged more than 65 years with Spectral domain OCT and ultrasonography over a period of one year. All subjects underwent a detailed history, physical examination and comprehensive ocular examination. Other ocular conditions like diabetic retinopathy, macular pucker, macular hole, inflammatory diseases, myopia of more than 2D and previous ocular surgeries are excluded from the study. Eyes with evidence of neo vascular AMD confirmed by FFA and ICG were included in group 1. Eyes with pigmentary changes at macula or drusens were included in group 2 and eyes without any changes are included in group 3. These patients were followed up for a duration of 6 months to see the progression at vitreomacular interface.

Results: In the present study, there is a significantly higher prevalence of VMA in patients with choroidal neovascularisation in comparison to eyes with dry AMD and controls. More specifically the attachment site of vitreous to the macula corresponds to the location of choroidal neovascularisation further suggesting the relationship (95%). Patients treated with vitrectomy and anti VEGF for associated VMT showed favourable results in terms of recurrence, visual acuity and number of anti VEGF injections. Also patients with VMA and CNVM needed more frequent injections in comparison to patients with no VMA.

Conclusion: Persistent attachment of the posterior vitreous cortex to the macula is another risk factor for the development and progression of exudative AMD. Inducing PVD could be a treatment option.

© 2019 Published by Innovative Publication. This is an open access article under the CC BY-NC-ND license (<https://creativecommons.org/licenses/by/4.0/>)

1. Introduction

Age related macular degeneration (ARMD) accounts for 8.7% of the total blindness globally, and is the third common cause of visual impairment.¹ In developed and developing countries, age related macular degeneration is the leading cause of vision loss in those aged more than 60 years,² and the morbidity rises with the increase in life expectancy. As reported in population based studies, the prevalence of AMD in India ranges from 39.5% to 0.3%.^{3–5} These proportions are likely to increase with increase in ageing population.

Many risk factors have been attributed for development of AMD like genetic factors, inflammation and ischemia.⁶ Vitreomacular adhesion (VMA) can also contribute to development of age related macular degeneration.^{7,8} The definite relationship between vitreomacular adhesion and AMD as well as the long-term therapeutic effect of induction of vitreomacular separation remains not well established.⁹ The study presented herein used ultrasound, optical coherence tomography, fundus fluorescein angiography and indocyanine green angiography to characterise the relationship between the posterior vitreous and the macula in subjects with both forms of AMD and age matched control groups.

* Corresponding author.

E-mail address: alwayskrish@gmail.com (K. Nagaradh).

2. Materials and Methods

The study was approved by the institutional review board and written informed consent was taken from all the participating subjects as per the declaration by Helsinki. We conducted a prospective randomized clinical comparative study for a period of 1 year during which 200 eyes of patients with age more than 65 years with sufficient visualisation of retina for fluorescein angiography assessed with SD OCT, ultrasonography, FFA and ICG. Patients with previous intraocular surgery, with any kind of retinal lasers, myopia of more than 2D and presence of any intraocular inflammation were excluded from the study.

B scan ultrasonography was done through the lid contact technique and the mobility of the posterior vitreous was examined during ocular saccades. Complete posterior vitreous detachment is seen as good after movements and partial PVD is seen as thin, smooth, continuous membrane with focal attachment with minimal after movements anterior to the retinal surface. Optical coherence tomography as done after mydriasis using Zeiss spectral domain OCT machine a 5 line raster OCT scans through the centre of the fovea were performed with additional lines through the upper and lower arcades, as well as radial lines through the optic disc.

The vitreo macular interface was assessed depending upon VMT study group classification¹⁰ into VMA, no VMA and VMT. The presence of at least one of the following points on OCT scan image is taken as VMA: Partial vitreous detachment as indicated by elevation of cortical vitreous above the retinal surface in the perifoveal area and Persistent vitreous attachment to the macula within a 3mm radius from the center of the fovea.

Presence of the following on OCT is considered as vitreo macular traction (VMT): Acute angle between posterior hyaloid and inner retinal surface or presence of changes in foveal contour or retinal morphology distortion of foveal surface, intra retinal structural changes such as pseudo cyst formation, elevation of fovea from the RPE, or a combination of any of these three features.

On fundus examination patients were classified as wet and dry AMD. Wet AMD was further assessed with OCT, B scan, FFA and ICG to know the type and activity to help us in our study and also for further management. The wet AMD was further categorised as proposed by Freund as type 1: sub RPE CNVM, type 2 subretinal CNVM and type 3 intraretinal CNVM or retinal angiomatosis proliferation (RAP). The lesions were also classified as active and inactive CNVM depending upon presence or absence of subretinal or intra retinal fluid on OCT and active leakage on FFA or ICG.

We followed our patients for duration of 6 months. Patients in control group observed every 6 months, patients in dry AMD group observed every 3 months and patients in wet AMD group observed monthly depending upon kind

of treatment planned for them. Patients needing intervention were seen on 1st post op day, after a week and after a month. Other patients with wet AMD who doesn't need any intervention were observed monthly or 3 monthly.

2.1. Statistical analysis

Results were entered into MEDCALC statistical software. Comparison between groups was tested using chi-square test. The data was analysed and comparisons were done with F Test (ANOVA). The data were also described in percentage and numbers. The judgement about the significance of results obtained was done at 5% level.

3. Results

A total of 200 eyes of patients were studied. Study included 53 males and 47 females. Mean age group in the study population is 71.2 years (Table 1). Number of eyes in each study group (Table 2) with exudative AMD being 88 (44%), in non-exudative AMD 86 eyes (43%), and in controls 26 eyes (13%). Eyes were also grouped into AREDS classification subtypes (Table 3) for further assistance in study. No AMD: None or very few small drusens seen in 26 eyes. Remaining 174 eyes showed some form of AMD which were further graded into AREDS type 1: early AMD- multiple small, few intermediate drusens or RPE abnormalities seen in 64 eyes. AREDS type 2: intermediate AMD- extensive drusens or geographical atrophy not involving the centre of the macula seen in 22 eyes. AREDS type 3: advance AMD - geographic atrophy involving centre of the macula or features of neovascular membrane seen in 88 eyes. The criteria for classifying drusens on sizes were Small drusens <63 microns, intermediate drusens 64 -123 microns, large drusens > 125 microns. Few patients had AREDS high risk AMD features (24 eyes) like confluent soft drusens seen in 3 eyes, marked pigmentary changes seen in 20 eyes, though visual loss in fellow eye due to AMD was seen in one eye.

Eyes with features of CNVM were further studied for characteristics like activity, type and location (Table 4). Out of 88 eyes with CNVM 68 eyes (77.27%) were active on OCT and FFA, 20 eyes (22.73%) were inactive. Depending on type of CNVM, type 1 (sub RPE) was seen in 30 eyes (34.03%), were as type 2 and 3 (sub retinal and RAP) were seen in 58 eyes (65.97%). Depending upon location subfoveal CNVM was seen in 78 eyes (88.63%) and extrafoveal CNVM seen in 10 eyes (11.37%)

On assessment of vitreomacular interface (Table 5), Vitreomacular adhesion (VMA) on OCT was seen in 40 eyes (45.45%) of wet AMD patients, 12 eyes (13.95%) of dry AMD and 3 eyes (11.53%) of controls. No VMA was seen in 23 eyes (88.46%) of control, 74 eyes (86.04%) of dry AMD and 48 eyes (54.54%) of wet AMD patients. The incidence of VMA was high in wet AMD 45.45%

in comparison to dry AMD 11.53% and 13.95%. We found statistically significant difference among wet AMD and control group (Table 6, RR 3.9394; 95%CI, 1.3263–11.7011; $P = 0.00001$). Similar kind of significant difference was seen between wet and Dry group ($P = 0.01719$). But we couldn't find any significant difference between control and dry groups (RR 1.2093; 95%CI, 0.3691–3.9620, $P = 0.7513$). Table 7 details vitreomacular interface in different types of CNVM and we didn't find any difference in behaviour of VMA in active and non active CNVMs. No statistically significant difference was found in occurrence of VMA among type 1 (34.10%) and type 2 (65.90%) CNVMs.

Our study followed up patients with VMA over a period of 6 months in all the three groups. No change in the pattern of VMA was seen in control, dry AMD group after 6 months.

In wet AMD group out of 40 eyes with VMA 10 patients showed spontaneous release after treatment with anti VEGF injection for neovascular membrane. 10 eyes which had component of VMT underwent vitrectomy for the same with anti VEGF injection. All the patients had regressed CNVM with improvement in vision after 6 months of surgery and needing an average of 2 injections treated on PRN regimen.

Other patients with CNVM and no VMA who were treated with anti VEGF received 1.7 injections on an average and patients with VMA not treated with vitrectomy received 2.7 injections on average.

4. Discussion

Physiological changes in vitreous that happens due to aging has been described by Sebag.^{10,11} Vitreous goes for liquefactive changes with deteriorating of its adhesions to entire retina and by eighth decade about 63% of individuals will have visible posterior vitreous detachment.¹² Many risk factors have been mentioned in lots of population based studies like cigarette smoking, genetics, age and diet in the development of AMD. The age related eye disease study concluded few additional high risk characteristics for ARMD like large confluent soft drusens, vision loss in fellow eye due to AMD, and marked pigmentary changes.^{13–16} Lee et al in his study done in 2009 showed that 24.4% of patients had wet AMD in only one eye and no signs of AMD or wet AMD in the fellow eye.¹⁷ But you cannot attribute different grades of AMD and progression between two eyes of same individual to genetic and environmental factors. There has to be some other explanation or contributing factors for this variation. That factor could be the relation of posterior vitreous cortex to the macula during the course of the disease as vitreous plays important role in providing oxygen and nutrients to the retina.

In our study we tried to understand the role of posterior vitreous in the pathogenesis of CNVM. We compared the

status of vitreomacular interface in control group, dry AMD patients and wet AMD patients. The wet AMD group had a significantly higher percentage of VMA in comparison to dry AMD and control group. Our results are similar other studies done on the similar background of vitreomacular interface in AMD patients. All data of these studies^{18–23} when put together showed VMA in wet AMD group of 28.55% [n=694], in dry AMD group of 11.9% [n=333] and in control group of 8.7% [n= 265]. Every single study reported higher rate of VMA in wet AMD patients. They also said that wet AMD patients are 2.15 (95% CI, 1.34–3.48; $P = 0.002$) times more likely to have VMA than control group and 2.54 times than dry AMD group (95%CI, 0.88–7.36; $P = 0.09$). Our study is also in acceptance with their results²⁴ and showed no much relationship between VMA and dry AMD (RR of 1.2). But patients with wet AMD were 3.9 times more likely to have VMA than control group which is statistically significant with p value of 0.0136. The patients in our study who had localised vitreous adhesion to macula on OCT showed higher prevalence of choroidal neovascular membrane. About 45.45% patients with CNVM had VMA. In 95.5% of patients with VMA that is 38 out of 40 eyes the site of VMA matched the site of CNVM which strongly suggests it as one of the cause.

We also did a sub analysis on type of CNVM and VMA changes in them. We found a higher number of patients with VMA in intra retinal CNVM (28 eyes out of 40 eyes) with in comparison to Sub RPE CNVM. It was Sebag and Hageman²⁵ who found structural, molecular and embryological resemblance between internal limiting membrane and bruch's membrane, so patients with VMA have a very high chance of having a weak Bruch's membrane which can lead to wet AMD and that too intraretinal type. We hypothesize that VMA induces inflammation and ischemic changes which favour the development of intraretinal component of CNVM. It is possible that these changes span the entire length of the retina (inner and outer) and therefore explain the intraretinal invasion.²⁶ However, we did not get any cases of type 3 CNV or RAP.

An article by Mojana *et al*²⁰ in 2008 quoted that VMA was seen higher in minimally classic type of CNV compared to occult and classic CNVs. Another study done in Japanese's patients said patients with typical AMD had lesser PVD in comparison to control groups but no change in occurrence of PVD was seen in patients with PCV and control group.²² Another study by Robison *et al*¹⁹ quoted an higher percentage of PVD in dry AMD patients and VMA being seen more in patients with wet AMD. They assumed that vitreo macular adhesion is acting as pro angiogenic factor and is the one causing increased release of VEGF and progression of CNV. Its another unifying concept of Sebag *et al*²⁷ who proposed recently of tractional effect of VMA as the cause of progression of AMD. We are in

Table 1: Comparison of studied groups on demographic data

Parameters		n=200	Control	Dry AMD	Wet AMD	Test of significance	P
Sex	Male	106	15	46	47	$\chi^2 = 1.3636$	0.505699
	Female	94	11	40	41		
Age	Median	65.2	65	64.2	66.2	F= 1.42	0.282

χ^2 : Chi-square test; F : F -test (ANOVA).

Table 2: Distribution of cases in each study group

	Group	Number of eyes	Percentage
1	Exudative(wet) AMD	88	44%
11	Non Exudative (dry) AMD	86	43%
111	Control	26	13%

Table 3: Distribution of cases according to AREDS classification

AREDS	n	%
No AMD	26	13
I	64	32
II	22	11
III	88	44
High risk AMD	24	
• Vision loss in fellow eye due to AMD	1	
• Confluent soft drusens	3	2
• Marked pigmentary changes	20	10

Table 4: Distribution of the studied cases according to characteristics of CNVM

Parameters		n	%
CNV activity (OCT, ICG & FFA) n=88	Active	68	77.27
	Inactive	20	22.73
CNV type	Sub RPE(type 1)	30	34.09
	Sub retinal and Intraretinal (type 2 and 3)	58	65.90
Location of CNVM	Subfoveal/juxtafoveal	78	88.63
	Extra foveal	10	11.36

Table 5: Comparison of studied groups according to VMA

Parameters	Control	Dry AMD	Wet AMD	Percentage	X ²	P
VMA n=55	3 (5.45%)	12 (21.81%)	40 (72.7%)	27.5%	25.4665	<0.00001
No VMA n=145	23	74	48	72.5%		
Significance between groups	P ₁ = 0.751386, P ₂ = <0.00001, P ₃ =0.001719					

Table 6: Analysis of complete PVD and VMA in wet and dry AMD

VMI	Variable	Risk ratio	95% CI		p
			Lower bound	Upper bound	
VMA	Dry AMD	1.2093	0.3691	3.9620	0.7536
	Wet AMD	3.9394	1.3263	11.7011	0.0136
	Control	1			
No VMA	Dry AMD	0.9853	0.7004	1.3862	0.9324
	Wet AMD	0.7519	0.5169	1.0937	0.1359
	Control	1			

Table 7: Relation between VMA and wet AMD characteristics

Parameters		VMA (n=40)	No (n=48)	VMA X2	p
CNV activity (OCT & FFA)	Active(n=68)	30 (75%)	38	0.2157	0.642347
	Inactive (n=20)	10 (25%)	10		
CNV type	Sub RPE(type 1)(n=30)	12	18	0.5462	0.4598
	Intraretinal (type 2 and 3) (n=58)	28	30		
Location of CNVM	Subfoveal/juxta (n=78)	38	40	2.9484	0.085964
	Extra foveal (10)	2	8		

Table 8: Status of VMA on follow up

Group	VMA at presentation	Progression at 6 months follow up
Control	3	3
Dry AMD	12	12
Wet AMD	40	20

Table 9: Details of patient treated with vitrectomy

S. No	Type of VMT	CNVM status	Intra op IV anti VEGF	Pre op vision	No of Follow up injection	Post op vision	CNVM status at 6 months
1	V shaped, focal	active	yes	20/200	1	20/60	inactive
2	Broad based	active	yes	20/100	1	20/60	inactive
3	V shaped focal	Active	yes	20/200	1	20/80	inactive
4	V shaped focal	active	yes	Cf 2mts	none	Cf 5mts	scared
5	V shaped focal	active	yes	20/80	1	20/40	inactive
6	V shaped focal	active	yes	Cf 1mts	1	Cf 5mts	scared
7	V shaped focal	Active	yes	20/200	1	20/80	inactive
8	Broad based	active	yes	20/100	1	20/40	inactive
9	V shaped focal	active	yes	20/80	1	20/40	inactive
10	Broad based	active	yes	20/100	1	20/80	scared

Table 10: Status of VMA post intravitreal anti VEGF injections

No. of eyes with wet AMD needed IV anti VEGF	No. of injections [avg] PRN regimen	Status of vitreo macular interface at follow up [avg duration 6 months]
No. of eyes with no VMA [48]	1.7 injections	No VMA
No. of eyes with VMA [40]	2.7 injections	10 eyes had spontaneous release of VMA and 10 eyes underwent vitrectomy for release of VMT.

acceptance with this concept.

It was Ikeda et al who did vitrectomy for VMA and CNVM in 12 eyes and at 6 months follow up CNVM regressed in 6 eyes and completely disappeared in 2 eyes.²⁸ Similarly Mojana et al did vitrectomy in 5 eyes and 4 eyes showed improvement in visual acuity and decrease in central foveal thickness on

OCT.²⁹ Two more studies report favourable outcome for vitrectomy in CNVM patients with VMT.^{30,31} It was Sakamoto et al who showed in 40 eyes that CNV can regress or completely disappear after vitrectomy.³² Another important finding was given by Schramm et al who commented that core vitrectomy in patients with CNVM might reduce the number of intravitreal anti VEGF injections.³³ Also EXCITE study showed better response

for anti VEGF in patients with VMA who developed PVD than in who retained VMA.^{34–37} All these studies favour vitrectomy in improving functional and structural outcomes or decrease the number of anti VEGF injections needed. They opine that vitrectomy release all inflammatory agents trapped between posterior vitreous and internal limiting membrane.²⁹ Vitrectomy thus helps by increasing oxygenation of the retina and reducing VEGF load.

Our study also included a subgroup with 10 cases of CNVM which had components of vitreomacular traction and subretinal fluid. These eyes were subjected for vitrectomy and release of traction with intra-op anti VEGF injection. The follow-up of these eyes was favourable as all patients showed improvement in vision and they did not show any recurrence of activity till date. They also

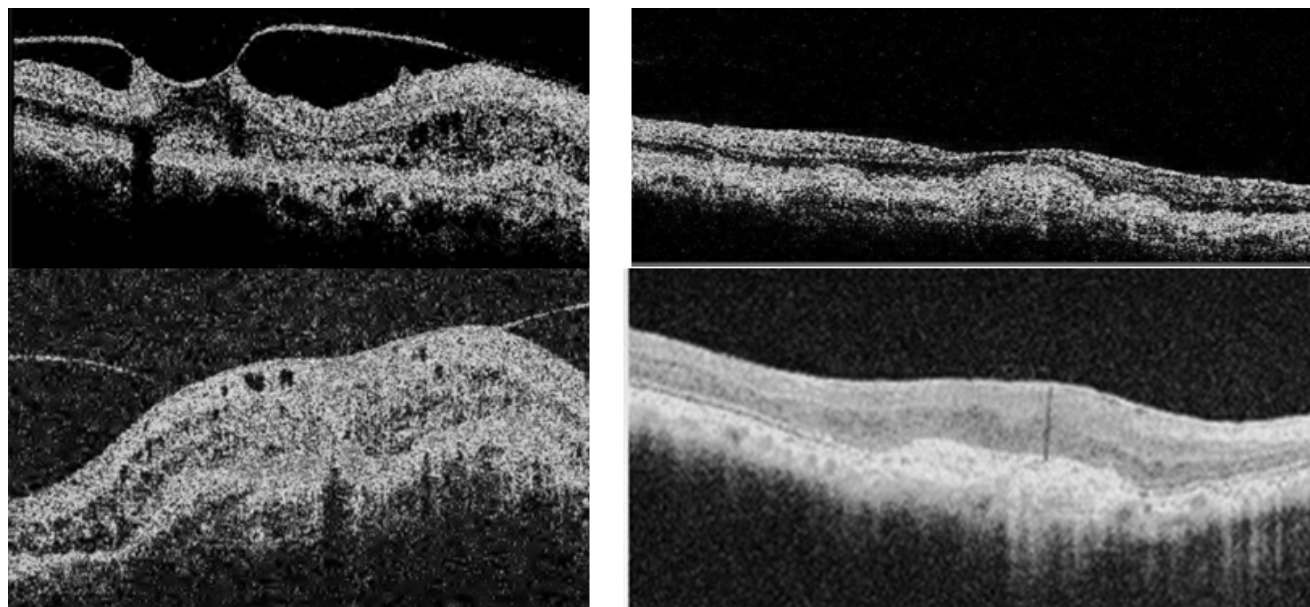


Fig. 1: Shows the pre op and post op OCT images of two patients with focal and broad based VMT who underwent vitrectomy with anti VEGF injection.

needed on an average one injection less than other patients who were treated with only anti VEGF injections. Patients with CNVM and VMA received an average 2.7 injections in comparison to patients without VMA who received 1.7 injections, one injection more which is significant in a country like India. We also noticed that 10 eyes had spontaneous release of VMA who required no further injections. However, prospective studies are necessary to confirm the role of vitrectomy in AMD pathogenesis and progression.

In spite of abundance of knowledge about the vitreo-macular interface and advanced instruments to record the events, the exact role played by VMA in the pathogenesis of AMD remains uncertain. There is a need for further studying of this aetiology. Emergence of pharmacological vitreolysis^{38–40} which aims in inducing PVD in cases with VMT will be game changer as it will act as a prophylactic treatment and a protection from developing wet AMD. Our study had a drawback of small number of patients in the control group and few patients couldn't get ICG done due financial constraints. Both these things could have further altered our study outcome. On stronger note we went and operated few patients with vitreo macular traction and AMD which showed favourable results postoperatively which strongly suggests VMA as a risk factor for AMD and its progression.

5. Conclusion

To summarise our study results show a strong relation between vitreomacular adhesion and wet AMD in particular intraretinal CNV. Studies with larger population and longer

follow-ups should be done which can support our findings. Inducing PVD in high risk patients could be a treatment option in hands of treating ophthalmologist.

6. Source of Funding

None.

7. Conflict of Interest

None.

References

1. World Health Organization. Age Related Macular Degeneration: Priority eye diseases. Available from: <http://www.who.int/blindness/causes/priority/en/index8.html>. [Last accessed on 2011 Feb 6]. ;.
2. Resnikoff S, Pascolini D, Etyaale D, Kocur I, Pararajasegaram R, et al. Global data on visual impairment in the y ear. *Bull World Health Organ*. 2002;82:844–851.
3. Krishnan T, Ravindran RD, Murthy G, Vashist P, Fitzpatrick KE, et al. Prevalence of early and late age-related macular degeneration in India: The INDEYE Study. *Invest Ophthalmol Vis Sci*. 2010;51:701–707.
4. R KS, Aghashe SR, Khandekar RB, Deshpande MD. Prevalence and determinants of age-related macular degeneration in the 50 years and older population: A AMD and diabetes S Srinivasan et al 1182 Eye hospital based study in Maharashtra, India. *Indian J Ophthalmol*. 2013;61:196–201.
5. Krishnaiah S, Das T, Nirmalan PK, Nutheti R, Shamanna BR, et al. Risk factors for age-related macular degeneration: Findings from the Andhra Pradesh eye disease study in South India. *Invest Ophthalmol Vis Sci*. 2005;46:4442–4449.
6. Spaide RF, Armstrong D, Browne R. Continuing medical education review: choroidal neovascularization in age-related macular degeneration what is the cause? *Retina*. 2003;23(5):595–614.
7. Krebs I, Brannath W, Glittenberg C, Zeiler F, Sebag J, et al. Posterior vitreomacular adhesion: a potential risk factor for exudative age-related

- macular degeneration? *Am J Ophthalmol.* 2007;144(5):741–746.
8. M MQEM, M MF. Anomalous vitreoretinal adhesions in patients with exudative age-related macular degeneration: an OCT study. *Eur J Ophthalmol.* 2006;16(1):134–137.
 9. Ondes F, G Y, Acar MA, Unl N, Kocaolan H, et al. Role of the vitreous in age-related macular degeneration. *Jpn J Ophthalmol.* 2000;44(1):91–93.
 10. Sebag J. Age-related changes in human vitreous structure. *Graefes Arch Clin Exp Ophthalmol.* 1987;225(2):89–93.
 11. Sebag J. Age-related differences in the human vitreoretinal interface. *Arch Ophthalmol.* 1991;109(7):966–971.
 12. Foos RY. Posterior vitreous detachment. *Trans Am Acad Ophthalmol Otolaryngol.* 1972;76(2):480–497.
 13. Clemons TE, Milton RC, Klein R, Seddon JM, Ferris FL. Age Related Eye Disease Study Research Group. Risk factors for the incidence of Advanced Age-Related Macular Degeneration in the Age-Related Eye Disease Study (AREDS) AREDS report no.19. *Ophthalmol.* 2005;112(4):533–539.
 14. Chakravarthy U, Augood C, Bentham GC, Jong PTVM, Rahu M, et al. Cigarette smoking and age-related macular degeneration in the EUREYE Study. *Ophthalmol.* 2007;114(6):1157–1163.
 15. Francis PJ, George S, Schultz DW, Rosner B, Hamon S, et al. The LOC387715 gene, smoking, body mass index, environmental associations with advanced age-related macular degeneration. *Hum Hered.* 2007;63(3-4):212–218.
 16. Risk factors associated with age-related macular degeneration. A case-control study in the age-related eye disease study: Age-Related Eye Disease Study Report Number 3. *Ophthalmology.* 2000;107(12):2224–2232.
 17. Lee SJ, Lee CS, Koh HJ. Posterior vitreomacular adhesion and risk of exudative age-related macular degeneration: paired eye study. *Am J Ophthalmol.* 2009;147(4):621–626. e1.
 18. Lee SJ, Koh HJ. Effects of vitreomacular adhesion on anti-vascular endothelial growth factor treatment for exudative age-related macular degeneration. *Ophthalmol.* 2011;118(1):101–110.
 19. Robison CD, Krebs I, Binder S, Barbazzetto IA, Kotsolis AI, Yannuzzi LA. Vitreomacular adhesion in active and end-stage age-related macular degeneration. *Am J Ophthalmol.* 2009;148(1):79–82. e2.
 20. Mojana F, Cheng L, Bartsch DU, Silva GA, Kozak I, Nigam N. The role of abnormal vitreomacular adhesion in age-related macular degeneration: spectral optical coherence tomography and surgical results. *Am J Ophthalmol.* 2008;146(2):218–227.
 21. Krebs I, Brannath W, Glittenberg C, Zeiler F, Sebag J, Binder S. Posterior vitreomacular adhesion: a potential risk factor for exudative age-related macular degeneration? *Am J Ophthalmol.* 2007;144(5):741–746.
 22. Nomura Y, Ueta T, Iriyama A, Inoue Y, Obata R, Tamaki Y. Vitreomacular interface in typical exudative age-related macular degeneration and polypoidal choroidal vasculopathy. *Ophthalmol.* 2011;118(5):853–859.
 23. El-Hifnawy M. The vitreomacular interface in different types of age-related macular degeneration. *Int J Ophthalmol.* 2017;10(2):246–253.
 24. Waldstein SM, Sponer U, Simader C, Sacu S, Schmidt-Erfurth U. Influence of vitreomacular adhesion on the development of exudative age-related macular degeneration: 4-year results of a longitudinal study. *Retina.* 2012;32(3):424–433.
 25. Sebag J. Is pharmacologic vitreolysis brewing? *Retina.* 2002;22(1):1–3.
 26. Freund KB, Zweifel SA, Engelbert M. Do we need a new classification for choroidal neovascularization in age-related macular degeneration? *Retina.* 2010;30(9):1333–1349.
 27. Sebag J. Anomalous posterior vitreous detachment: a unifying concept in vitreo-retinal disease. *Graefes Arch Clin Exp Ophthalmol.* 2004;42(8):690–698.
 28. Ikeda T, Sawa H, Koizumi K, Yasuhara T, Yamasaki T. Pars plana vitrectomy for regression of choroidal neovascularization with age-related macular degeneration. *Acta Ophthalmol Scand.* 2000;78(4):460–464.
 29. Mojana F, Cheng L, Bartsch DUG. The role of abnormal vitreomacular adhesion in age-related macular degeneration: spectral optical coherence tomography and surgical results. *Am J Ophthalmol.* 2008;146(2):218–227.
 30. Liu YL, Lin CP, Yang CM. Transient regression of choroidal neovascularization membrane after vitrectomy in age-related macular degeneration with vitreomacular traction syndrome. *Acta Ophthalmol.* 2011;89(3):291–293.
 31. Shah SU, Haller JA. Vitreomacular traction in a case of exudative age-related macular degeneration resistant to anti- VEGF therapy. *Acta Ophthalmol.* 2012;90(7):569–570.
 32. Sakamoto T, Sheu SJ, Arimura N. Vitrectomy for exudative age-related macular degeneration with vitreous hemorrhage. *Retina.* 2010;30(6):856–864.
 33. Schramm K, Mueller M, Koch FH, Singh P, Kohnen T, et al. Effects of core vitrectomy in the treatment of age-related macular degeneration. *Acta Ophthalmol.* 2014;92(5):465–472.
 34. Mayr-Sponer U, Waldstein SM, Kundi M, Ritter M, Golbaz I, et al. Influence of the vitreomacular interface on outcomes of ranibizumab therapy in neovascular age-related macular degeneration. *Ophthalmol.* 2013;120(12):2620–2629.
 35. Ciulla TA, Cuilla TA, Ying GS, Maguire MG, Martin DF, et al. Influence of the vitreomacular interface on treatment outcomes in the comparison of age-related macular degeneration treatments trials. *Ophthalmol.* 2015;122(6):1203–1211.
 36. Houston SK, Rayess N, Cohen MN, Ho AC, Regillo CD. Influence of vitreomacular interface on anti-vascular endothelial growth factor therapy using treat and extend treatment protocol for age-related macular degeneration (Vintrex). *Retina.* 2015;35(9):1757–1764.
 37. McKibbin MA, Suter CA, Willis TA. The influence of vitreomacular adhesion on outcomes after aflibercept therapy for neovascular age-related macular degeneration. *Retina.* 2015;35(10):1951–1956.
 38. Sebag J. Molecular biology of pharmacologic vitreolysis. *Trans Am Ophthalmol Soc.* 2005;103:473–494.
 39. -. *Sebag J Pharmacologic vitreolysis Retina.* 1998;18(1):1–3.
 40. J S, Hageman GS, Interfaces. Pharmacologic vitreolysis. *Retina.* 2000;18(1):1–3.

Author biography

Krishna Nagaradh Assistant professor

Cite this article: Nagaradh K, Gokarn P. Vitreomacular adhesion a risk factor and inducing PVD a treatment option in patients with age related macular degeneration. *Indian J Clin Exp Ophthalmol* 2019;5(4):501-507.