



Case Series

Ocular tuberculosis manifestation patients attending a tertiary care center

Rekha Rathnaiah^{1*} ¹Dept. of Ophthalmology, The Oxford Medical College, Hospital and Research Centre, Bangalore, Karnataka, India

Abstract

The objective is to determine the incidence of ocular manifestation of tuberculosis in a tertiary care center and to study different clinical manifestations of ocular tuberculosis for early and specific diagnosis. Ocular tuberculosis (TB) is an infection caused by *M. tuberculosis* (MTB) involving eye, with or without systemic manifestation. Tuberculosis of eye represents a challenging task for a clinician in diagnosis and treatment. This study is a small step to explore various clinical manifestation of ocular tuberculosis. The present study represents prospective observational study conducted from 2018 to 2023 at a tertiary center focusing on the various clinical manifestation and diagnosis of ocular tuberculosis.

The present study consists of 11 ocular tuberculosis cases 9 cases having bilateral ocular involvement. The most common clinical presentation is retinal vasculitis (45%) followed by intermediate uveitis (9%), multifocal choroiditis, (9%). For ophthalmologists it is imperative to know different morphological presentations of ocular tuberculosis. The Ocular Tuberculosis is diagnosed based on the high index of suspicion, typical clinical manifestations supported by modern molecular microbiological assays and a therapeutic response to Anti tubercular treatment.

Keywords: Ocular tuberculosis, Scleritis, Multifocal choroiditis, Retinal vasculitis.

Received: 12-05-2024; **Accepted:** 02-04-2025; **Available Online:** 13-09-2025

This is an Open Access (OA) journal, and articles are distributed under the terms of the [Creative Commons Attribution-NonCommercial-ShareAlike 4.0 License](https://creativecommons.org/licenses/by-nc-sa/4.0/), which allows others to remix, tweak, and build upon the work non-commercially, as long as appropriate credit is given and the new creations are licensed under the identical terms.

For reprints contact: reprint@ipinnovative.com

1. Introduction

The current global prevalence of ocular TB 0.5% to 1.4%. In India an endemic tuberculosis area prevalence of ocular tuberculosis is 9.86%. Ocular TB is an infection caused by of *M. tuberculosis* involving eye with or without Systemic involvement. Ocular tuberculosis infection occurs either due to direct mycobacterium invasion on ocular tissues, hypersensitivity to antigen of MTB with viable mycobacterium and hypersensitivity in the absence of viable bacteria.¹

The primary ocular TB occurs due to direct infection of the eye through the conjunctiva, cornea, or sclera. The secondary ocular TB occurs by hematogenous spread of the organism. The choroid is the most common site of ocular TB manifestation due to the rich blood supply and high regional oxygen of the uveal tract.² The HIV pandemic and emergence of drug-resistant strains of MTB has generated a renewed

interest in the ocular tuberculosis. Clinical manifestation of tuberculosis in eye involves almost every part of eye from orbit to optic nerve. The tuberculosis manifestation orbit draining sinus with bone destruction, eyelid abscess, chalazion dacryadenitis, conjunctival nodule, keratoconjunctivitis.² Tubercular scleritis presents as focal elevated nodules of dark red discoloration of the sclera inflamed crisscross episcleral vessels are adherent to the sclera with associated Scleral edema and edges of the scleritis is more yellowish white as compared to the noninfectious scleritis which is whitish and more avascular. (**Figure 1**)

*Corresponding author: Rekha Rathnaiah
Email: rekhakrathnaiah@gmail.com

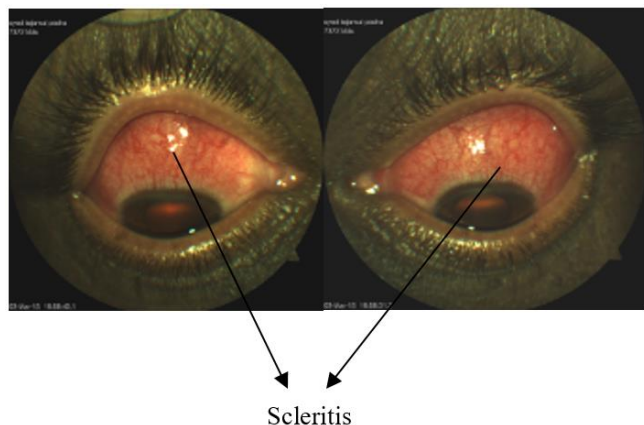


Figure 1: Tubercular scleritis

Tubercular uveitis presents as granulomatous anterior uveitis broad-based synechial.³ Presence of a pigmented hypopyon which do not show adequate response to topical/systemic steroids alone and recurrences on stopping steroid is highly suggestive of tubercular uveitis. The complicated cataract begins as a posterior sub capsular cataract opacity irregular in outline appearing as bread crumb, appearance of iridescent colored particles polychromatic luster of red green and blue gradually forms total cataract. (**Figure 2**) Intermediate uveitis presents as smoldering vitritis with snowball opacities over the pars plana⁴⁻⁶ associated with peripheral vascular sheathing, cyclitis, and retinochoroidal granuloma. Posterior uveitis presents as Choroidal tubercles creamy to yellow colored, deep nodules margins well defined on healing appears as a ring of peripheral pigmentation. On OCT well-defined hypo reflective areas in the choroid obscuring the normal choroidal vasculature FFA of Choroidal tubercle early phase hypofluorescent. Centripetal increase in fluorescence of the lesion with the lesion becoming hyperfluorescent in the late stages, due to dye entering the lesion from its surroundings Choroidal Tuberculomas are large granulomatous infiltration of the choroid with tubercular bacilli forming a sub retinal mass lesion.⁴⁻⁶ On Indirect ophthalmoscope presents as large creamy to yellow mounds elevating the retinochoroidal layers the margins not well defined associated retinal hemorrhages or retinal folds Tubercular choroiditis presents in three types 1 Multifocal choroiditis: yellowish white $\frac{1}{4}$ –1 disc diameter (DD) in size with well-defined margins discrete lesions and slightly raised edges which are noncontiguous initially and show a wavelike progression over a period of 1–4 weeks and gradually become confluent. Placoid chorioretinitis: amoeboid plaque-like lesion yellowish white elevated border active edge. On healing pigmentary changes in the center of the lesion

Tubercular anterior uveitis complicated cataract

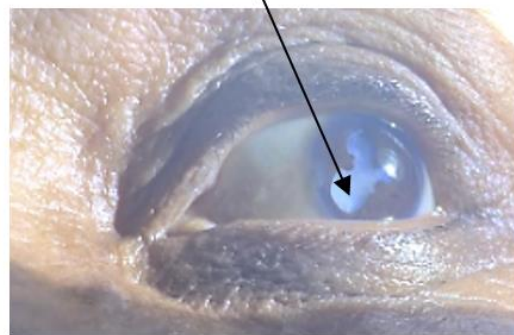
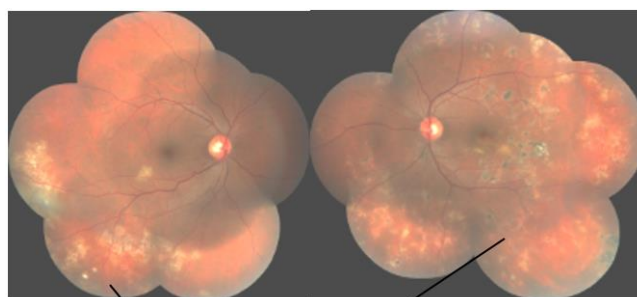


Figure 2: Complicated cataract and tubercular uveitis

Mixed pattern: overlapping features of both multifocal and placoid chorioretinitis.⁷

Figure 3 FFA. Active lesions demonstrate ill-defined hyper-autofluorescence diffuse, amorphous appearance. Stage of early healing a thin rim of hypo-autofluorescence surrounding the lesion which remains predominantly hyper-auto fluorescent with a stippled pattern. (**Figure 4**) Multifocal serpiginous choroiditis or serpiginous-like choroiditis⁴⁻⁶ bilateral, appearing as greyish yellow discoloration extending from the juxtapapillary area Multifocal, irregular, serpiginous lesions involving the posterior pole, mid-periphery and periphery, but usually sparing the juxtapapillary associated with vitritis and uveitis. Pigment clumping usually at the centre of lesions.

Tubercular retinal vasculitis presents as perivascular inflammatory infiltrates associate with an exudative segmental hemorrhagic peri or sub vascular choroiditis, vitritis disc and macular edema.^{6,8} (**Figure 5**) Untreated recurrent vitreous bleeds leads to tractional retinal detachment iris neovascularization and neovascular glaucoma. (**Figure 6**)



Multifocal Choroiditis

Figure 3: Multifocal chordates

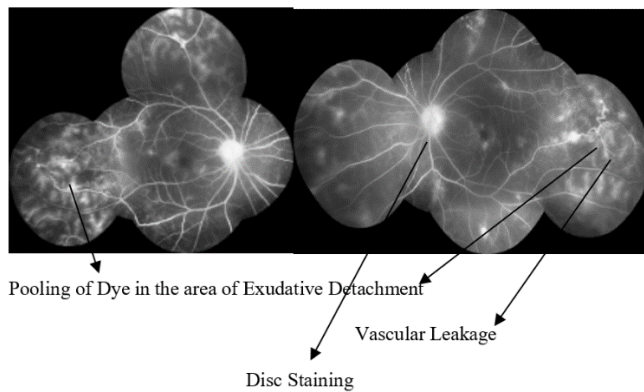


Figure 4: Fundus fluorescein angiogram

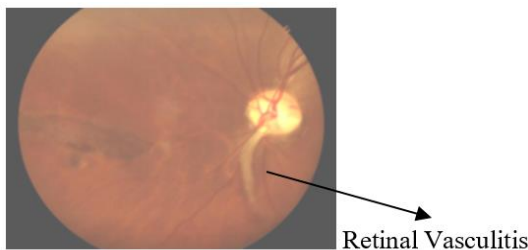


Figure 5:

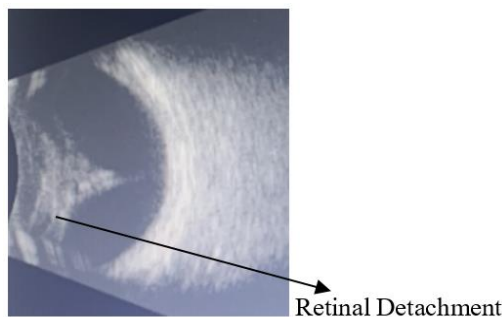


Figure 6:

Ocular tuberculosis in HIV positive presents as Focal necrotizing scleritis Choroidal tubercle or granuloma panophthalmitis. (**Figure 7**) Mantoux test may be negative due to altered immune status, and chest X-ray normal. A risk of worsening of the tubercular inflammation is seen when HAART and ATT are started together which hasten the progression to panophthalmitis to avoid this, the HAART be started a few weeks after initiating ATT.

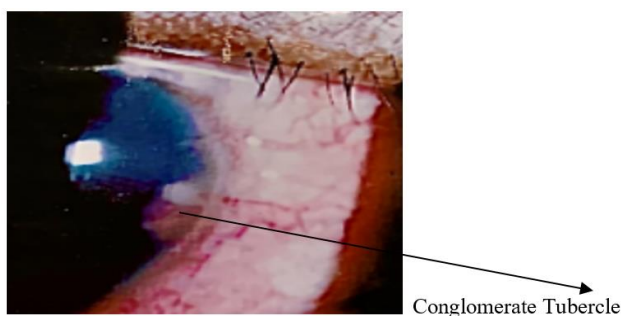


Figure 7:

The need for the study India being endemic country for the TB and reemergence of AIDS increase in TB case. The occurrence of ocular TB needs to be determined. Ocular TB, potentially sight threatening manifestation and rare manifestation of systematic TB there are several gaps in ocular TB research that requires to be addressed for improvement and diagnosis and patient vision outcomes. The gaps include lack of reliable biomarkers for early detection and diagnosis and under diagnosis of ocular TB which is symptomatic or present with non specific symptoms thus accurate understanding of clinical manifestation of ocular TB is required for early diagnosis of ocular TB. This study is small step towards determining ocular manifestation of tuberculosis in different parts of eye both in presence and absence of systemic tuberculosis.

2. Objective

1. To determine the incidence of ocular manifestation of tuberculosis in a tertiary care center.
2. To study different clinical manifestations of ocular tuberculosis for early and specific diagnosis

3. Material and Methods

The present study represents prospective observational study conducted from 2018 to 2023 at a tertiary center focusing on the various clinical manifestation and diagnosis of ocular tuberculosis.

The study involved about 11 study participants on whom

- A. Detailed pulmonary evaluation performed by pulmonologist using criteria¹
 1. Mantoux –15mmx15mm
 2. chest x ray with previous pulmonary TB –discrete fibrotic scar or linear opacity nodules with calcification or retraction, volume loss are considered positive for previous history of pulmonary TB.
 3. QuantiFERON-TB Gold positive if T-N is >1.5 IU/ml T IFN gamma response to purified protein derivatives from M tuberculosis N IFN gamma response to nil antigen.⁹
 4. FNAC OF LYMPH NODE Fine needle aspirations done using 22G needle and disposable syringe of 20ml The smears are air dried and stained with MAY –grunwaldgiemsa (MGD) and Ziehl Neelsen stain (ZN) stain for AFB other features like epithelioid cell granuloma with caseation necrosis and inflammation considered positive
 5. The diagnosis of intraocular TB requires strong clinical suspicion with corroborative laboratory and radiological evidence. A positive PCR is reliable whereas negative results should be correlated with clinical features. An adequate response to ATT supports PCR results.¹⁰

B. Detailed ophthalmological evaluation is performed by examination of

1. Visual acuity estimation using Snellen chart and jager chart
2. Colour vision by Ishara chart
3. Detailed anterior segment examination is done using the slit lamp
4. Fundus examination was done using indirect ophthalmoscope and 78D
5. Fundus photography
6. Fundus fluorescein angiogram
7. Optical coherent topography

The inclusion criteria for the diagnosis of the ocular tuberculosis used in study² are:

1. Mantoux or Tuberculin skin test (TST) more than 10 mm-15mm is considered positive.
2. Clinical picture on examination with a slit lamp, Indirect ophthalmoscope Fundus fluorescein angiogram
3. QuantiFERON-TB gold positive¹¹
4. Dramatic response to antituberculous drug-symptomatic better with decrease pain and decrease in the anterior segment reaction and cells after treatment of ATT for one to four week¹²

Table 3 depicts clinic distributions of individual ocular manifestations and their correlation with laboratory radiological associated systemic tuberculosis.

Retinal vasculitis constituting about 45% in about 5 of the study participants out of 11 presented constituting the most common ocular manifestation in our present study. Scleritis, intermediate uveitis multifocal choroiditis, choroidal tubercle and posterior uveitis each constituting 1 and Uveitis and complicated cataract presented in 2 study participants. Previous history of pulmonary tuberculosis treated with ATT in 4 study participants.

Table 1: Socio-demographic profile of our present study

Table 3: Clinical profile of our present study

Study participant	Ocular manifestation	Pulmonary TB	Past History Pulmonary TB	The Mantoux /tuberculin skin test	QuantiFERON-TB Gold	Fine needle aspirations of lymph node	Chest x ray
1	Scleritis	Present	Absent	P	P	P	P
2	Uveitis and complicated cataract	Present	Absent	P	P	N	P
3	Intermediate uveitis	Absent	Present	N	N	N	N
4	Multifocal choroiditis	Absent	Present	N	P	N	N
5	Choroidal tubercle and posterior uveitis	Present	Present	P	P	P	P
6	Retinal vasculitis	Absent	Present	N	N	N	N
7	Retinal vasculitis	Absent	Absent	N	N	N	N
8	Retinal vasculitis	Absent	Absent	N	N	N	N
9	Retinal detachment secondary to retinal vasculitis	Present	Absent	P	P	N	P

5. Dramatic response with topical steroid eye drops without systemic steroids

3.1. Exclusion criteria

Patients with anterior or posterior uveitis due to connective tissue disorders or those showing a dramatic response to topical/systemic steroids without ATT.¹³

The consent is taken from all patients participating in the study.

The institutional ethical committee clearance is taken prior to study initiation

4. Results

Table 1 depicts Sociodemographic profile of study participant. In our study Males constituting most common group about 10 (91%) of 11 study participants presenting with ocular manifestation. In our study 6 participants are in the age group of 41 to 65 years constituting about 55% and 5 study participants in age group 21-40yrs forming 45%. **Table 2** depicts clinical profile of our study with bilateral eyes involved in 9 of our study participants constituting about 81%,

Gender	Number	Percentage	
Male	10	90.9	
Female	1	9.09	
		Age (Yr)	
		Less than 20yrs	Above 65yrs
0	5	6	0

Table 2: Clinical profile of our present study

Laterality	Number	Percentage
Unilateral	2	18.8
Bilateral	9	81.8

Table 3 Continued...							
10	Retinal detachment secondary to retinal vasculitis	Absent	Absent	N	N	N	N
11	Anterior uveitis conglomerate tubercle	Present	Absent	P	N	N	P

Where N represents negative and P represents position

Table 4:

Clinical manifestation	Number	Percentage
Scleritis	2	10
uveitis	2	10
Choroiditis	4	20
Retinal vasculitis	12	60
Clinical manifestation with pulmonary TB	7	63.63
Clinical manifestation without Pulmonary TB	5	45.45

5. Discussion

Our study is prospective observational study with 11 patients constituting 10 (91%) are males and 9% of female presenting with ocular tuberculosis compared to Adnan et al¹⁴ where 88% in females Murphy et al in 54% female presented with ocular tuberculosis.⁷ our study there is predominance of male compare to other studies with female predominance in ocular tuberculosis. There is no gender preference in the ocular tuberculosis although there is female predominance in pulmonary TB and Genital tuberculosis.

Our study (9) 81% of our study participants presented with bilateral ocular tuberculosis compared to Adnan et al¹⁴ bilateral ocular tuberculosis in 67%, 56% in Lopes et al 22% Grodrey et al had bilateral.¹⁵

In our study 5 of the study participants out of 11 presented with retinal vasculitis constituting about 45% constituting most common ocular tuberculosis followed by scleritis, intermediate uveitis, multifocal choroiditis, choroidal tubercle and posterior uveitis each constituting in 1, uveitis and complicated cataract presented in 2 study participants as compared to Adnan et al intermediate uveitis 3 multifocal uveitis in 2 one each of subretinal abscess, panuveitis, choroiditis, panophthalmitis, anterior uveitis.¹⁴ Murphy et al. 28 patients 23 uveitis is most common 10 anterior uveitis 6 posterior uveitis 7 panuveitis maculopathy optic neuritis episcleritis orbital fibrovascular TB retinal periphlebitis one each India being endemic for tuberculosis in our study the commonest manifestation retinal vasculitis and uveitis suggest that ocular tuberculosis infection occurred due to hypersensitivity in the absence of viable bacteria.⁷

In our study every part of eye is affected by TB with choroid infection being more commonest in form of panuveitis, choroiditis retinal vasculitis the choroidal infections and inflammations are common due to its rich blood supply and exposed to hypersensitive reaction.

6. Limitation of the Study

The ocular tuberculosis manifests in all tissues of eye. The limitation of our study is not all manifestation of ocular tuberculosis is not studied. Lack of reliable biomarkers for ocular TB making diagnosis challenging. Current diagnostic methods such as PCR are not always sensitive and specific to detecting TB. There is a need for better screening test especially in TB endemic areas like India.

7. Conclusion

For ophthalmologists it is imperative to know different morphological presentations of ocular tuberculosis. The Ocular Tuberculosis is diagnosed based on the high index of suspicion, typical clinical manifestations supported by modern molecular microbiological assays and a therapeutic response to Anti tubercular treatment.

8. Source of Funding

None.

9. Conflict of Interest

None.

References

- Grodsky JD, Lee J, Piri N. Presumed ocular tuberculosis: a retrospective case review. *J Ophthalmol Res.* 2022;5:108–16.
- Kumar A, Chawl R, Sharma N. Ocular tuberculosis. In: Essentials in Ophthalmology. Cham, Switzerland: Springer International Publishing AG; 2017.
- Nussenblatt RB. The natural history of uveitis. *Int Ophthalmol.* 1990;14(5-6):303–8.
- Testi I, Agrawal R, Mahajan S, Agarwal A, Gunasekaran DV, Raje D, et al. Tubercular uveitis: nuggets from collaborative ocular tuberculosis study (COTS)-1. *Ocul Immunol Inflamm.* 2020;28(sup1):8–16.
- Agrawal R, Agarwal A, Jabs DA, Kee A, Testi I, Mahajan S, et al. Standardization of nomenclature for ocular tuberculosis - results of Collaborative Ocular Tuberculosis Study (COTS) Workshop. *Ocul Immunol Inflamm.* 2020;28(sup1):74–84.
- Gunasekaran DV, Agrawal R, Agarwal A, Carreño E, Raje D, Aggarwal K, et al. The Collaborative Ocular Tuberculosis Study (COTS)-1: a multinational review of 251 patients with tubercular retinal vasculitis. *Retina.* 2019;39(8):1623–30.
- Murphy J, Etti M, Duret A, Papineni P. Ocular tuberculosis: a case series from a London hospital. *Int J Infect Dis.* 2021;101(S1):452–63.
- Agarwal A, Agrawal R, Gunasekaran DV, Raje D, Gupta B, Aggarwal K, et al. The Collaborative Ocular Tuberculosis Study (COTS)-1 Report 3: polymerase chain reaction in the diagnosis and management of tubercular uveitis: global trends. *Ocul Immunol Inflamm.* 2019;27(3):465–73.

9. Tsui J, Poon SHL, Fung NSK. Ocular manifestations and diagnosis of tuberculosis involving the uvea: a case series. *Trop Dis Travel Med Vaccines*. 2023;9(1):20.
10. Sudheer B, Lalitha P, Kumar AL, Rathinam S. Polymerase chain reaction and its correlation with clinical features and treatment response in tubercular uveitis. *Ocul Immunol Inflamm*. 2018;26(6):845–52.
11. Lee C, Agrawal R, Pavesio C. Ocular tuberculosis--a clinical conundrum. *Ocul Immunol Inflamm*. 2016;24(2):237–42.
12. Agrawal R, Gunasekaran DV, Raje D, Agarwal A, Nguyen QD, Kon OM, et al. Global variations and challenges with tubercular uveitis in the Collaborative Ocular Tuberculosis Study. *Invest Ophthalmol Vis Sci*. 2018;59(10):4162–71.
13. Agarwal A, Aggarwal K, Gupta V. Infectious uveitis: an Asian perspective. *Eye (Lond)*. 2019;33(1):50–65.
14. Abd ZA. Tuberculosis of the eye, case series study. *J Med Life*. 2022;15(8):1058–62.
15. Teixeira-Lopes F, Alfaro S, Dinis A, Gomes MC, Tavares A. Ocular tuberculosis - a closer look to an increasing reality. *Pulmonology*. 2018;24(5):289–93.

Cite this article: Rathnaiah R. Ocular tuberculosis manifestation patients attending a tertiary care center. *Indian J Clin Exp Ophthalmol*. 2025;11(3):545–550.