

Content available at: <https://www.ipinnovative.com/open-access-journals>

Indian Journal of Clinical and Experimental Ophthalmology

Journal homepage: www.ijceo.org

Original Research Article

Fundus fluorescein angiography (FFA) most common complication compare with diet or without diet

Sushil Kumar Sah^{1*}, Rajya I Gurung¹, Shrbhan Sah², Tinku Mukherjee¹¹Dept. of Ophthalmology, Biratnagar Eye Hospital, Biratnagar, Nepal²L V Prasad Eye Institute, Hyderabad, Telangana, India

ARTICLE INFO

Article history:

Received 11-09-2023

Accepted 23-11-2023

Available online 30-03-2024

Keywords:

Adverse reactions

Diet or without diet

Systemic Illness

ABSTRACT

Purpose: Fundus fluorescein angiography (FFA) is usually done when the patient is on an empty stomach. In case, if the patient is not, their FFA is rescheduled for the next day to avoid the risk of complications. The purpose of this study was to compare the complications in patients who had undergone an FFA procedure on an empty stomach to those who had breakfast immediately before the procedure.

Materials and Methods: In this study, 210 participants underwent FFA, of which 104 were fasting, and 106 had breakfast just before their procedure. In these two populations, we compare the immediate and post-procedure complications.

Result: Patients who had FFA on an empty stomach were more likely to experience nausea and vomiting (11.32% vs 7.69%), skin allergies (1.89% vs 1.92%), and unconsciousness (0.94% vs 2.88%). In either the fasting or control groups, no complications were statistically significant ($P > 0.05$).

Conclusion: FFA is generally a safe procedure, however, previous studies have observed increased adverse events with people on empty stomachs. In individuals with various systemic disorders and diets, our study found no increase in adverse effects. Consequently, FFA shouldn't be postponed in these individuals who are not on a diet or who have systemic co-morbidities.

This is an Open Access (OA) journal, and articles are distributed under the terms of the [Creative Commons Attribution-NonCommercial-ShareAlike 4.0 License](https://creativecommons.org/licenses/by-nc-sa/4.0/), which allows others to remix, tweak, and build upon the work non-commercially, as long as appropriate credit is given and the new creations are licensed under the identical terms.

For reprints contact: reprint@ipinnovative.com

1. Introduction

Fundus fluorescein angiography (FFA) is an imaging technology commonly used in ophthalmology that provides more detailed information about the condition of the fundus of the eye.¹ It not only allows the diagnosis of vascular abnormalities but also shows the dynamic effects of delayed capillary filling when blood vessels leak due to inflammation or increased intracranial pressure.² The method uses sodium fluorescein (C₂₀H₁₀O₅Na₂), an organic dye with a molecular weight of 376 Daltons.³ Most commonly advised for the diagnosis of retinal diseases such as diabetic retinopathy, hypertensive retinopathy, age-related macular degeneration, central serous retinopathy,

and vascular occlusion.⁴ It is considered a safe procedure but the fact that studies have shown numerous side effects, which are divided into three categories: mild vomiting, irritability, convulsions, restlessness, involuntary injection into blood vessels), and moderated (fainting, thrombosis, fever, local changes) in tissue necrosis, muscle paralysis and skin allergy) and severe (bronchospasm, laryngeal edema,^{5–7} Previous studies have shown that mild side effects occur (from 14 to 0.73)%, i.e. the most common complication is vomiting. Severe and moderate side effects are lower (1%).⁸ to prevent complications Patients may be advised to empty their stomachs for four hours prior to the FFA procedures in order to prevent nausea and vomiting. They may also be given oral dosages of 25–50 mg of promethazine hydrochloride (Phenergan)

* Corresponding author.

E-mail address: sushilsahoptom24@gmail.com (S. K. Sah).

for about an hour, as well as sodium fluorescence injections. For moderately recurrent allergic reactions during FFA, it has been demonstrated that promethazine reduces itching and allergy symptoms. Pressor agents, aminophylline, epinephrine, and systemic steroids ought to be accessible for the treatment of bronchospasm and other allergic or anaphylactic reactions.⁹ study shows that Age and controlled systematic history demonstrate no increased risk for FFA procedure in comparison to the control group.¹⁰ Another important complication of angiography is fluorescein leakage during injection, which can be very painful, such as Skin peeling, tissue necrosis, subcutaneous granulomas, and toxic neuritis.^{11,12} To avoid such problems, it is recommended to constantly monitor the injection site throughout the procedure and check whether the patient experiences any discomfort. This study aims to determine the adverse effects of fundus fluorescein angiography in fasting patients and in patients who were not fasting before the procedure.

2. Materials and Methods

The Ethics Committee of Biratnagar Eye Hospital Institutional Review Committee approved this Cross-sectional comparative study. This study adhered to the declaration of Helsinki.

A Cross-sectional comparative study was done on patients who had undergone FFA at Biratnagar Eye Hospital. First, the patient visited the diagnostic department of the retina on the date of his or her appointment. Informed consent was explained to the patient and written consent was taken before the procedure when the ophthalmologist advised for the FFA. A nurse and an optometrist used an established questionnaire to collect a medical history when the patient arrived. Age, sex, systemic history, allergies to drugs, and the number of FFA investigations related details. Additionally, the patient's blood pressure and pulse were checked 20 minutes before and after the procedure. Following that, topical tropic-p (tropicamide and phenylephrine hydrochloride) was used to dilate the patient's pupils. After peripheral upper limb vein cannulation for intravenous access, 20% fluorescein dye with 3ml was administered as a quick (4–6 second) bolus. After the procedure was completed, the patient waited in the waiting area for an additional 1 to 2 hours. All asymptomatic patients who had breakfast prior to the FFA procedure were compared to those who had not.

Angiography's fundus fluorescence physical characteristics

A yellow-red, inorganic salt dye known as sodium fluorescein is commonly used as a cosmetic and medicinal color, as a labelling agent in protein, and to examine the flow structures of subsurface fluids.¹³ Its molecular mass is 376.7 kDa. After inserting a cannula in the vein, the circulation, around up to 80% of the dye's affinity for

plasma proteins, especially albumin, and the remaining 20% does not. Within 24–36 hours following injection, the liver and kidneys metabolize the dye, which is then excreted in the urine. Fluorescein angiography makes use of sodium fluorescein's unique fluorescent feature, which is the capacity for some molecules to produce longer-wavelength light when activated by shorter-wavelength light. Release of energy source by electron in the form of electromagnetic waves after being stimulated, which results in the of visible light. Using a flash of light /barrier filter or laser up to 500 to 485 nm range, light source energy is sent to the patient's retina. After that, the source of light energy is either reflected back as blue light due to the barrier filter being used or absorbed by sodium fluorescein and released as green light. The fluorescent picture is then selectively recorded using a camera and a filter that emits green light (520 to 535 nm) onto film or a digital surface. These characteristics make it recognized as the ideal material for researching blood-retinal barriers.¹⁴

2.1. Statistical analysis

SPSS version 25.0 was used for data analysis.

The chi-square test and Fisher's exact text association were used to get the P-value. It was considered statistically significant if P values were <0.05.

3. Results

Obtained data on 210 patients, (Age range 20 - ≤71 years). There were 29.52% females and 70.48% males in the population in Table 1.

Table 1: Demographic characteristics

Demographic Characteristics		n (%)
Age Group	<= 20	7 (3.33)
	21 – 30	11 (5.24)
	31 – 40	27 (12.86)
	41 – 50	38 (18.1)
	51 – 60	50 (23.81)
	61 – 70	59 (28.1)
	>= 71	18 (8.57)
Sex	Female	62 (29.52)
	Male	148 (70.48)
Diabetic	No	134 (63.81)
	Yes	76 (36.19)
Allergy	No	209 (99.52)
	Yes	1 (0.48)
Asthma	No	209 (99.52)
	Yes	1 (0.48)
Cardiac Disease	No	206 (98.1)
	Yes	4 (1.9)
Hypertension	No	181 (86.19)
	Yes	29 (13.81)
Tuberculosis	No	207 (98.57)
	Yes	3 (1.43)

Table 2: Diet in take and without wise demographic characteristics

Demographic Characteristics		Treatment Group	
		Without Diet	Diet
		n (%)	n (%)
Age Group	<= 20	3 (2.83)	4 (3.85)
	21 – 30	6 (5.66)	5 (4.81)
	31 – 40	11 (10.38)	16 (15.38)
	41 – 50	19 (17.92)	19 (18.27)
	51 – 60	25 (23.58)	25 (24.04)
	61 – 70	32 (30.19)	27 (25.96)
	>= 71	10 (9.43)	8 (7.69)
Sex	Female	28 (26.42)	34 (32.69)
	Male	78 (73.58)	70 (67.31)
Diabetic	No	63 (59.43)	71 (68.27)
	Yes	43 (40.57)	33 (31.73)
Allergy	No	105 (99.06)	104 (100)
	Yes	1 (0.94)	0 (0)
Asthma	No	106 (100)	103 (99.04)
	Yes	0 (0)	1 (0.96)
Cardiac Disease	No	105 (99.06)	101 (97.12)
	Yes	1 (0.94)	3 (2.88)
Hypertension	No	90 (84.91)	91 (87.5)
	Yes	16 (15.09)	13 (12.5)
Tuberculosis	No	105 (99.06)	102 (98.08)
	Yes	1 (0.94)	2 (1.92)

Table 2, shows the age group and number of systemic illnesses (diabetic mellitus, allergy, Asthma, cardiac disease, hypertension, and Tuberculosis) of patients who had breakfast before and after the FFA procedures.

The total adverse reaction rate (AR) included nausea and vomiting (11.32%) without diet and with diet (7.69%), skin allergy (1.89%) without diet and with diet (1.92%), and unconsciousness (0.94%) without diet and with diet (2.88%). There were no fatalities or significant cardiovascular issues. Three people needed medical attention for respiratory issues (Table 3, Figure 1).

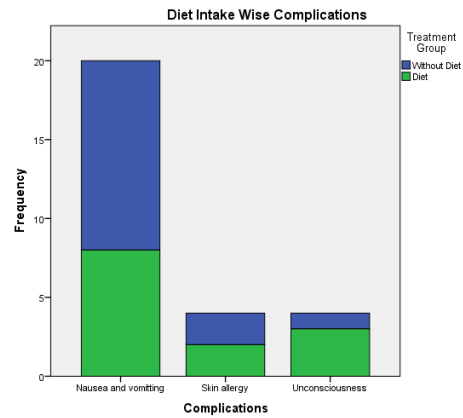
Hence, diet intake and adverse reactions have no association or correlation (P value > 0.05).

The frequency of adverse reactions (vomiting and nausea, skin allergies, and unconsciousness) is shown in Figure 1.

No statistically significant difference was found in the adverse effects in both the groups those who had breakfast vs those who didn't before the procedure (P>0.05).

4. Discussion

The invasive diagnostic technique is known as fundus fluorescein angiography (FFA). An analysis of the structure, physiology, and pathophysiology of the retinal and choroidal circulation is helpful.^{11,12} It can be used for the interpretation of various eye diseases. There are negative

**Figure 1:** Association of Diet intake and without intake adverse reaction

consequences attached to the function even if it is safe. The fundamental ideas, methods, and applications of FFA are described in this activity. Additionally, it analyses the role played by the interprofessional team in controlling adverse events and enhancing care for patients having this procedure performed, as well as the negative impacts connected with the diagnostic technique. The overall complication rate for the fasting group was 12.49% compared to 14.15% in the non-fasting group. It is to be noted that the difference in mild complications in these two populations while the moderate and severe complications in these two populations are not clinically significant. According to Oliver R. Marmoy, Robert H. Henderson, and Kuan Ooi, a patient who has had only a light breakfast without lunch before the oral FFA procedure is more effective and safer.¹⁵ According to earlier studies, minor adverse effects including vomiting sensation are the most common (2% to 14%), but moderate and severe complications are rare (1%). Although different authors have documented varying numbers of these negative side effects, the researcher did a retrospective and does not distinguish between patients who have previously undergone this test and those who are undergoing it for the first time¹⁶ Also, when we compare the complication rate in patient with systemic disease (diabetics, hypertension) the mild, moderate, and severe complication is 8.49%, 0.94%, and nil respectively in the population (n=73) who had breakfast immediately before the procedure while the population (n=59) who has undergone FFA in the empty stomach has the mild, moderate and severe complication of 3.92%, 0.98%, 0.98% respectively. Here the mild complication rate is higher in patients who had breakfast before the procedure, while the moderate to severe complication rate is clinically insignificant. Some other study done on Fluorescein angiography in geriatric and hypertensive individuals did not have any negative consequences, according to Fayyaz Musa and Wisam J. Muen.,¹⁰ Fluorescein is used topically in almost

Table 3: Adverse reaction of fundus fluorescence angiography in both groups

Adverse Reaction		Treatment Group		P value
		Without Diet n (%)	Diet n (%)	
Nausea and vomiting	No	94 (88.68)	96 (92.31)	0.255*
	Yes	12 (11.32)	8 (7.69)	
Skin allergy	No	104 (98.11)	102 (98.08)	0.682 [#]
	Yes	2 (1.89)	2 (1.92)	
Unconsciousness	No	105 (99.06)	101 (97.12)	0.304 [#]
	Yes	1 (0.94)	3 (2.88)	

all patients with ocular problems during regular eye examinations. However, reports of negative effects are rare. Fluorescein adverse reactions occur between 1% and 2% of the time when given orally and 9.72% of the time when given intravenously.¹⁷ Since the mild complication in these two populations has nausea and vomiting only and is temporary, it is safe to perform FFA in patients who had a light breakfast before the procedure. Also, a history of systemic disease under control with medications has comparable adverse effects in these two populations.

5. Conclusions

This study's conclusion is that FFA is a generally secure procedure that provides crucial diagnostic information that might eventually improve the patient's quality of life. FFA should not be postponed on the basis of whether the patient was empty stomach or not. Systemic illness as these factors, not adverse reactions in FFA procedures both groups had complication rate are same which is not clinically significant in this study.

6. Source of Funding

None.


7. Conflict of Interest


None.

References


- Ali SM, Kozak I. Fundus fluorescein angiography via percutaneous endoscopic gastrostomy: Description of technique. *Am J Ophthalmol Case Rep.* 2023;30:101832.
- Littlewood R, Mollan SP, Pepper IM, Hickman SJ. The Utility of Fundus Fluorescein Angiography in Neuro-Ophthalmology. *Neuroophthalmology.* 2019;43(4):217–34.
- Bennett TJ, Quillen DA. Fundamentals of Fluorescein Angiography. Available from: <http://eye-pix.com/>.
- Berkow JW, Flower RW, Orth DH, Kelley JS. Fluorescein and Indocyanine Green Angiography: techniques and interpretation. 2nd ed. San Francisco: The Foundation of the American Academy of Ophthalmology; 1997. p. 224.
- Tsang SH, Sharma T. Fluorescein Angiography. *Adv Exp Med Biol.* 2018;1085:7–10.
- Kwiterovich KA, Maguire MG, Murphy RP, Schachat AP, Bressler NM, Bressler SB, et al. Frequency of adverse systemic reactions after fluorescein angiography: results of a prospective study. *Ophthalmology.* 1991;98(7):1139–42.
- Yannuzzi LA, Rohrer KT, Tindell LJ, Sobel RS, Costanza MA, Shields W, et al. Fluorescein angiography complication survey. *Ophthalmology.* 1986;93:611–7.
- Hyderi MF, Khan TP, Munawar CMT. Incidence of Complications during Fluorescein Fundus Angiography (FFA) in Our Population. *PJMHS.* 2012;6(2):320–3.
- Johnson RN, Fu AD, McDonald HR, Jumper JM, Ai E, Cunningham ET, et al. Fluorescein Angiography: Basic Principles and Interpretation. *Retina.* 2012;doi:10.1016/B978-1-4557-0737-9.00001-1.
- Musa F, Muen WJ, Hancock R, Clark D. Adverse effects of fluorescein angiography in hypertensive and elderly patients. *Acta Ophthalmol Scand.* 2006;84(6):740–2.
- Schatz H. Sloughing of skin following fluorescein extravasation. *Ann Ophthalmol.* 1978;10(5):625.
- Lipson BK, Yannuzzi LA. Complications of fluorescein injections. *Int Ophthalmol Clin.* 1989;29:200–5.
- Ciardella AP, Prall FR, Borodoker N, Cunningham ET. Imaging techniques for posterior uveitis. *Curr Opin Ophthalmol.* 2004;15(6):519–30.
- Bennett TJ, Barry CJ. Ophthalmic imaging today: an ophthalmic photographer's viewpoint - a review. *Clin Exp Ophthalmol.* 2009;37(1):2–13.
- Marmoy OR, Henderson RH, Ooi K. Recommended protocol for performing oral fundus fluorescein angiography (FFA) in children. *Eye (Lond).* 2022;36(1):234–6.
- Yannuzzi LA, Rohrer KT, Tindell LJ, Sobel RS, Costanza MA, Shields W, et al. Fluorescein angiography complication survey. *Ophthalmology.* 1986;93:611–7.
- Lira RPC, De Andrade CL, Oliveira C. Adverse reactions of fluorescein angiography: a prospective study. *Arq Bras Oftalmol.* 2007;70(4):615–8.

Author biography

Sushil Kumar Sah, Master in Optometrist  <https://orcid.org/0009-0009-3491-7275>

Rajya I Gurung, Vitreo-retina Surgeon  <https://orcid.org/0000-0003-0816-9823>

Shrban Sah, Master in Optometrist  <https://orcid.org/0009-0009-4073-1151>

Tinku Mukherjee, Master in Optometrist  <https://orcid.org/0009-0003-0421-5930>

Cite this article: Sah SK, Gurung R, Sah S, Mukherjee T. Fundus fluorescein angiography (FFA) most common complication compare with diet or without diet. *Indian J Clin Exp Ophthalmol* 2024;10(1):76–79.