

Content available at: <https://www.ipinnovative.com/open-access-journals>

Indian Journal of Clinical and Experimental Ophthalmology

Journal homepage: www.ijceo.org

Case Report

A rare case of Turner's syndrome with thyroid associated orbitopathy

Avina Bishnoi¹, Subhash Kumar¹, Supreeth Chandrashekhar¹, Ritesh Kumar^{1*},
Rajendra Prakash Maurya²

¹Dept. of Endocrinology & Metabolism, Institute of Medical sciences, Banaras Hindu University, Varanasi, Uttar Pradesh, India

²Regional Institute of Ophthalmology, Institute of Medical Sciences, Banaras Hindu University, Varanasi, Uttar Pradesh, India



ARTICLE INFO

Article history:

Received 20-08-2024

Accepted 12-09-2024

Available online 30-09-2024

Keywords:

Turner's syndrome
Graves' orbitopathy
TAO

ABSTRACT

Turner syndrome (TS) is a chromosomal disorder that occurs in 1 per 2500 live-born females, due to complete or partial absence of a second normal X chromosome resulting in short stature and ovarian failure. The risk of autoimmune diseases in patients with TS is quite prominent, especially autoimmune thyroiditis. Nevertheless, Graves' disease (GD) has been rarely reported in Turner's syndrome with 45, XO karyotype. Here we report a case of adult phenotypic female who first time presented with Graves' orbitopathy and later was diagnosed to have Turner's syndrome.

This is an Open Access (OA) journal, and articles are distributed under the terms of the [Creative Commons Attribution-NonCommercial-ShareAlike 4.0 License](https://creativecommons.org/licenses/by-nc-sa/4.0/), which allows others to remix, tweak, and build upon the work non-commercially, as long as appropriate credit is given and the new creations are licensed under the identical terms.

For reprints contact: reprint@ipinnovative.com

1. Introduction

Turner syndrome, first described by Henri Turner, is the most common sex chromosomal abnormality found in females.¹ It results from complete or partial deletion of the X chromosome. Most common karyotype found in half of the TS is monosomy X (45, XO). Rest contains mosaic chromosome (45, X with mosaicism) and chromosome with structural abnormalities.² Increased incidence of Autoimmune disease is seen with chromosome with structural abnormalities as isochromosome q. Prevalence of Hashimoto's thyroiditis (HT) is approximately 25% and 2.5% of GD, which is in much lesser prevalence than HT.³ Thyroid associated orbitopathy (TAO) is a common manifestation of Graves disease. We thus report a case of a phenotypic female presenting with Graves' orbitopathy in her late 20s and was found to have Turner's syndrome with 45, XO karyotype.

2. Case Report

Twenty eight years old female presented in the endocrinology department with complaints of weight loss associated with loosening of clothes and hyper defecation from 1 year, along with bilateral eye symptoms of dryness, redness and associated pain, proptosis, and double vision for 6 months. These symptoms were associated with abnormal photophobia and excess watering. Further history revealed that patient didn't attained menarche and there was non-development of secondary sexual characters. Past illness or family history did not reveal any presence of thyroid-related diseases or any other autoimmune disorder. On physical examination, her blood pressure in supine position was 130/80 mm Hg with pulse rate of 130 beat per minute, no radio-radial or radio-femoral delay was present. Anthropometric examination revealed proportionate short stature with height 143 cm (<3rd centile, -2.7 SDS), weight 34.5 kg (<3rd centile, -2.4 SDS), and body mass index (BMI) of 16.8 kg/m². Multiple nevi, shield chest, pectus excavatum, carrying angle of 15°, brachydactyly and brachymetatarsia, WHO grade II goiter and fine tremors

* Corresponding author.

E-mail address: riteshgsvm@gmail.com (R. Kumar).

in outstretched hands was present. Sexual maturity rating according to Tanner stage was 1 for breast and pubic hair. Ophthalmological examination revealed retracted eyelid, and lagophthalmos. Exophthalmos measurement by Hertel ophthalmometer on the right and left sides were 20 mm and 16mm, visual acuity with Snellen's chart was 6/18 in both eyes. Intraocular pressure was normal. Clinical activity score (CAS) was 4 with redness and swelling of the eyelid, caruncle swelling and pain while movement (Figure 1 A). Systemic examination was otherwise normal.

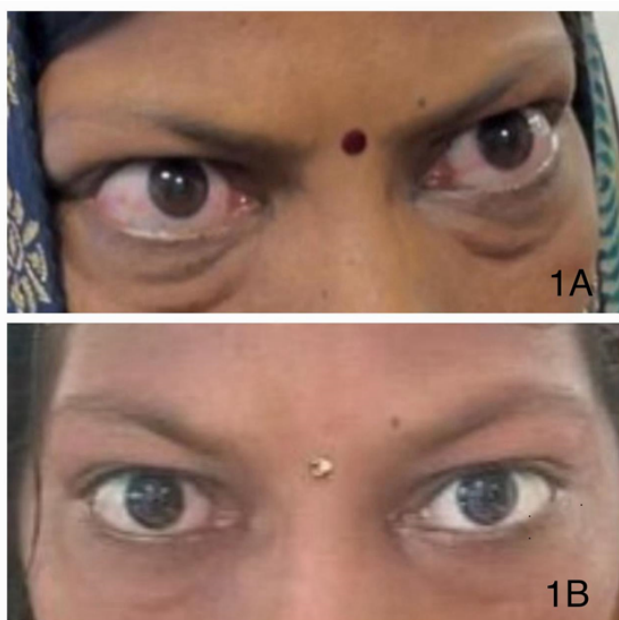

Figure 1: A) Baseline clinical activity score (CAS, 4/10); B): Clinical activity score (CAS, 0/10) after 3 month of Methylprednisolone therapy

Biochemical investigations (Table 1) revealed hyperthyroidism with T3: 671 (87-178 ng/dl), T4: 26 (4.82-15.65 mcg/dl), Thyroid stimulating hormone (TSH): 0.002 mIU/ml; and Follicular stimulating hormone (FSH) of 45 mIU/ml, suggestive of hypergonadotropic hypogonadism. Patient's liver function tests were deranged, which could be the result of thyrotoxicosis as abdominal ultrasonography was normal. Ultrasonography revealed diffuse enlargement of thyroid gland with increased vascularity. Non-contrast Computed Tomography (NCCT) of the orbit showed mild axial proptosis of bilateral eyeballs with mild enlargement of extraocular muscles. Chromosomal analysis conveyed 45, XO karyotype, which was consistent with our diagnosis.

She was started on the injection methylprednisolone 500 mg intravenously weekly for 6 weeks and later on 250 mg weekly for 6 weeks for the treatment of Graves' orbitopathy along with the supportive measures as sunglasses for reduction of photophobia, artificial tears and lubricant ointments. After 12 week of methylprednisolone therapy,

clinical activity score was decreased from 4/10 to 0/10 (Figure 1 B) and still non active orbitopathy after 6 month of follow-up. To restore euthyroidism patient was given 40 mg of carbimazole and 80 mg of sustained release propranolol. After 3 months of carbimazole therapy, level of T3, T4, AST & ALT were decreased compared to baseline (Table 2).

Table 1: Baseline biochemical investigation of patient

	Result	Normal range
Haemoglobin (g/dl)	11.5	12-15
TLC (thou/mm ³)	8.17	4.0-10.0
Blood urea (mg/dl)	15.9	15-45
S. Creatinine (mg/dl)	0.34	0.5-1.4
SGOT/ SGPT(IU/L)	139/118	<40
ALP (IU/L)	1328	0-270
Total Bilirubin (mg/dl)	0.46	0.1-1.2
T3 (ng/dl) T4 (mcg/dl)	671 26	T3 (87-178) T4 (4.82-15.65)
TSH (mIU/ml)	0.002	TSH (0.38-5.33)
FSH (mIU/ml)	45	3-14

Table 2: Baseline clinical activity score, biochemical investigation and after follow-up

	CAS	T3/T4/TSH	LFT (SGOT/SGPT/ALP)
Baseline	4/10	671/26/0.002	139/118/1328
After 1 st month	1/10	102/1.92/8.96	48/64/800
After 3 rd month	0/10	117/4.70/6.02	40/60/540

3. Discussion

The risk of autoimmune disease has been better characterized in patients of TS such that two fold increased risk has been described than general female population.⁴ Autoimmune disease commonly observed in TS include Hashimoto's thyroiditis, increased risk of celiac disease, type 1 diabetes (T1DM), inflammatory bowel disease, juvenile rheumatoid arthritis, Sjogren's disease, sarcoidosis, alopecia areata, psoriasis, as well as rare diseases like polyarthritis nodosa, and immune thrombocytopenic purpura.⁵

Increased frequency of autoimmunity in TS patients is reported possibly due to haploinsufficiency of genes on the X chromosome which leads to lack of self-protein exposure in the thymus and escape of autoreactive T cells.⁶ Some studies reported an association between autoimmune thyroiditis and influence of karyotype, an increased incidence of Autoimmune disease in girls with the isochromosome q karyotype.⁷ HT is more frequent in TS patients with X isochromosome and have higher proportion of positive antithyroid antibodies. Women with TS have excessive production of pro-inflammatory

cytokines (IL-6), and lower anti-inflammatory cytokines (IL-10, TGF- β), involved in regulation of the immune response and altered immune tolerance.^{8,9} Autoimmune susceptibility in TS has also been described due to genes located on the X-chromosome which are known to be possibly involved in the immune regulation process such as alteration in the expression of the X-linked FOXP3 gene. FOXP3 encodes a transcription factor important in the development of regulatory T cells. Polymorphisms of FOXP3 expression has been shown to result in autoimmune thyroid diseases in TS girls.⁸ Autoimmune thyroiditis is the most prevalent autoimmune disease in TS with elevated titers of antithyroid antibodies (antithyroid peroxidase, antithyroglobulin) reported in as many as 50% of Turner patients.⁹ Thyroid autoimmune diseases encompasses Hashimoto's thyroiditis (HT), and Graves' disease. Most Hashimoto's thyroiditis cases present with subclinical hypothyroidism, but with a higher risk of progression from subclinical to overt hypothyroidism with age. As high as 25–30% prevalence of overt hypothyroidism has been reported in adult women with TS.^{10,11} Though HT prevalence is higher in TS patients, but low prevalence for GD is reported, prevalence rate of GD has been reported to be 1.7–3% in TS girls.¹² Mohamed et al. conducted a meta-analysis on patients of TS, which included total of 18 studies and demonstrated that 12.7% of them had clinical hypothyroidism and 2.6% had hyperthyroidism.¹³ GD presents at a slightly later age, its presentation is often preceded by HT antecedents but has a similar clinical course and response to treatment in TS as in females without TS.¹⁴

4. Conclusions

Higher prevalence of autoimmune diseases especially autoimmune thyroiditis has been reported in TS. Graves' disease though rare, yet has been documented in patients with Turner's syndrome. GD has a similar clinical course and response to treatment in TS as in females without TS.

5. Source of Funding

None.

6. Conflict of Interest


None.

References


1. Turner HH. A syndrome of infantilism, congenital webbed neck, and cubitus valgus. *Endocrinology*. 1938;23(5):566–74.
2. Wolff DJ, Dyke DLV, Powell CM. Working Group of the ACMG Laboratory Quality Assurance Committee. Laboratory guideline for

- Turner syndrome. *Genet Med*. 2010;12(1):52–5.
3. El-Mansoury M, Bryman I, Berntorp K, Hanson C, Wilhelmsen L, Landin-Wilhelmsen K. Hypothyroidism is common in turner syndrome: results of a five-year follow-up. *J Clin Endocrinol Metab*. 2005;90(4):2131–2136.
4. Lleo A, Moroni L, Caliarì L, Invernizzi P. Autoimmunity and Turner's syndrome. *Autoimmun Rev*. 2012;11(6-7):538–43.
5. Jørgensen KT, Rostgaard K, Bache I, Biggar RJ, Nielsen NM, Tommerup N, et al. Autoimmune diseases in women with Turner's syndrome. *Arthritis Rheum*. 2010;62(3):658–66.
6. Bianchi I, Lleo A, Gershwin ME, Invernizzi P. The X chromosome and immune associated genes. *J Autoimmun*. 2012;38(2-3):187–92.
7. Sparkes RS, Motulsky AG. The Turner syndrome with isochromosome X and Hashimoto's thyroiditis. *Ann Intern Med*. 1967;67(1):132–44.
8. Bakalov VK, Gutin L, Cheng CM, Zhou J, Sheth P, Shah K, et al. Autoimmune disorders in women with turner syndrome and women with karyotypically normal primary ovarian insufficiency. *J Autoimmun*. 2012;38(4):315–21.
9. Mortensen KH, Cleemann L, Hjerrild BE, Nexø E, Loch H, Jeppesen EM, et al. Increased prevalence of autoimmunity in Turner syndrome— influence of age. *Clin Exp Immunol*. 2009;156(2):205–10.
10. Chiovato L, Larizza D, Bendinelli G, Tonacchera M, Marinó M, Mammoli C, et al. Autoimmune hypothyroidism and hyperthyroidism in patients with Turner's syndrome. *Eur J Endocrinol*. 1996;134(5):568–75.
11. Davenport ML. Approach to the patient with Turner syndrome. *J Clin Endocrinol Metab*. 2010;95(4):1487–95.
12. Valenzise M, Aversa T, Corrias A, Mazzanti L, Cappa M, Ubertaini G, et al. Epidemiology, presentation and long-term evolution of Graves' disease in children, adolescents and young adults with Turner syndrome. *Horm Res Paediatr*. 2014;81(4):245–50.
13. Mohamed SOO, Elkhidir IHE, Abuzied AIH, Nouredin A, Ibrahim GAA, Mahmoud AAA. Prevalence of autoimmune thyroid diseases among the Turner Syndrome patients: meta-analysis of cross sectional studies. *BMC Res Notes*. 2018;11(1):842.
14. Aversa T, Lombardo F, Corrias A, Salerno M, Luca FD, Wasniewska M. In young patients with Turner or Down syndrome, Graves' disease presentation is often preceded by Hashimoto's thyroiditis. *Thyroid*. 2014;24(4):744–7.

Author biography

Avina Bishnoi, Senior Resident  <https://orcid.org/0000-0003-2133-976X>

Subhash Kumar, Senior Resident

Supreeth Chandrashekar, Senior Resident  <https://orcid.org/0000-0003-3085-6195>

Ritesh Kumar, Associate Professor

Rajendra Prakash Maurya, Professor

Cite this article: Bishnoi A, Kumar S, Chandrashekar S, Kumar R, Maurya RP. A rare case of Turner's syndrome with thyroid associated orbitopathy. *Indian J Clin Exp Ophthalmol* 2024;10(3):609-611.